

East African Medical Journal Vol. 84 No. 12 December 2007

CONSERVATIVE MANAGEMENT OF HORIZONTAL ROOT FRACTURE OF A MAXILLARY PERMANENT INCISOR: CASE REPORT

G. C. Ogonji, BDS, MSc.D, Division of Dental Health Services, Ministry of Health, Afya House, P.O. Box 3001-00100, Nairobi, Kenya

## CONSERVATIVE MANAGEMENT OF HORIZONTAL ROOT FRACTURE OF A MAXILLARY PERMANENT INCISOR: CASE REPORT

G. C. OGONJI

### SUMMARY

A case is presented of an 11-year-old boy who was diagnosed with a horizontal radicular fracture located in the middle third of a maxillary right central incisor that was immediately managed conservatively. Subsequent to the injury, the patient complained of inability to bite, a swollen upper lip and pain on palpation in the periapical region of the tooth. Clinically the tooth appeared extruded. Radiographic examination revealed a root fracture. The extruded tooth was repositioned and immobilised with a wire-composite splint, under a suitable prophylactic antibiotic and anti-inflammatory analgesic coverage for one week. Two years after trauma, the treated tooth was firm and healthy with good aesthetics and normal function.

### INTRODUCTION

In the majority of cases, root fractures occur in teeth with roots that are fully formed as evidenced by closed apices and are well embedded in matured alveolar bone. Such fractures may occur in the cervical third, middle third or apical third of the root (1). The least frequent, and also the most difficult to treat, are those fractures that occur in the cervical third (2,3). The fracture site appears radiolucent on radiographic examination and a diagnosis is made based upon the finding of a radiolucent line disrupting the normal continuity of the root. Early investigators as well as the current ones have stressed that the diagnostic quality of the radiograph in cases of a root fracture will depend on the angulation of the X-ray beam relative to the fracture and the plane of the fracture itself (4). They have further suggested that the radiographs be taken at several angulations in order to view the suspected root fracture from different perspectives. When a patient presents with a fractured root, the segments may be in close proximity or they may be separated. If they are apart, efforts should be made to bring the ends into close approximation by digital manipulation of the crown segment under local anaesthesia. A more favourable outcome is assured if segments are in close contact (5). Following reduction, the injured tooth must be immobilised for a period sufficient to allow for healing. This may be three weeks to three months or even years, depending on the severity of the fracture and the patient's oral

conditions as well as the systemic health (6). For best results, the patient should be placed on prophylactic antibiotic and anti-inflammatory analgesic coverage for one week. With the stabilisation of the fragments and absence of infection, the prognosis of middle third and apical third root fractures is very good. The prognosis of cervical third root fractures is poor because of the difficulty of stabilising the crown segment and because of the ease with which bacteria from the gingival crevice and saliva can infect the fracture area (2,7). Davidovich *et al.* (8) have reported that minimal coronal displacement, optimal reduction and immediate fixation all contribute to the preservation of the integrity of the periodontal ligament and vitality of the pulp, resulting in a favourable prognosis. The purpose of this work, therefore, was to describe a successful conservative treatment of a radicular fracture of an anterior tooth based on early and accurate diagnosis of the injury.

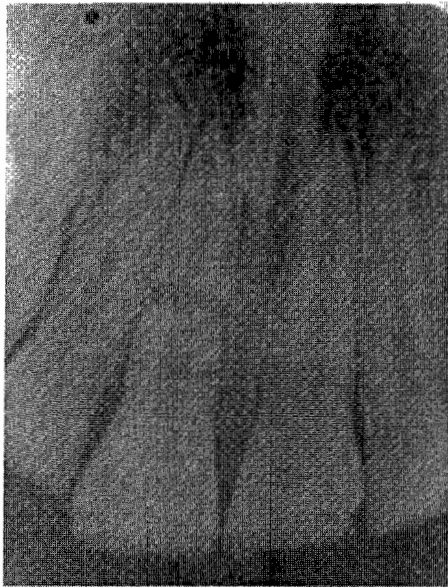### CASE REPORT

An 11-year-old boy was referred to a private paediatric dental practice for treatment of oro-facial injuries sustained following a fall at school. On clinical examination, injuries in the mouth included extrusion of a maxillary right central incisor, an upper labial laceration and a deep cut in the lower lip with a swelling while radiographic examination revealed a complete horizontal mid root fracture of the injured tooth with moderate displacement and widening of

the periodontal space (Figure 1), but eliciting a positive reaction to an electric pulp vitality test. A medical report from the referring local health facility indicated that the patient had received an initial injection of tetanus toxoid booster and anti-inflammatory drugs as well as prophylactic antibiotics in both injectable and oral forms.

**Figure 1**

*Horizontal root fracture of maxillary permanent right central incisor upon presentation of the patient for treatment*

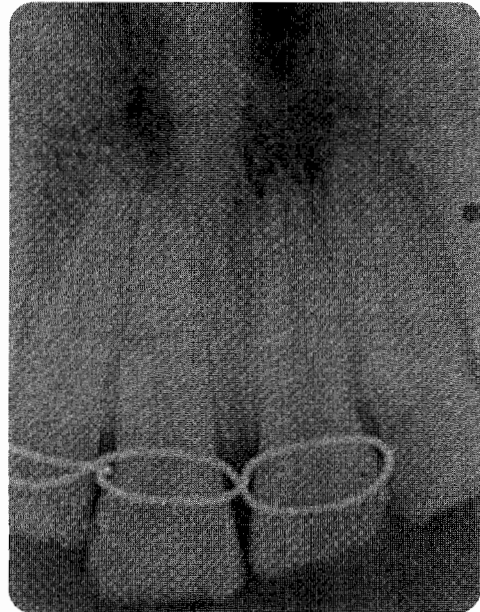


Under local anaesthesia and sterile conditions, thorough debridement of the lacerated lip and gingivae was carried out prior to their surgical closure with catgut and silk sutures. Immediately after, a gentle digital manipulation and approximation of the root fragments was performed, bringing the crown to a functional occlusion and aesthetic appearance.

A wire-composite splint, because of its flexibility and capability to maintain its position (9,10), was the splint of choice. A 0.3 mm stainless steel wire was looped around the labial and palatal surfaces of the crown of the injured tooth and extended to two other teeth on either side of the injury (Figure 2). The enamel surfaces were etched, and bonding resin and composite were then placed and polymerised in sequence separately with ultraviolet light (11). Occlusal contact with the opposing teeth was relieved to minimise further injury to the splinted tooth. The patient was educated on the importance of oral hygiene, with a strong emphasis on regular tooth brushing and oral rinsing with a chlorhexidine antibacterial mouthwash and how to clean the splint properly in order to avoid destruction of the periodontal apparatus.

**Figure 2**

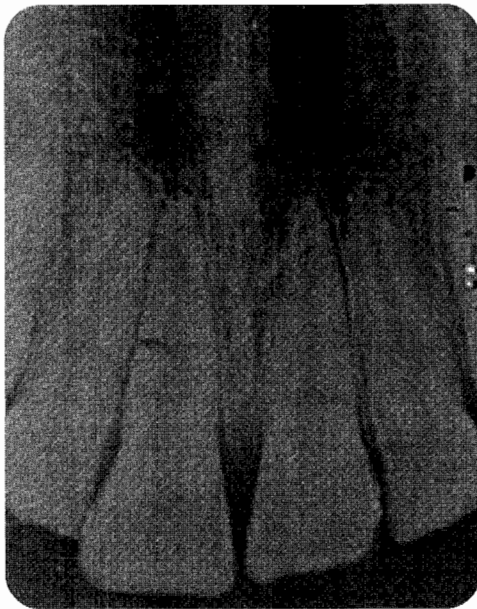*Successful approximation of the root fragments is evident ten days after reduction and fixation with a wire-composite splint*



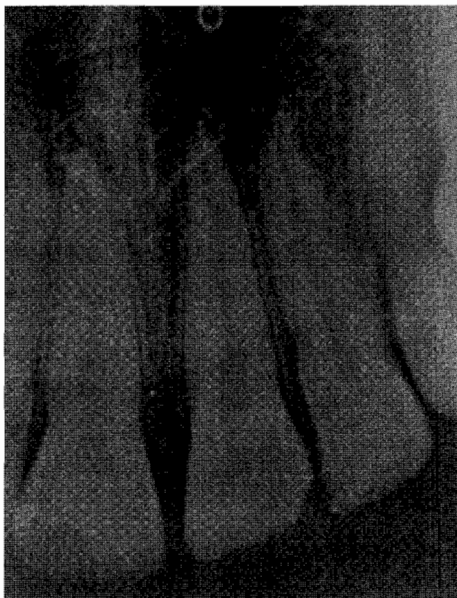At a follow-up visit ten days later, the patient reported total relief from pain related to the injuries. The soft tissue healing was remarkable as was the stability of the splinted tooth. At this stage silk sutures were removed and the healing wounds cleaned. Oral hygiene instructions were reinforced. Regular monthly recall visits were planned to assess the condition of the splinted tooth and the supporting tissues both clinically and radiographically. At a recall appointment two months after his initial presentation, the patient appeared to have healed completely with no discomfort arising from the orofacial injuries. This observation was confirmed by the normal tooth colour and position, with a positive response to electric pulp vitality test. Follow-up radiographs showed almost complete repair of the root fracture with hard tissue forming between the root segments (Figure 3). No pathological changes were evident in the periapical or fracture areas. The encouraging results from the review appointments indicated that the splint had successfully stabilised the repositioned tooth fragments. Subsequently, the splint was removed. At a 22-month follow-up examination, the tooth was clinically healthy and continued to satisfy aesthetic and functional demands (Figure 4). Further clinical review could not be carried out as the patient immigrated abroad soon after this visit.

**Figure 3**

*Healing of fracture line with hard tissue formation is evident after eight weeks of splinting*

**Figure 4**

*Healing is nearly complete 22 months after treatment commenced*



## DISCUSSION

Although the available literature considers the horizontal mid-root and apical fractures in mature permanent anterior teeth to be the most common and with favourable prognosis (12,13), some factors of the injury can lead to an underestimation of the

extent of inflicted damage that tends to impact unfavourably on treatment outcomes. Periodontal tissue injuries tend to be neglected and are mostly noticed when healing fails to occur (14). In addition, as these injuries cause less severe symptoms compared to the root fracture, they are likely to remain untreated. Therefore, a thorough clinical assessment as well as high quality diagnostic radiographs would further contribute considerably to the success of overall management of the sustained injury. Healing of root fractures usually takes place in four different ways: (a) interposition of calcified tissue, (b) interposition of connective tissue (c) interposition of bone tissue and (d) interposition of granulation tissue (5,15). However, histologic studies have shown that if granulation tissue is interspersed between the root segments healing does not occur. Instead, there is a widening of the fracture line (5,15). On clinical examination a fistula may be present and the teeth may be mobile and nonvital. Radiographically the bone associated with the fracture is radiolucent. These cases are considered failures which require follow-up endodontic treatment or extraction (13,15,16).

In the present case, the reason for a conservative approach in the management of the root fracture was that the two root fragments were moderately separated intraosseously with minimal damage to the periodontium. In the circumstances, the most viable treatment option was reduction and immobilisation of the fragments as this would increase the chances of the pulp remaining vital and healing of the fracture occurring with hard tissue (5,15). However, if pathologic changes occurred during the period of immobilisation, a decision would be made as to whether the tooth should be retained. Under such circumstances, retention would necessitate root canal therapy in the principal coronal fracture segment while the apical segment may be left alone, filled with an extension of the root filling from the principal segment, or may be surgically removed if infected (13-16).

In conclusion, this case illustrates the potential for repair of a horizontal root fracture following a successful reduction and fixation of the root fragments immediately after the injury. It further demonstrates that in a healthy patient, the prognosis may be directly related to the timeliness of treatment. Additionally, the treatment outcome highlights the need to encourage consultations and prompt referrals for improved quality of treatment of orofacial injuries.

## ACKNOWLEDGEMENT

My sincere gratitude to the patient and the parents for permission to publish the case report and timely appointments and understanding throughout the period of treatment.

## REFERENCES

1. Perkill, S.F., Hargreaves, J.A. and Weyman, J. Children's dentistry in general practice: Injuries to anterior teeth of children. *Brit. Dent. J.* 1970; **129**: 382-384.
2. Welbury, R., Kinirons, M.J., Day, P. *et al.* Outcomes for root-fractured permanent incisors: a retrospective study. *Pediatr. Dent.* 2002; **24**: 98-102.
3. Cvek, M., Mejare, I. and Andreasen, J.O. Healing and prognosis of teeth with intra-alveolar fractures involving the cervical part of the root. *Dent. Traumatol.* 2002; **18**: 57-65.
4. Schmidt, B.L. and Stern, M. Diagnosis and management of root fractures and periodontal ligament injury. *Calif. Dent. Assoc.* 1996; **24**: 51-55.
5. Cvek, M., Andreasen, J.O. and Borum, M.K. Healing of 208 intra-alveolar root fractures in patients aged 7-17 years. *Dent. Traumatol.* 2001; **17**: 53-62.
6. Yates, J. A. Root fractures in permanent teeth: A clinical review. *Int. Endod. J.* 1992; **25**: 150-157.
7. Ferari, P.H.P., Zaragoza, R.A., Ferreira, L.E. and Bombana, A.C. Horizontal root fractures: A case report. *Dent. Traumatol.* 2006; **22**: 215-217.
8. Davidovich, E., Heling, I. and Fuks, A.B. The fate of a mid-root fracture: a case report. *Dent. Traumatol.* 2005; **21**: 170-173.
9. von Arx, T. Splinting of traumatised teeth with focus on adhesive techniques. *J. Calif. Dent. Assoc.* 2005; **33**: 409-414.
10. Chang, H.H., Wang, Y.L., Chen, H.J., *et al.* Root fracture of immature permanent incisors - A case report. *Dent. Traumatol.* 2006; **22**: 218-220.
11. Maki, K., Nishioka, T., Seo, R. and Kimura, M. Management of a root fracture in an immature permanent tooth. *J. Clin. Pediatr. Dent.* 2005; **30**: 127-130.
12. Calistan, M.K. and Pehlivan, Y. Prognosis of root-fractured permanent incisors. *Endod. Dent. Traumatol.* 1996; **12**: 129-136.
13. Poi, W.R., Manfrin, T.M., Holland, R. and Sonoda C.K. Repair characteristics of horizontal root fracture: a case report. *Dent. Traumatol.* 2002; **18**: 98-102.
14. Roberts, J., Olsen, C. and Messer, H. Conservative management of an intruded immature maxillary permanent central incisor with healing complication of pulp bone. *Aust. Endod. J.* 2001; **27**: 29-32.
15. Celenk, S., Ayna, B.E., Ayna, E., *et al.* Multiple root fracture: a case report. *Gen. Dent.* 2006; **54**: 121-122.
16. Moule, A.J. and Moule, C.A. The Endodontic management of traumatised permanent anterior teeth: A review. *Aust. Dent. J.* 2007; **52** (1 Supp): S122-S137.