

East African Medical Journal Vol. 84 No. 11 November 2007

CAROTID OCCLUSION AND CEREBRAL INFARCTION FROM CAMEL BITE: CASE REPORT

B.B. Shehu, MBBS, FRCSI, FWACS, FACS, Senior Lecturer and Consultant Neurosurgeon, J.I. Nasiru, MBBS, FWACS, Lecturer and Consultant Neurosurgeon, M.R. Mahmud, MBBS, Senior Registrar in Neurosurgery, A. Laseini, MBBS, Senior Registrar in Neurosurgery, Regional Centre for Neurosurgery and S.A. Saidu, MBBS, FWACS, Lecturer and Consultant Radiologist, Department of Radiology, Usmanu Danfodio University Teaching Hospital, Sokoto, Sokoto State, Nigeria

Request for reprints to: Dr. B.B. Shehu, Regional Centre for Neurosurgery, Usmanu Danfodio University Teaching Hospital, Sokoto, Sokoto State, Nigeria

CAROTID OCCLUSION AND CEREBRAL INFARCTION FROM CAMEL BITE: CASE REPORT

B.B. SHEHU, J.I. NASIRU, M.R. MAHMUD, A. LASEINI and S.A. SAIDU

SUMMARY

A 30-year-old farmer was bitten by his camel on the left side of the neck. He suffered immediate loss of consciousness but recovered three days later with right-sided hemiplegia and complete aphasia. He bled minimally from the neck. CT scan of the brain and carotid Doppler ultrasonography confirmed left parietal lobe infarction and partial occlusion of the left carotid artery respectively. He was managed conservatively with physiotherapy and low dose aspirin. At six months of follow up, his speech remains slurred but comprehensible and is able to walk with a walking stick.

INTRODUCTION

Cerebrovascular disorders are a common cause of morbidity and mortality world wide. Cerebral ischaemia and infarction are the result of interruption of blood flow to the brain. In 80% of cases, the interruption occurs as a result of blockage in the arterial circulation to the brain due to an embolus, an obstructing arterial thrombus, or the stenotic effect of atherosclerosis (1). In the other 20%, it is caused by minor haemorrhage in the brain (1). We report an interesting case of cerebral infarction following carotid artery obstruction due to camel bite to the neck. We are aware of three similar cases reported following dog bites (2-4) and a case of camel bite that resulted to a fractured mandible, injury to the ear and intimal tear of the left common carotid artery (5).

CASE REPORT

A 30 year old farmer presented with four months history of right sided body weakness, pain and paraesthesia following a bite on the neck by his

camel. There was immediate loss of consciousness which was regained three days later. On recovery he was noticed to have right hemiparesis, aphasia, right ear hearing loss, and deviation of the mouth to the left. No convulsions. He only bled minimally from the neck wounds. No faecal or urinary incontinence. No visual impairment. The body weakness, hearing and speech have gradually being improving. Not a known hypertensive. No previous history of stroke. He walked into the clinic with a walking stick. Pulse rate 100/min, BP 130/90 mmHg, normal heart sounds. Two healed puncture wounds on the left side of the neck, anterior border of sternomastoid (Figure 1), and two other similar wounds at the apex of the right posterior triangle of the neck (Figure 2) were noted. He had a Glasgow Coma Score of 14 (confused), normal pupils, right facial nerve upper motor neuron palsy, and slurred speech. Muscle power was 3/5, with hypertonia, hyperreflexia, and sustained ankle clonus on the right upper and lower limbs. Left side was normal.

Chest X-ray, full blood count, erythrocyte sedimentation rate, serum electrolytes, blood sugar

and genotype were normal. Doppler ultrasound showed significant reduction in the diameter of the left carotid artery 2.5mm as compared to the right 6.5mm. Colour flow imaging showed no significant flow on the left carotid. Spectral display revealed spectral broadening suggestive of stenosis. Cranial CT scan (Figure 3) revealed watershed infarct involving the left parietal and temporal lobes extending from cortex to the lateral wall of the body of the lateral ventricle (left middle cerebral artery territory). Angiography or MR angiography could not be done. He is being managed conservatively on physiotherapy and psychotherapy.

Figure 1

Two healed puncture wounds on the left side of the neck, anterior border of sternomastoid (arrows)




Figure 2

Two healed wounds at the apex of the right posterior triangle of the neck (arrows)


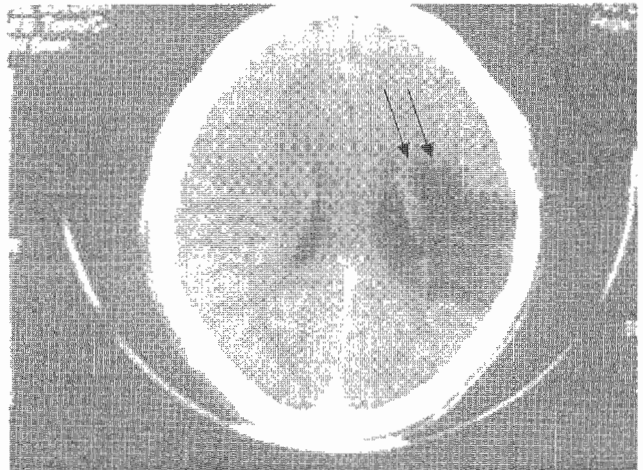


Figure 3

CT brain scan revealing watershed infarct involving the left parietal and temporal lobes (left middle cerebral artery territory) depicted by arrows



DISCUSSION

The metabolic demands of the brain define both its functional capabilities and its vulnerability to ischaemia. Cerebral ischaemia is the condition during which a region of brain suffers from insufficient metabolic energy to meet its local demands, resulting in an almost immediate loss of function for that region of the brain. Cerebral infarction with resultant cellular necrosis is the most extreme degree of cerebral ischaemia 80% of cerebrovascular diseases (CVD) result from blockage of cerebral arterial circulation by an embolus, thrombus, or stenotic effect of atherosclerosis. In the other 20% it is caused by minor cerebral haemorrhage (1). Major causes include hypertension, atherosclerosis, vascular malformation, arterial dissection. Rare causes include blood dyscrasias, polycythaemia, and infections. Other rarer causes include penetrating and non-penetrating trauma to the neck. Dog bite (2-4) and camel bite (5).

Middle cerebral artery (MCA) is the most involved in CVD, and is the largest of the branches of the internal carotid artery (ICA). Main-stem MCA occlusion produces massive infarction. A prolonged diminished level of consciousness is most often a finding given brain stem compression from oedematous MCA-supplied brain matter. Contralateral hemiplegia and hemisensory loss are characteristic. Lesions occurring in the dominant hemisphere result in profound aphasia, as demonstrated in our patient, while non-dominant

hemisphere lesions give rise to apraxia and hemineglect (6). Often, ICA occlusion occurs without overt clinical manifestations in the presence of adequate anastomosis. But where collateral supply is inadequate it may mimic an occlusive main-stem MCA lesion (1,6).

Laboratory tests are directed towards identifying treatable causes of cerebral ischaemia. Complete blood count, ESR, serum electrolytes, blood sugar, genotype and chest radiograph were done to exclude hypertension, haemoglobinopathy, hyperviscosity and infection as possible causes, and they were all normal. Doppler ultrasound of the carotid arteries showed reduced diameter of left common and internal carotid arteries. The left ICA was 2.5mm compared to the right 6.5mm. There was no significant flow in the left CCA and ICA. Also spectral display showed spectral broadening in same region suggesting stenosis.

ACKNOWLEDGEMENTS

To Dr. E.A. Ameh for severally going through the manuscript and giving tangible advice from its inception to its completion. We also thank the staff of the physiotherapy unit of Usmanu Danfodiyo University Teaching Hospital, Sokoto,

for the time and effort they put in to rehabilitate this patient. Finally we acknowledge the devotion of the dedicated nurses of the Regional Centre for Neurosurgery, Sokoto.

REFERENCES

1. Blasser T., Hoffmann K., Buerger T., *et al.* Risk of stroke, transient ischaemic attack, and vessels occlusion before endarterectomy in patients with severe carotid stenosis. *Stroke*. 2002; **33**: 629-638.
2. Meuli M. and Glaner H. Delayed cerebral infarction after dog bites: case report. *J. Trauma*. 1994; **37**: 848-849. PMID: 7966488
3. Hoyama Y., Fujioka S., Takiki S., *et al.* Occlusion of the cervical internal carotid artery due to dog bite wound: case report. *No Shinkei Geka*. 1994; **22**: 353-356. Japanese. PMID :8164801
4. Miller S.J., Copass M., Johansen K. and Winn H.R. Stroke following rottweiler attack. *Ann. Emerg. Med.* 1993; **22**: 262-264. PMID: 8427445.
5. Nawaz A., Matta H., Hamchou M., *et al.* Camel-related injuries in the pediatric age group. *J. Pediatr. Surg.* 2005; **40**: 1248-1251. [Abstract].
6. Keifer S.P., Selman W.R. and Ratcheson R.A. Clinical syndromes of cerebral ischaemia. In: Tindall G.T., Cooper P.R., Barrow D.L. Eds. *The practice of Neurosurgery*, William and Wilkins, 1997; Chapter 117.