

East African Medical Journal Vol. 84 No. 5 May 2007

SURGICAL COMPLICATIONS FROM LOCAL HERBAL PRACTITIONERS: REPORT OF FIVE CASES

A.A. Musa, FWACS, Consultant General Surgeon, S.A. Ogun, FWACP, Consultant Neurologist, A.O.J. Agboola, MBChB, Department of Morbid Anatomy, A.M.O. Shonubi, FWACS, Consultant Paediatric Surgeon, A.A.F. Banjo, FMCPATH, Consultant Histopathologist and J.A. Akindipe, MBBS, Department of Surgery, Olabisi Onabanjo University Teaching Hospital, Sagamu, Nigeria

Request for reprints to: Dr. A.A. Musa, Department of Surgery, Olabisi Onabanjo University Teaching Hospital, Sagamu, Nigeria

SURGICAL COMPLICATIONS FROM LOCAL HERBAL PRACTITIONERS: REPORT OF FIVE CASES

A.A. MUSA, S.A. OGUN, A.O.J. AGBOOLA, A.M.O. SHONUBI, A.A.F. BANJO and J.A. AKINDIPE

SUMMARY

Over a 12-month period, five patients (out of a total of 72) with serious complications resulting from use of herbs by traditional healers were seen at the surgical unit of Olabisi Onabanjo University Teaching Hospital, Sagamu, Nigeria. The age range was one and a half to five years with a mean age of $23.4 \pm SD$ years and a male to female ratio of 3:2. All the cases were misdiagnosed and mismanaged and ended up with various complications. Such as penile amputations, digital necrosis, upper and lower limb gangrene as well as a severe sepsis among others. Ignorance, cultural beliefs and attitudes, delusion, poverty and inaccessibility to orthodox medical practice were some of the factors responsible for the patronage of traditional healers.

INTRODUCTION

In recent time on a global outlook, herbal medicine and traditional healers have been given much recognition (1,2). There is increased use of herbal remedies by various groups of people and this is probably due to increased advocacy and publicity by the news media (1,2). There is attendant increase in the number of complications resulting from the herbal remedies and other forms of traditional healing methods (1,2).

This paper aims to report patients with various complications from the use of herbal preparations and to possibly highlight the shortcomings of their unscientific therapeutic methods (3).

This prospective study was carried out over a 12-month period between January – December 2004. Five patients (with very serious complications out of a total of 72) treated by traditional healers and subsequently came to hospital were reviewed. The age, sex, occupation, educational status of the patients were recorded and the reasons for

patronising the herbal and spiritual homes. The indication for treatment, as well as the nature/type of complications were recorded.

CASE REPORTS

Case 1: A six-year old school girl was knocked down by a motor-cycle on January 5, 2004, she sustained abrasions over the face, abdomen and lower limbs. The right arm was swollen and there was no loss of consciousness.

She was resuscitated and an X-ray of the right arm revealed a spiral fracture of the humerus (Figure 1). The relatives thereafter requested for discharge, refused further orthodox treatment and took her to a traditional bone setter within Sagamu, Ogun State, Nigeria.

She was brought back two weeks later with gangrenous right upper limb, (Figure 2). The herbalist put a tight cloth tourniquet round the right axilla (Figure 2, see the abrasions and pressure necrosis of the tourniquet round the right axilla).

Figure 1

X-ray of the right fore-arm with spiral fracture of the humerus

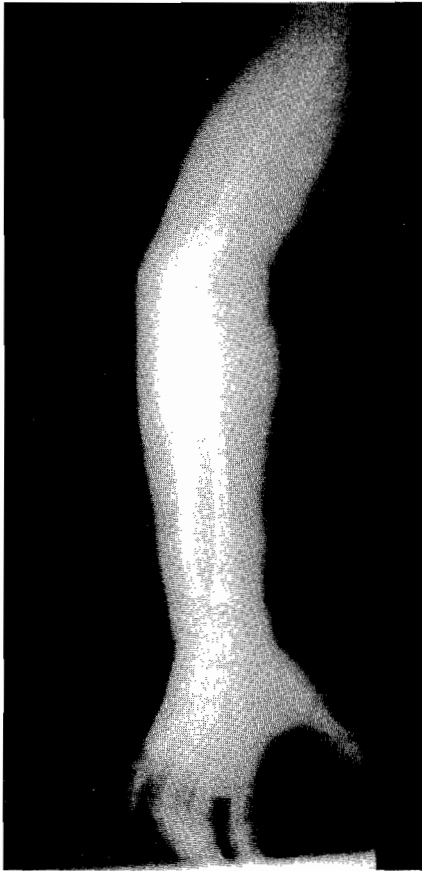

Figure 2

Swollen right upper limb with gangrenous skin and bulous eruptions

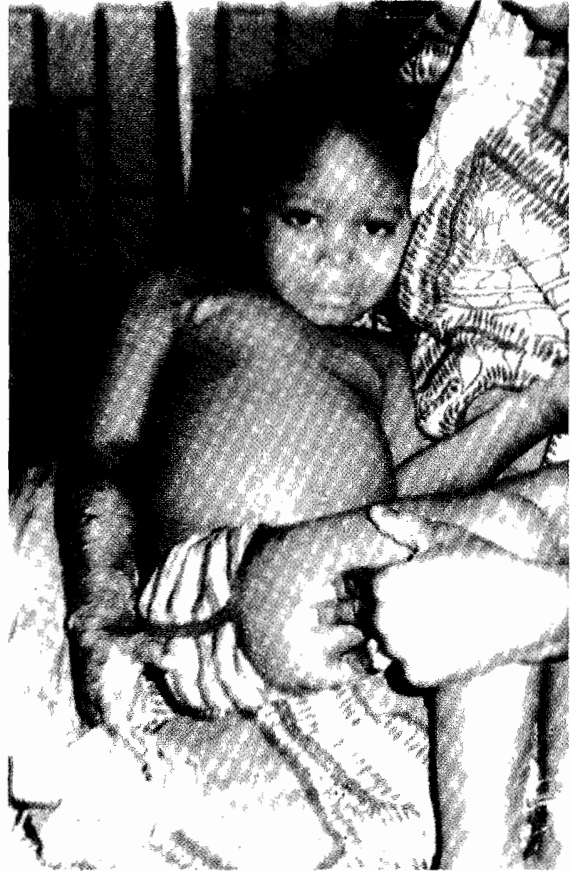
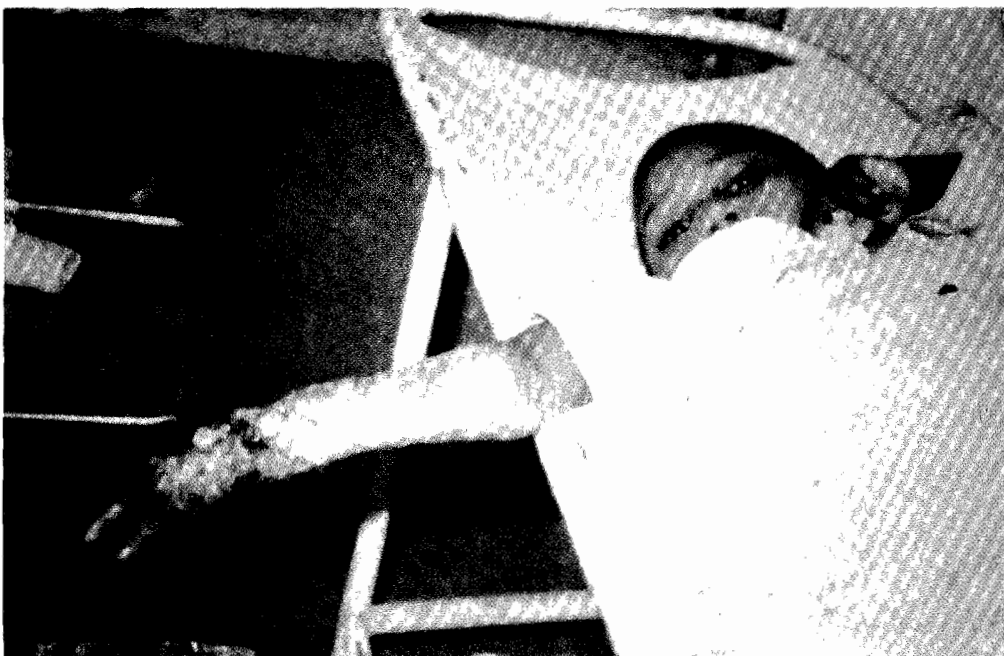

Figure 3

After debridement. Loss of skin, subcutaneous layer and loss of thumb, index and little fingers



This partially compromised blood supply and resulted in gangrene. After debridement, the patient lost the whole of the skin and subcutaneous layer of the right forearm with the thumb, index and little fingers (Figure 3). She had skin grafting subsequently and she was doing fine on follow up.

Case 2: An 18-year old apprentice was hit by a car on the right thigh. X-ray of the thigh revealed a distal third fracture of the right femur (Figure 4). The relatives absconded with the patient to a traditional bone setter. He applied a very tight cloth tourniquet just below the knee (see the necrotic skin at the tourniquet site).

This probably made the severance of the popliteal vessel by posterior angulation of the distal fracture segment possible with consequent

gangrene of the right leg. He lost the right foot in the process (Figures 5 and 6). He later reported back in the hospital and ended up with an above knee amputation. He was rehabilitated and prosthesis was given. He reported back to work.

Case 3: A 55-year old farmer suddenly developed a sharp upper abdominal pain and was taken to a traditional doctor. When his condition did not get better after five hours of observation, with increasing abdominal swelling, he was brought to the hospital for further management at the 7th hour post-ictal.

He was resuscitated and eventually had an exploratory laparotomy, which revealed a duodenal perforation (Figure 7). He had a closure of the perforation and postoperative recovery was uneventful.

Figure 4

Distal third fracture of the right femur

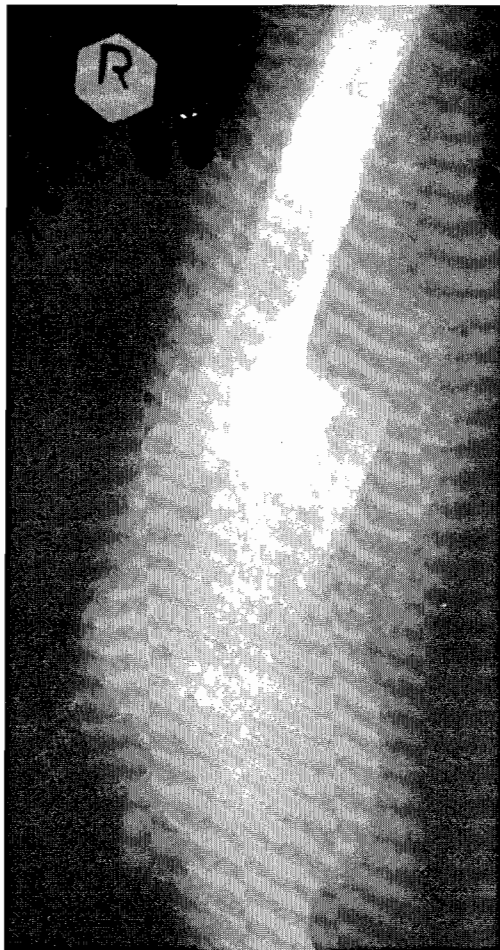


Figure 5

The tourniquet site and loss of right foot

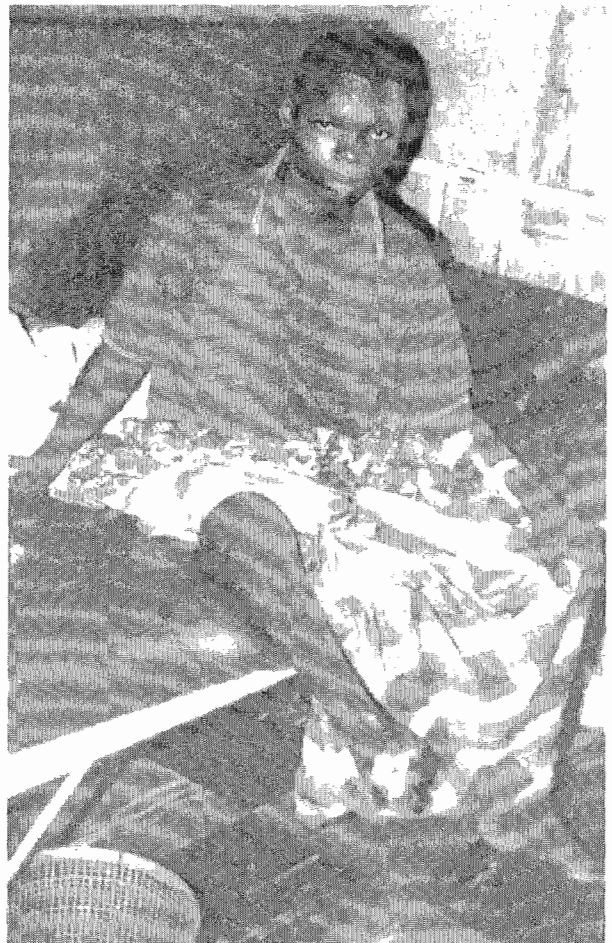

Figure 6

The absence of the right foot

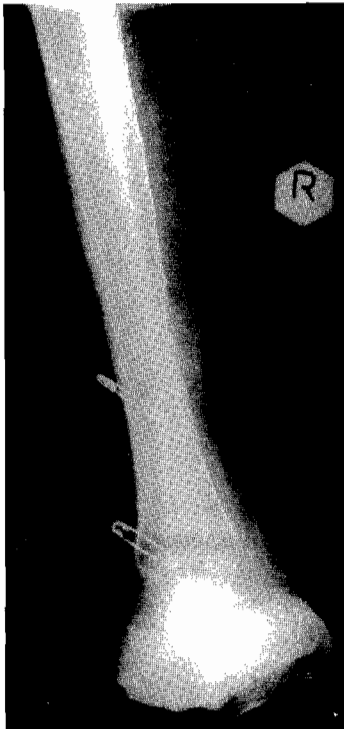


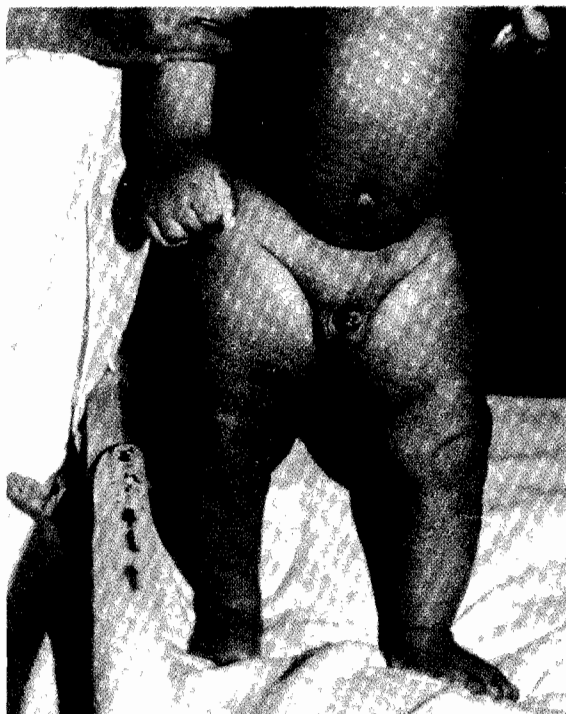
Figure 7

Duodenal perforation (intra-operative)

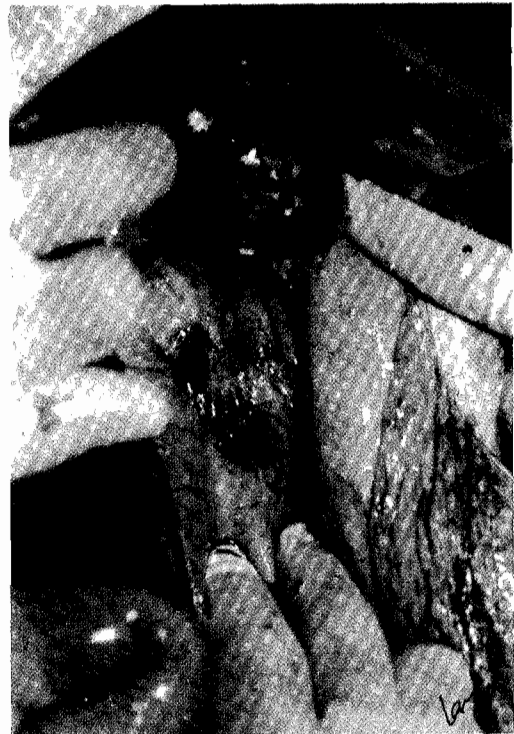

Figure 8

Penile-amputation in an 18-month-old child

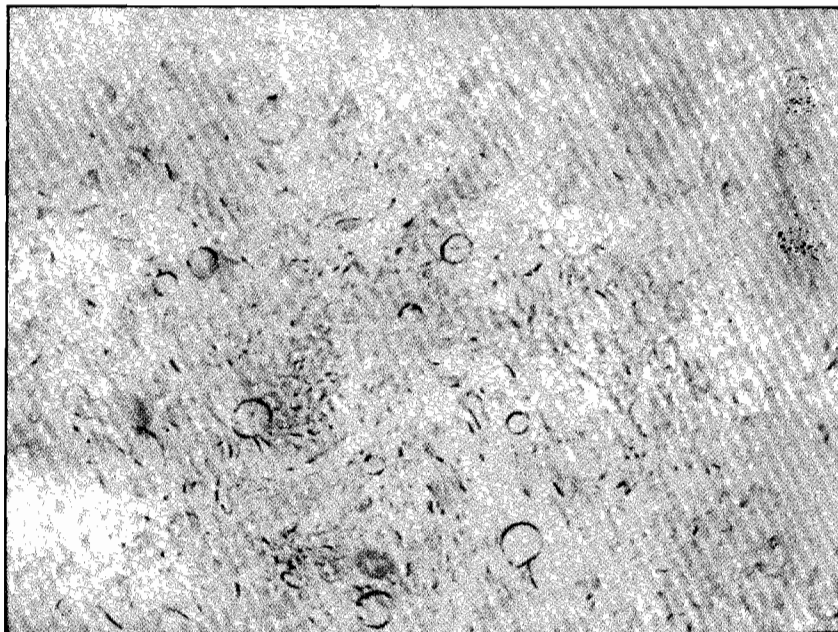
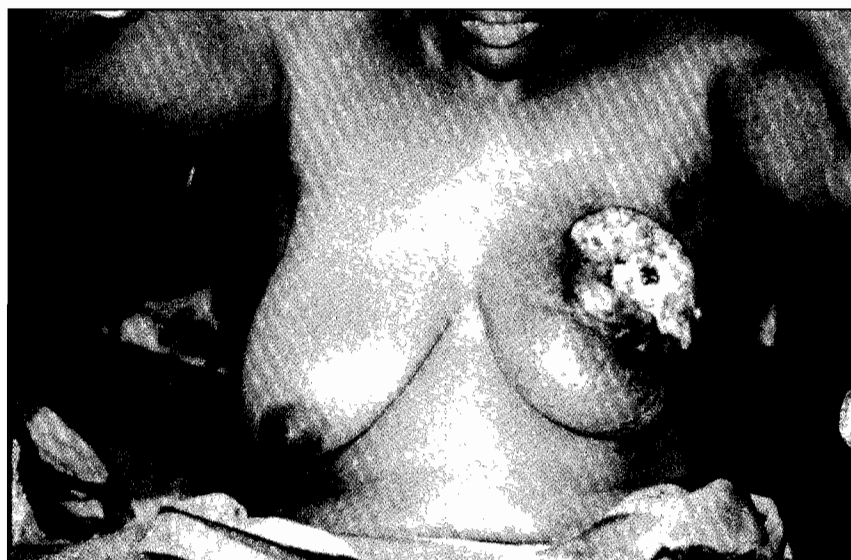

Case 4: An 18-month-old boy was taken to a traditional doctor for circumcision, four weeks before presentation at the surgical out patient clinic

in our hospital. Mother claimed she discovered the glans penis was partially missing seven days after the circumcision but the native doctor re-assured her. Further questioning revealed that she had earlier been to hospital but was not attended to. She therefore resorted to a native doctor.

Physical examination confirmed a healthy-looking boy with partial amputation of the glans penis (Figure 8). He had a refashioning done but was lost to follow up thereafter.

Case 5: A 43-year-old woman initially reported in the hospital with a lump in the right breast of three months duration. An incisional biopsy was done and the histology report was consistent with invasive ductal carcinoma (Figure 9). She was to undergo a modified radical mastectomy when she afterwards discharged herself against medical advice to a spiritual healer. She came back 12 weeks later with a fungating right breast tumour (Figure 10). She later had toilet mastectomy and split skin graft to achieve skin cover of the wound. She did well postoperative and later had cyclic chemotherapy. She is still on follow-up.

Figure 9*Features of invasive ductal carcinoma***Figure 10***Fungating left breast tumour*

DISCUSSION

Although West Africa is known to possess a very rich medical history, herbal medicine has been practiced for hundreds of years. The establishment of an effective herbal pharmacopoeia was probably the first medical research carried out in the sub-region (4).

There are lots of complications seen daily from the treatment offered by traditional healers. This is evidenced by the cases presented in this study. The insight into the modus operandi of these traditional healers and the methods of management offered for the cases reported here showed clearly the level of ignorance and lack of scientific bases for their treatment (5). The use of cloth as tourniquet

to immobilise fracture segments with or without realignment in the first two cases showed a total lack of understanding of principles of fracture management. The third case with an acute abdomen should have been sent back to hospital for proper management immediately as the herbal doctor had no clue as to the problem of the patient. The lack of knowledge of anatomy might be responsible for the circumcision mishap in the fourth case.

It is significant and noteworthy that all the cases came with various complications from the treatment they received from the herbalists. Comparable complications were documented in a study done in Dar es Salaam, Tanzania where the treatment of eye injuries by traditional healers resulted in such complications as Keratitis, endophthalmitis and panophthalmitis with poor visual outcome in the patients when compared with orthodox treatment (5). In Nigeria, Ogun *et al*, wrote that several claims of cure of diabetes and hypertension by traditional healers had resulted in increase in the prevalence of diabetic complications, chronic renal failure and stroke (6). Also in the United Kingdom, two cases of severe nephropathy caused by Chinese herbal tea, which was administered to treat eczema were recently reported (1,7). Mention must also be made of variations in the quality of herbal preparations. Recently, study of herbal creams in the United Kingdom showed that eight of the eleven preparations contained undeclared dexamethazone at a dangerous mean concentration of 456 mg/g (1,8).

To circumvent some of these problems, health providers should ensure improvement in basic health care, more service with better access, more dedication and respect from doctors and nurses with provision of more personnel and drugs. Furthermore doctors, pharmacists and health care professionals need to change their attitudes towards herbal medicine and traditional medical practice as more and more herbal medicines are being used by the people. This will be necessary in order to advise patients responsibly (1). Health providers need to know about herbal medications which should form an essential part of history taking especially on the drug-herb interaction (1,9,10). This will afford better protection of patients about complications of herbal medicine and traditional medical services (1). It is

also suggested that research into medicinal plants and alternative therapy should be through a proven scientific approach (3).

It can be concluded that traditional healing methods and use of herbal medication is worldwide and is given recognition especially among the indigent communities. Many of the methods they use are unscientific and forth with irreversible complications.

REFERENCES

1. Ernst E. Herbal Medicines: Where is the evidence? *Brit. Med. J.* 2000; **321**: 12.
2. Thanni L.O.A. Factors influencing patronage of traditional bone setters. *West Afr. Med. J.* 2000; **19**: 220-224.
3. Tsey K. Traditional medicine in contemporary Ghana; A public policy analysis. *Social Sci. Med.* 1997; **45**: 1065-1074.
4. Greenwood B. Traditional medicine to D.N.A. vaccines: The advance of medical research in West Africa. *Trop. Med. Int. Hlth.* 1998; **3**: 166-176.
5. Mselle J. Visual impact of using traditional medicine on the injured eye in Africa. *Acta. Trop.* 1998; **70**: 185-192.
6. Ogun S.A., Adelowo O.O., Faminloni O.B., Jaiyesimi A.E. and Fakoya E.A.O. Pattern and outcome of medical admissions and deaths in Ogun State Teaching Hospital, Sagamu – A three-year review. *West Afr. Med. J.* 2000; **19**: 309
7. Lord G.M., Tagore R., Cook T., Gower P. and Pusey C.D. Nephropathy caused by Chinese herbs in U.K. *Lancet.* 1999; **354**: 481-482.
8. Keane F.M., Munn S.E., Du Vivier A.W.P., Taylor N.F. and Hyiggins E.M. Analysis of Chinese herbal creams prescribed for dermatological conditions. *Brit. Med. J.* 1999; **318**: 563-564.
9. Janetzky K. and Morreale A.P. Probable interactions between warfarin and ginseng. *Amer. J. Hlth. Syst. Pharm.* 1997; **54**: 692-693.
10. Ernst E. Possible interactions between synthetic and herbal medicinal products. Part I: A systematic review of the indirect evidence. *Perfusion.* (in press).
11. Van Der Geest S. Is there a role for traditional medicine in basic health services in Africa? A Plea for a community perspective. *Trop. Med. Int. Hlth.* 1997; **2**: 903-911.