

*East African Medical Journal* Vol. 83 No. 12 December 2006

#### DETECTION AND IDENTIFICATION OF ECHOVIRUS 7 FROM A CHILD WITH GASTRO-ENTERITIS

J.W.O. Nyangao, MSc, Research Officer, P. Kingori, HNDD, Senior Medical Laboratory Technologist and F.A. Okoth, MBChB, MMed, Chief Research Officer/Director, Centre for Virus Research, Kenya Medical Research Institute, P.O. Box 54628-00200, Nairobi, Kenya

Request for reprints to: Mr. J.W.O. Nyangao, Centre for Virus Research, Kenya Medical Research Institute, P.O. Box 54628-00200, Nairobi, Kenya

## DETECTION AND IDENTIFICATION OF ECHOVIRUS 7 FROM A CHILD WITH GASTRO-ENTERITIS

J.W.O. NYANGAO, P. KINGORI and F.A. OKOTH

### ABSTRACT

**Background:** Gastro-enteritis continues to be a significant cause of mortality in infants and young children in developing countries. Some previous studies have associated echoviruses with gastro-enteritis.

**Objective:** To look for other viral agents causing gastro-enteritis in stool samples of infants and young children admitted with diarrhoea in an urban hospital in Kenya by electron microscopy.

**Design:** A cross sectional study.

**Setting:** Mbagathi District Hospital, Nairobi, Kenya.

**Subjects:** One hundred infants and young children admitted in the hospital due to gastro-enteritis and found to be negative for group A rotaviruses.

**Results:** We report a virus designated KE/CVR-99 which was recovered from the faeces of a one year old male child hospitalised for gastro-enteritis. Virus particles measuring 20-25 nm in diameter were detected by electron microscopy from the stool of the child hospitalised with gastro-enteritis. After injecting the viral particles intracerebrally in newborn suckling mice which were then observed daily for signs of illness, no sign of paralysis or any other form of illness was detected. Cytopathic effect was observed in rhabdomyosarcoma cells within six days of incubation whereas no cytopathic effect was observed in L-20 B cells. We identified the virus after typing against known anti-sera to a panel of enteroviruses. This virus was found to be Echovirus 7.

**Conclusion:** This is the first case report of echovirus 7 in association with gastro-enteritis and detection by electron microscopy in Kenya.

### INTRODUCTION

Diarrhoeal diseases continue to be a significant cause of morbidity in infants and young children in developed countries. It is also a significant cause of morbidity and mortality in the same age group in developing countries (1). Since Kapikian first identified a virus in the stool of a patient with diarrhoea in 1972, many viruses have been described that cause diarrhoea directly or indirectly. It is now appreciated that viruses are the most common cause of diarrhoeal illness worldwide. Rotavirus remains the leading cause of diarrhoeal disease overall, with

the newly designated calicivirus family causing the most outbreaks in the industrialised nations. As diagnostic techniques improve, however, the importance of other previously under-reported pathogens is becoming more apparent and the number of viruses associated with gastro-enteritis continues to increase (2).

Echoviruses are small, non-enveloped, positive-strand RNA viruses belonging to the genus Enteroviruses of the family Picornaviridae. They are human pathogens that infect mainly young children, causing a wide spectrum of clinical symptoms including aseptic meningitis, encephalitis, paralysis,

myocarditis, respiratory and gastro-intestinal disorders, muscular disability, exanthema and Reye's syndrome. However, the majority of infected individuals are asymptomatic. After transmission via the faecal-oral route, echoviruses are thought to establish themselves in primary sites of replication in the alimentary tract before spreading to other secondary target organs. However little is known about the actual course of echoviruses *in vivo*, except that viraemia may occur from 6 to 30 days prior to the onset of illness. There are 28 echovirus serotypes and most are associated with multiple clinical symptoms (3-5).

Echoviruses are found worldwide. Infection rates vary with the season, geography, and with both the age and socio-economic status of the population sampled. In the tropics, the infections occur throughout the year. In temperate climates in the northern hemisphere, infections are strikingly more prevalent during the summer and autumn months (6). Many cases of diarrhoea disease are reported but in some cases the aetiology is not known. It is important to try and identify other viral agents causing gastro-enteritis in children. We report on laboratory investigations performed and the identified causative agent.

## MATERIALS AND METHODS

In this study, one hundred diarrhoea stool samples from infants and young children that were negative for Group A rotaviruses by ELISA were subjected to electron microscopy to try and detect other viruses. These were samples from children admitted at Mbagathi District Hospital in Nairobi, Kenya with gastro-enteritis.

*Specimen collection:* Stool specimen was collected from every child attending or admitted in the study hospitals presenting with diarrhoea. The stool samples were collected in a clean stool container, then transferred to the Centre for Virus Research, Kenya Medical Research Institute. They were immediately kept in freezing storage at  $-20^{\circ}\text{C}$

*Processing of stool samples:* The stool samples were removed from cold storage and allowed to thaw. Stool suspension was made by adding a pea-sized (Approximately 0.6 gms.) amount of faecal material

from each sample to approximately 5 ml distilled water (12% suspension) and mixed well and allowed to settle. The supernatant was then used for ELISA.

*ELISA test for rotavirus infection:* Detection of human rotaviruses in stool was done by using a commercially available enzyme linked-immunosorbent assay (ELISA) kit (DAKOPATTS A/S, Copenhagen, Denmark) (7).

*Negative staining with phosphotungstic acid:* For negative staining examination, 400 grid mesh, coated with 20-40 nm plastic film (Collodion) and reinforced with 10-20 nm layer of carbon was used. The grids were made hydrophilic by glow discharge. Stool was diluted in a capped, 15 ml plastic tube 1:3 with hi-distilled water and homogenised using a vortex for 30 sec. Large particle matter, e.g. cell debris and bacteria were removed by low speed centrifugation (2,000 to 3,000 g for 10 min). Several drops of 20 microliter of the clear, transparent supernatant was placed onto the sheet of Parafilm and then hydrophilic grids were placed onto the droplet's surface for ten minutes adsorption time. The grids with adhering virus were transferred using forceps onto 50  $\mu\text{l}$  droplets of 2% phosphotungstic acid (PTA) pH 7.2. The grids were floated for thirty seconds on the stain. The grids were then removed from the stain and excess stain was drained away by touching the grids with a strip of filter paper ready for examination.

*Electron microscopy observation:* Samples were examined under a transmission electron microscope (TEM) (100 SX, JEOL) at an acceleration voltage of 100 kV. Photography was done using an electron microscope film (Fuji, Japan) developed in copital solution (Fuji) and enlarged on photographic paper (Fujibro WP, Fuji).

*Animal inoculation:* A 10% stool suspension was prepared in Eagle's Maintenance Medium with 2% serum albumin, 2% glutamine, and 1% antibiotics (penicillin, streptomycin and amphotericin B) and centrifuged at 3,000 rpm for 10 minutes. The clarified supernatant fluid was filtered with a 0.45- $\mu\text{m}$  syringe filter and injected intracerebrally into a litter of newborn suckling mice (24-48 hours after birth). The mice were observed daily for signs of illness.

*Cell culture and viral propagation:* Viral isolation attempts on both rhabdomyosarcoma and L-20 B cell cultures were made by injecting 100 µl of sample on to confluent monolayer of rhabdomyosarcoma and L-20B cells in 25 cm<sup>2</sup> culture flasks. These were incubated at 36°C and observed daily for evidence of cytopathic effect (CPE). When CPE was evident, the isolates was then subjected to neutralisation test for identification of enteroviruses.

*Neutralisation test for identification of enteroviruses:* Antisera was raised in animals against many echoviruses and coxsackie viruses because large number of viruses makes it impractical to perform individual neutralisation tests. These were pooled in an over lapping scheme to allow many viruses to be identified using as few as nine tests. Interpretation of the results was done with the assistance of a list of the neutralisation patterns of individual viruses.

The unknown virus was tested in duplicate against a trivalent pooled polio antisera (PP) a coxsackie virus B1-6 pool (CP), and seven pools against coxsackie virus A9 and 20 echoviruses (A-G). 50 µl of antisera was added to appropriate wells in a microtitre (96 wells) plate. 50 µl of test sample (10<sup>-2</sup>) dilution was added onto the antisera. The plate was covered with a lid and incubated for one hour at 36°C in a CO<sub>2</sub> incubator. RD cells were trypsinised and a suspension of approximately 1.5 x 10<sup>5</sup> Cells/ml prepared. 100 µl of cell suspension was distributed in all wells and the plate covered and incubated at 36°C in a CO<sub>2</sub> incubator. Plates were examined daily using an inverted microscope and CPE recorded until 24 hours after CPE in virus control wells reached 100%.

## RESULTS

*Electron microscopy observation:* During observation the sample under the transmission electron microscope, virus particles measuring 20-25 nm in diameter were detected. Photographic pictures of these negatively stained particles was taken and then developed into micrographs (Figure 1).

*Animal inoculation:* After observing the mice daily for up to 21 days, there was no sign of paralysis or any other form of illness detected.

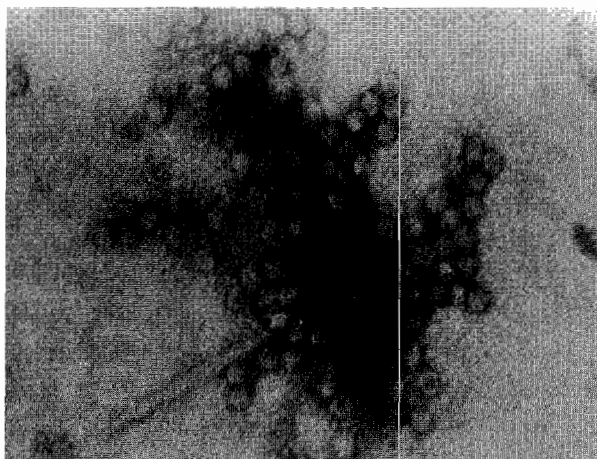
*Cell culture and viral propagation:* Cytopathic effect was observed in rhabdomyosarcoma cells within six

days of incubation. The cells supernatant was then put in fresh rhabdomyosarcoma cells and cytopathic effect was observed within three days.

No cytopathogenic effect was observed in L-20 B cells.

**Figure 1**

*Direct transmission electron microscopy image and morphology of echoviruses in an area of the grid. Particles were negatively stained using 2% phosphotungstic acid (PTA) pH 7.2*



*Neutralisation test for identification of enteroviruses:* The virus is identified by the pattern of inhibition of CPE by antiserum pools. Based on a chart of neutralisation patterns of individual viruses, the isolate was identified as echovirus 7.

## DISCUSSION

Gastro-enteritis due to echoviruses has previously been under reported. This could be due to the fact that these viruses have mainly been known to be associated with aseptic meningitis in children. Echoviruses are not easily diagnosed in many laboratories due to lack of facilities to undertake polymerase chain reaction and tissue culture. Many laboratories also do not have the electron microscope that can be used to visualise virus particles. Even with the electron microscope, experience is needed to detect these viruses which are among some of the smallest viruses.

When observing the grids under the Electron Microscope, numerous particles measuring 20-25 nm in diameter were detected from the stool samples obtained from a male child aged one year admitted to the hospital due to diarrhoea. Due to the size and shape of the virus particles, it was suspected to be a member of the family Picornaviridae. Injection of 10% stool

60 M - 200 FT

H

36 M - 120 FT

ELPS

24 M - 80 FT


REDUCE

18 M - 60 FT

THE APPEARANCE

12 M - 40 FT

OF SCARS AND STRETCH MARKS



Bio-Oil® helps improve the appearance of both old and new scars and is suitable for all scar types, including striae. Apply Bio-Oil to the affected area twice daily, massaging until fully absorbed. It is available at pharmacies at the following recommended price: KSHS 695.00 (60ml). Bio-Oil is distributed by Healthwise Limited (tel: 020-2727-867). [www.bio-oil.com](http://www.bio-oil.com)

**Results of clinical trials:** Photobiology Laboratory MEDUNSA 2006 **1.** Scars: Independent expert clinician observed a 65% improvement in appearance at 4 weeks (panellists: 24 Caucasians age 18-60, comprising 22 females & 2 males) **2.** Striae: Independent expert clinician observed a 50% improvement in appearance at 8 weeks (panellists: 20 Caucasian women age 18-55) **3.** Pigmentation: Independent expert clinician observed a 93% improvement in appearance at 6 weeks (panellists: 30 women age 18-55, comprising 15 Caucasian & 15 Negroid). All trials were single-blind & randomized with intra-subject comparison under controlled conditions.



T.W.I.G. SA, 2004



TELKOM  
VoIP 888

The way Kenya is talking to the world.



Now you can make high quality VoIP international calls to Africa and all over the world using Telkom payphones, Pre-paid & Postpaid phones and The Big 5 calling cards. From just Kshs 15 a minute, it's the way Kenya is talking to the world.

 **TelkomKenya**  
We've got you talking

INTERNATIONAL CALLS FROM ONLY KSH15/ MIN



**VoIP CALLS ON  
POSTPAID**

Dial: 888 followed by the country code, area code and number you wish to call.

*No explanation required*



**VoIP CALLS ON  
PRE-PAID**

(Make sure your pre-paid account is topped up with any Big Five Calling Card)

Dial 0845 and then dial: 888 followed by the country code, area code and number you wish to call.



**VoIP CALLS  
ON A  
PAYPHONE**

Slot in your coins and dial 888 followed by country code, area code and the number you wish to call. Please note that when using the calling card refer to the instructions on VoIP calls using the calling card.



**VoIP CALLS  
USING A  
CALLING CARD**

(Use the Big Five Calling Card on any Telkom phone)  
Dial 0844, followed by the PIN number and password and then dial: 888 followed by the country code, area code and number you wish to call.

TELKOM  
VoIP 888

The way Kenya is talking to the world.



Now you can make high quality VoIP international calls to North America and all over the world using Telkom payphones, Pre-paid & Postpaid phones and The Big 5 calling cards. From just Kshs 15 a minute, it's the way Kenya is talking to the world.

 **TelkomKenya**  
We've got you talking

INTERNATIONAL CALLS FROM ONLY KSH15/ MIN



**VoIP CALLS ON  
POSTPAID**

Dial: 888 followed by the country code, area code and number you wish to call.

[www.telkomkenya.com](http://www.telkomkenya.com)



**VoIP CALLS ON  
PRE-PAID**

(Make sure your pre-paid account is topped up with any Big Five Calling Card)

Dial 0845 and then dial: 888 followed by the country code, area code and number you wish to call.



**VoIP CALLS  
ON A  
PAYPHONE**

Slot in your coins and dial 888 followed by country code, area code and the number you wish to call. Please note that when using the calling card refer to the instructions on VoIP calls using the calling card.



**VoIP CALLS  
USING A  
CALLING CARD**

(Use the Big Five Calling Card on any Telkom phone)  
Dial 0844, followed by the PIN number and password and then dial: 888 followed by the country code, area code and number you wish to call.



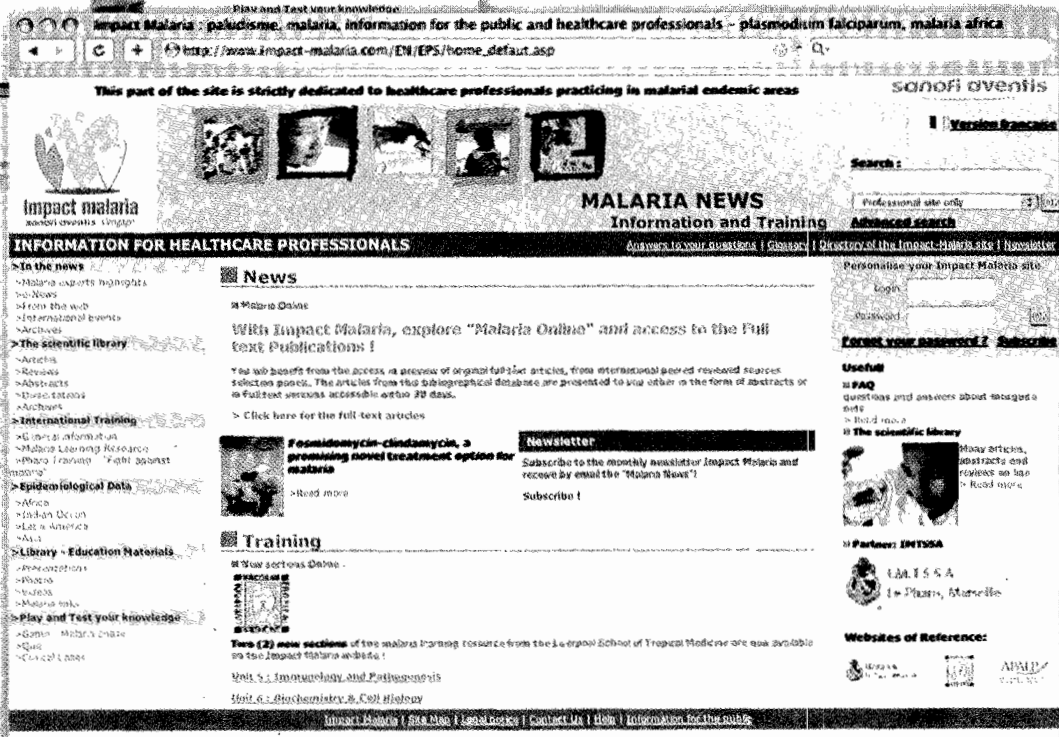
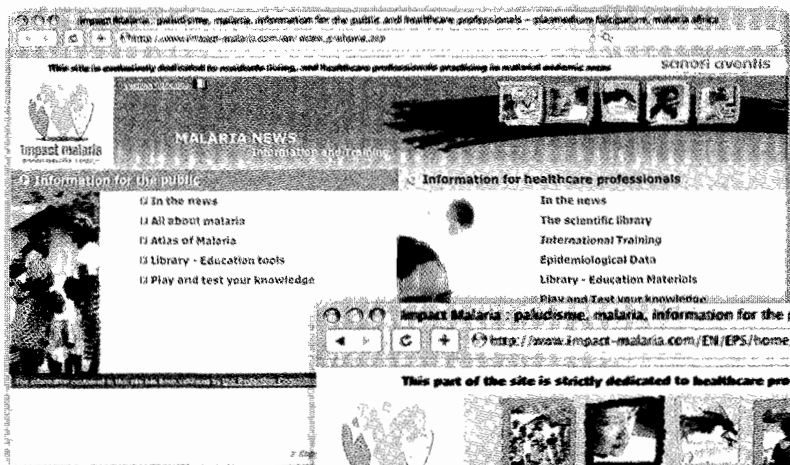


Impact malaria

M a l a r i a n e w s

www.impact-malaria.com

Information and training web site



- Scientific news on malaria: full text articles, abstracts, news
- A remote training tool for healthcare professionals
- A global information base on the disease
- Real time information on the progress of the anti-malaria fight
- Knowledge tests and quizzes



sanofi aventis

Because health matters

suspension intracerebrally into a litter of newborn suckling mice did not cause any visible illness in the mice. This was an indication that the viruses were most likely to be echoviruses and not coxsackie viruses. Prototype echovirus strains must not produce disease in suckling mice, rabbits, or monkeys, while Coxsackie viruses are known to be highly infective to newborn mice, in most cases resulting in flaccid paralysis (8). This viruses were found to cause cytopathic effect in rhabdomyosarcoma cells and not L-20B cells. The L-20 B cells are special cells with specific membrane receptors for infection with poliovirus and are used for detection of poliovirus. Poliovirus grows in both cell lines but non polioviruses do not grow in L-20 B Cells. The fact that the viruses did cause cytopathic effect in rhabdomyosarcoma cells and not in L-20 B cells was a confirmation that they were non polio enteroviruses.

Echoviruses have previously been shown to be associated with gastro-enteritis. In Japan there was an outbreak of gastro-enteritis caused by echovirus type six in a children orphanage (9). Other studies have also shown a link between echoviruses and gastro-enteritis (10,11).

Work done by Christenten *et al* in Norway on enteroviral diseases diagnosed from 1992 to 2001, enterovirus infections were diagnosed by polymerase chain reaction, isolation by tissue culture, and in a few cases by electron microscopy. One hundred and seventy two of the isolates were typed. Meningitis, gastro-enteritis, respiratory disease and fever were the most frequent diseases associated with infection and echovirus 7 was found to be one of the causes of gastro-enteritis (12).

In conclusion, this is the first case to our knowledge of published information of echovirus causing gastro-enteritis in a child in Kenya. It will also be the first detection by electron microscopy. With this finding, echoviruses could be another virus apart from rotaviruses adenoviruses, caliciviruses and noroviruses causing gastro-enteritis in young children. More work needs to be done to strengthen this hypothesis.

#### ACKNOWLEDGEMENTS

To the staff of Mbagathi District Hospital for allowing us to undertake this study and Mr Ernest Mabinda for helping in the mice inoculation work. This paper

is published with approval of the Director, Kenya Medical Research Institute to whom we are grateful for allowing us to undertake this study.

Mr. Nyangao is a Research Officer at the Viral Diarrhoea Section. Centre for Virus Research, Kenya Medical Research Institute. He is working on viral diarrhoea pathogens, mainly rotaviruses.

#### REFERENCES

- Hoshino Y. and Kapikian A.Z. Rotavirus serotypes: classification and importance in epidemiology, immunity and vaccine development. *J. Hlth. Popul. Nutr.* 2000; **18**: 5-14.
- Clark B. and McKendrick M. A review of viral gastro-enteritis. *Curr. Opin. Infect. Dis.* 2004; **17**: 461-469.
- Melnick J.L. My role in the discovery and classification of the enteroviruses. *Annu. Rev. Microbiol.* 1996; **50**: 1-24.
- Lum L.C., Chua K.B., McMinn P.C., *et al.* Echovirus 7 associated encephalomyelitis. *J. Clin. Virol.* 2002; **23**: 153-160.
- Handsher R., Shulman L.M., Abramovitz B., *et al.* A new variant of echovirus 4 associated with a large outbreak of aseptic meningitis. *J. Clin. Virol.* 1999; **13**: 29-36.
- Lutwick L.I. and Hussain S. Echoviruses. [www.emedicine.com/med/topic632.htm](http://www.emedicine.com/med/topic632.htm)
- Grauballe A.Z., Vestergaard B.F., Meyling A. and Genner J. Optimised enzyme-linked immunosorbent assay for detection of human and bovine rotavirus in stools: Comparison with electron-microscopy, immunoelectro-osmophoresis, and fluorescent antibody techniques. *J. Med. Virol.* 1981; **7**: 29-40.
- Jawetz, Melnick & Adelberg's. *Medical Microbiology Book*. Nineteenth Edition. 1991.
- Abe O., Kimura H., Minakami H., *et al.* Outbreak of gastro-enteritis caused by echovirus type 6 in an orphanage in Japan. *J. Infect.* 2000; **41**: 285-286.
- Field P.R., Murphy A.M., Gibson I.I.B. and Rennie T.F. An outbreak of gastro-enteritis associated with Echovirus type I. *Med J. Aust.* 1968; **1**: 9-11.
- De Sanctis Monaldi T., Benedetto A., Frugoni G. and Formato. Epidemic of 'acute enteric disease' associated with infection by 'Echo 14' virus. *Helv. Paediatr. Acta.* 1966; **21**: 239-249.
- Christensen A. and Nordbo S.A. Enterovirus infections diagnosed in middle Norway during the period 1992-2001. *Tidsskr. Nor. Laegeforen.* 2003; **123**: 3180-3183.