

East African Medical Journal Vol. 78 No. 1 January 2001

VAN der WOUDE SYNDROME WITH MENTAL RETARDATION: CASE REPORT

B.T. Ugwu, BM, BCh, FWACS and J.T. Momoh, FRCS(C), FMCS, Department of Surgery, Jos University Teaching Hospital, Jos, Nigeria.

Request for reprints to: Dr. B.T. Ugwu, Department of Surgery, Jos University Teaching Hospital, P.M.B. 2076, Jos, Nigeria.

VAN DER WOUDE SYNDROME WITH MENTAL RETARDATION: CASE REPORT

B.T. UGWU and J.T. MOMOH

SUMMARY

A report of a four and half-year old African patient with Van der Woude syndrome and mental retardation is reported. In addition to cleft lip/palate, hypodontia and lower lip pits; features consistent with Van der Woude syndrome, he manifested features consistent with growth and mental retardation. A genetic basis for these associated features can only be determined by detailed karyotype studies.

INTRODUCTION

Anne Van der Woude(1) in 1954 described a familial syndrome of cleft upper lip and palate associated with discharging lower lip sinuses. This syndrome has been traced to deletion or translocation on chromosome 1q32 (2-5). In very rare instances, Van der Woude syndrome has been reported in association with other genetic abnormalities such as Kabuki Make-up syndrome(6), characterised by typical facial appearance, skeletal abnormalities, post-natal growth retardation, mental retardation and anomalous dermatoglyphic patterns.

CASE REPORT

I.A. a four and half-year old boy was delivered at term by spontaneous vaginal delivery after normal pregnancy with an Apgar score of 8 assessed at about five minutes post delivery. His parents were young, apparently normal, non-con sanguinous and both of them Tivs (an indigenous ethnic group in the Middle Belt of Nigeria). His birth weight was 3.05kg.

His parents and the attending mid-wife at birth noted the

Figure 1a

Picture of the patient showing a pair of lower lip pits and the repaired bilateral cleft upper lip

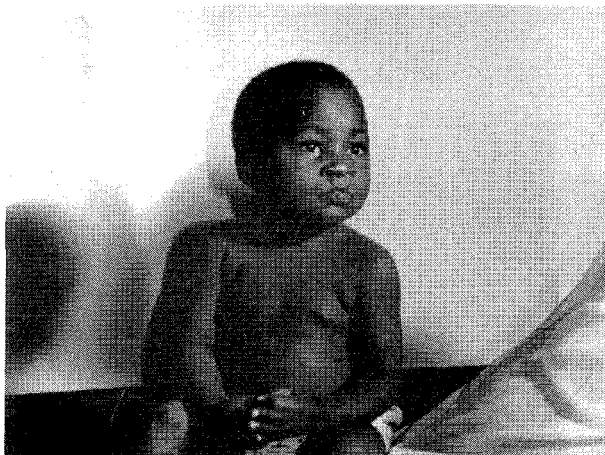


Figure 1b

Van der Woude syndrome with short stature bilateral genu vara and the right paraumbilical hernia

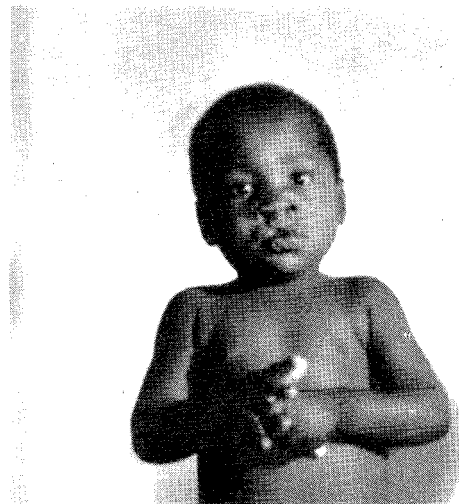
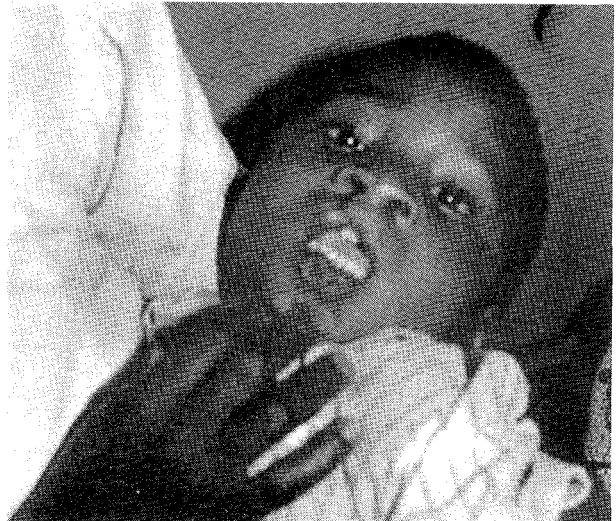


Figure 1c

Hypodontia of upper lateral incisors



presence of cleft upper lip and palate and an umbilical hernia. A few days later his parents noticed a pair of discharging sinuses in the lower lip just close to the mid-line, the discharge had remained clear and slimy like saliva. There was no family history of similar congenital anomalies. The patient presented late because of his parents' ignorance and their misguided belief in local taboo.

At the age of four and half-years, the patient was referred to us for cosmetic reasons and also because of suspected mental retardation. We found him very active, giggling without apparent cause, with bilateral cleft lip, left complete cleft palate, a pair of serous discharging, symmetrical sinuses one on either side of the mid-line of the lower lip and hypodontia of the lateral upper incisors. He also presented with a paraumbilical hernia and bilateral genu vara. Though there was no obvious defects in axial skeleton, his height was diminutive but his head circumference was within normal limits for his age. There was obvious mental retardation - drooling of saliva, loss of concentration as well as giggling unprovoked with features of infantile autism. Despite his physical and mental defects, his serum calcium, proteins and thyroid functions tests were all within normal limits. His cleft upper lip and palate were successfully repaired (Figure 1).

DISCUSSION

This patient, a native African, has all the composite features of Van der Woude syndrome: bilateral cleft upper lip and palate, discharging symmetrical lower lip sinuses and hypodontia. This syndrome is usually familial but could occur spontaneously without obvious family history as is the case in this patient. It is inherited as an autosomal dominant genetic disorder located at various loci on chromosome 1q, especially on loci 1q32.1 a region

implicated in Van der Woude syndrome and microcephaly(2-5). Treatment involves staged cleft lip and palate repair as well as wedge excision of the sinuses with wound closed in eversion to prevent unsightly notching(1).

In the absence of facilities in Nigeria for detailed genetic studies such as karyotyping, a genetic basis for the associated mental retardation and small stature in this patient could not be established.

REFERENCES

1. Mann, C.V., Russel, R.C.G. and Williamsn, N.S. (Eds); Van der Woude Syndrome - In: *Bailey and Love's Short Practice of Surgery*; 22nd edition, pages 426-427.
2. Murray, J.C., Nishimura, D.Y., Buetow, K.H. Ardinger, H.H., Spence, M. A., Sparkes, R.S. and Falk, R.E. Linkage of an autosomal dominant clefting syndrome (Van der Woude) to loci on chromosome 1q. *Amer. J. Hum. Genet.* 1990; **46**:486-491.
3. Kenwrick, S., Leversha, M., Rooke, L. Hasler, T. Sonderegger, P. Localisation of the human TAX-1 gene to 1q 32.1: a region implicated in microcephaly and Van der Woude syndrome. *Hum. Mol Genet.* 1993; **2**:1461-1462.
4. Bocian, M., Waler, A.P. Lip pits and deletion 1q32-41. *Amer. J. Med. Genet.* 1987; **26**:437-443.
5. Frazal, J. and Schinzel, A. Report of the Committee on Clinical Disorders and Uniparental Disomy. *Cytogenet. Cell Genet.* 1991; **58**:986-1052.
6. Franceschini, P., Vardeu, M.P., Guala, A. Franceschini, D., Testa, A., Corria, A. and Chiabotto, P. Lower Lip pits and complete corrias idiopathic precocious puberty in a patient with Kabuki Make-up (Niikawa-Kuroki) syndrome. *Amer. J. Med. Gen.* 1993; **47**: 423-425.