

East African Medical Journal Vol. 78 No. 7 July 2001

SPLENIC SIZE DETERMINATION IN SICKLE CELL ANAEMIA: AN ULTRASONOGRAPHIC STUDY

A. A. Olatunji, MBBS, FMCR, Lecturer/Consultant Radiologist, Department of Radiology and P. O. Olatunji, MBBS, WACP, FMCPATH, Senior Lecturer/Consultant, Haematologist, Department of Haematology, Faculty of Health Sciences, University of Ilorin, PMB 1515, Kwara State, Nigeria.

Request for reprints to: Dr. A.A. Olatunji, Department of Radiology, Faculty of Health Sciences, University of Ilorin, P.M.B. 1515, Ilorin, Kwara State, Nigeria.

SPLENIC SIZE DETERMINATION IN SICKLE CELL ANAEMIA: AN ULTRASONOGRAPHIC STUDY

A. A. OLATUNJI and P. O. OLATUNJI

ABSTRACT

Objectives: To examine the generally accepted concept of autosplenectomy in patients with sickle cell anaemia, and determine the relationship between age, the steady state PCV and splenic size.

Design: Case - control study.

Setting: Sickle Cell Clinic, University of Ilorin Teaching Hospital, Ilorin, Nigeria.

Subjects: Sickle cell anaemia patients aged three to 47 years, while the controls included age and sex matched patients attending the General Outpatient Department for minor ailments.

Interventions: Longitudinal and coronal sizes of the spleen were measured antemortem, by ultrasonographic method, in 98 adult sickle cell anaemia patients and 48 control subjects and compared. The splenic size was correlated with age and PCV among sickle cell anaemia patients.

Main outcome measures: Determination of longitudinal and coronal sizes of the spleen, comparison of mean splenic sizes of patients with those of controls by Student's t test, and correlation of age and PCV with splenic sizes.

Results: Both mean longitudinal and coronal diameters, and surface area were found to be higher in the sickle cell anaemia patients compared to the controls. While the longitudinal diameter increased with age continuously, the coronal diameter decreased after the age of 30 years. There were no significant correlations between the splenic sizes and PCV and number of crises per year.

Conclusion: The general belief that sickle cell anaemia patients suffer anatomical autosplenectomy was not confirmed. This could be due to the effect of malaria and improved clinical care.

INTRODUCTION

Sickle cell anaemia is the commonest genetic disorder in Nigeria and it constitutes a major national health problem. The incidence of sickle cell trait in Nigeria is about 25% of the total population compared with the seven per cent in the American Negro (1). Sickle cell haemoglobinopathy is predominantly a disease of the Negroid race but isolated cases have been found in the Greeks, Mexicans and Arabs (2,3) and in excavated Red Indian skulls (4). Radiological changes in patients with sickle cell anaemia has been extensively studied by various authors in the past and documented (3-7).

The dynamic nature of the imaging techniques in radiology, particularly with ultrasonography has opened up a new approach to the study of various organs of the body especially of the spleen, a target organ in sickle cell anaemia. The importance of ultrasound in the study of the pathologic conditions of the spleen has been attributed to its simplicity of use and the absence of stress to the patient (8). Hence, ultrasonography is the method of choice for the determination of position, shape, size and volume

of most organs of the body, diagnosing and recording the changes within them (8).

Ultrasonography had subsequently been used for the following: (a) determination of the predictive capability for differentiating veno-occlusive disease (sickle cell crisis) from acute biliary disease (9); (b) the diagnosis, management and follow up of splenic diseases generally (10,11) and; (c) detection of the frequency of abnormalities of the spleen and other abdominal organs among Japanese adults (12).

The appearance and changes in the spleen in patients with sickle cell anaemia have been previously described from autopsy findings. In early life, the spleen is enlarged, dark purple and soft with a smooth surface (13). Later in life, the spleen becomes firm and nodular with depressed scars. Finally, the spleen becomes reduced to a small wrinkled remnant often buried in adhesions, the pulp being completely replaced by thick walled vessels and fibrous tissue and covered by a grossly thickened capsule. This siderofibrotic spleen is in effect an autosplenectomy (6).

From all the available data very little work has been done on ultrasonography of the spleen in sickle cell anaemia patients(8,14). This present study was thus aimed at documenting the antemortem size of the spleen in patients with sickle cell anaemia by means of ultrasonography. Changes in size with age were also determined.

MATERIALS AND METHODS

One hundred and fifty subjects, aged three to 47 years, made up of 100 sickle cell anaemia patients and 50 age and sex matched controls were recruited into the study. The patients were recruited from the paediatric and adult sickle cell anaemia clinics of the University of Ilorin Teaching Hospital (UIH), Ilorin, while the control subjects were drawn from among hospital patients attending the general outpatient clinic for acute medical conditions. All the sickle cell patients were in steady condition, having been free from crises for at least the previous four weeks. A protocol incorporating a questionnaire was administered on each patient to record their demographic data and frequency of crises. The packed cell volume (PCV) was determined for each subject by the microhaematocrit centrifuge method. All the subjects had ultrasonographic scanning of the abdomen for the measurement of the longitudinal and coronal diameters of the spleen.

Abdominal scan: Ultrasonographic scanning of the spleen was carried out using a Siemens sector scanner with an angled 5 Mega Hz transducer to show the complete view of the spleen from which its size, architecture, shape, outline and possibly any gross pathology could be determined. The stomach was filled with water which transmitted the ultrasound beam and thus allowed the normal spleen to be imaged in transverse section when necessary. This technique allows a differentiation between the spleen and the liver.

The longitudinal size was obtained by scanning the patient along the tenth and eleventh intercostal spaces in an oblique plane that runs along its longitudinal axis. The coronal size was obtained by scanning along the eleventh intercostal space. A transverse scan was also done with the patients still in the right decubitus position but with a change in the polarity of the direction of the probe. Each patient was scanned in neutral respiration, since a deep breath might have drawn the lung over the spleen. In splenomegaly, additional subcostal sector views under the left costal margin was helpful as well as serial longitudinal and transverse sections. The splenic artery was seen as having highly reflective rim over a very short course.

RESULTS

One hundred sickle cell anaemia patients with a mean age of 13.9 ± 7.4 (range 3 - 47 years) made up of 48 (48%) males and 52 (52%) females were entered into the study. Of these, 38 (38%) were in the 6 - 10 age range, 31 (31%) in the 11 - 15 year group, 16 (16%) were in the 16-20 year range, 9 (9%) in the 21 - 25 years age group and 3 (3%) each were in the 26 - 30 years and the over 30 years age group. However, only 98 patients and 48 age and sex-matched control subjects had complete data which could be analysed.

The mean longitudinal length of the spleen in patients with sickle cell anaemia was 101.7 ± 18 while that in the control subjects was 95.6 ± 13 . The length in the patients

was significantly more than that of the control subjects ($p = 0.02$). The patients had a mean coronal diameter of 98 ± 18 mm while that in the control subjects was 92.4 ± 11 . The difference was not statistically significant.

The longitudinal diameter among the patients was 93 ± 17.3 for ages 1 - 10 years, 108 ± 17.8 for ages 11 - 20 years, 103.0 ± 12.6 for ages 21 - 30 years and 98.5 ± 19.7 for those over 30 years old. For the control population the longitudinal diameters were 89 ± 10.2 for 1 - 10 years, 98.0 ± 16 for 11-20 years, 99.0 ± 11.7 for 21- 30 years and 95.0 ± 10.2 for those over 30 years (Figure 1). In the patients population, the coronal diameters were 92.4 ± 16.7 for 1-10 years, 101.9 ± 16.2 for 11-20 years, 102.6 ± 28.5 for 21-30 years, and 92.8 ± 4.6 for those over 30 years. Among the control subjects, the coronal diameters were 87.2 ± 10.1 for 1-10 years, 93.0 ± 9.6 for 11-20 years, 92.0 ± 11.1 for 21-30 years, and 105.8 ± 7.8 for those over 30 years. There were significant differences in measurement of longitudinal diameters among patients and coronal diameters among controls ($p=0.004$ and $p=0.01$ respectively) (Figure 2).

Figure 1

Longitudinal size of the spleen in patients and controls

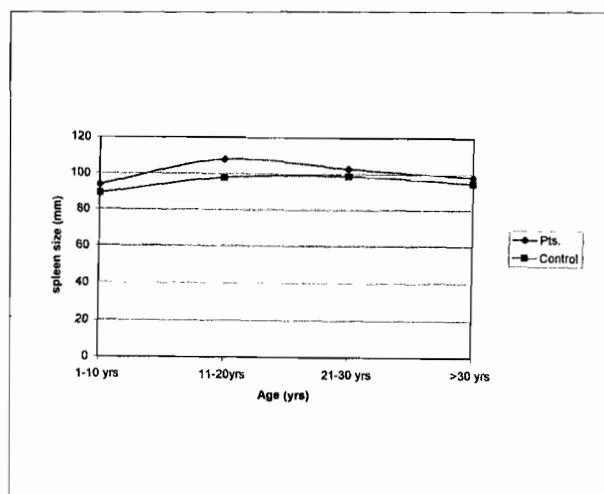


Figure 2

Coronal sizes of the spleen in patients and controls

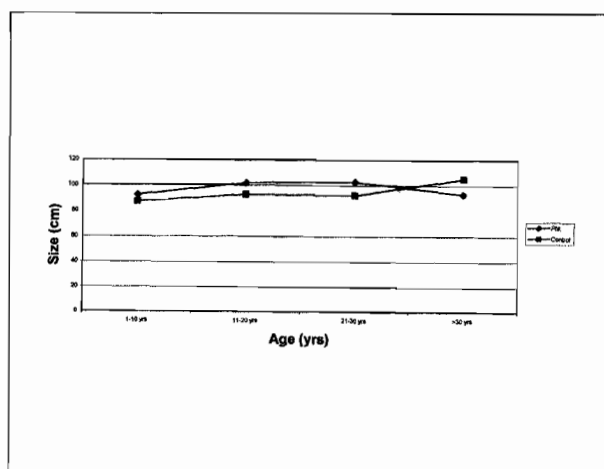
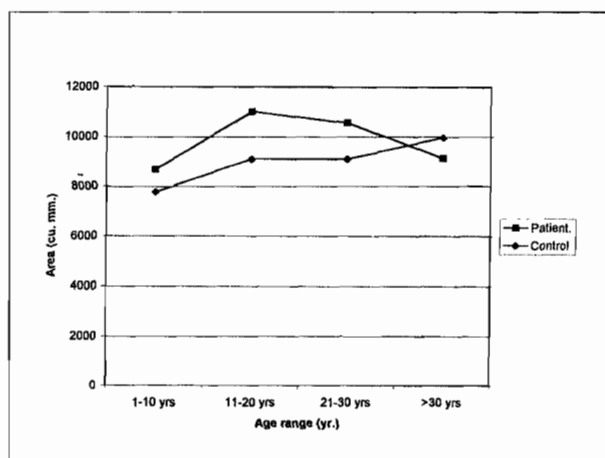


Table 1
Surface area of the spleen in patients and controls

Age range (yrs)	Patients		Controls	
	No.	Mean surface area (mm ²)	No.	Mean surface area (mm ²)
1-10	38	8882	13	7818
11-20	46	11197	15	9130
21-30	12	10786	15	9144
>30	4	9137	5	10033
Total	100	10186	48	8874

Figure 3

Splenic surface area in patients and controls



The surface areas as determined by the product of the longitudinal and coronal diameters were 10186 mm² for the patients and 8873 mm² for the control population. The mean surface area was larger in the patients than in the control population ($p = 0.013$). Table 1 and Figure 3 show the changes in surface area with age.

The correlation coefficients (r) were: -0.14 for longitudinal diameter and packed cell volume (PCV), 0.07 for coronal diameter and PCV, -0.07 for longitudinal diameter and number of crises per year, and 0.00 for coronal diameter and number of crises per year. There was no significant correlation between spleen sizes and PCV or numbers of crises per year.

DISCUSSION

Ultrasonography has become a major diagnostic tool in soft tissue pathology and other conditions, particularly in the pelvis and abdomen. Its advantage is due to the absence of radiation and non-requirement for contrast media and its attendant reactions, as well as the possibility of accurate measurement. The discovery of normal size and enlarged spleens in patients with sickle cell anaemia at postmortems prompted the need to re-evaluate the general belief that autosplenectomy is the rule among them. The choice of ultrasonographic measurement in this study was made because of the above advantages.

The patients and controls from below ten years were included in order to determine the effect of age. As would be expected, and due to already documented shortened lifespan, the majority of patients were less than 25 years old. The mean longitudinal and coronal diameters of the spleen were significantly longer in sickle cell anaemia patients than in the normal controls, which seem to disagree with the general understanding that profuse fibrosis reduces the size of the spleen in these patients. However, the sizes according to age groups showed that the longitudinal diameter among patients and control subjects, and the longitudinal diameter among patients increase with age up to the age of 30 years when it declines. This is consistent with the findings of David-West(15) who studied spleen weights in Ibadan. The longitudinal diameter in the patients followed the trend of the controls, the coronal diameter increased with age even beyond the age of 30 years. This difference in the coronal diameter was reflected in the crude surface area obtained by multiplying the longitudinal diameter by the coronal diameter. Thus, the sickle cell anaemia patient begins life with a larger spleen than the control but after the age of 30 years, the coronal diameter and the surface area reduce significantly.

The lack of significant correlation between the PCV, number of crises per year and splenic diameter indicates that the spleen is not a critical indicator of clinical severity. Watson *et al*(16) had reported that a considerable degree of splenic enlargement was associated with severe anaemia and less frequent painful crises. This was confirmed more recently by Adeodu and Adekile(17).

On the other hand, the study of Adekile *et al*(18) demonstrated that the splenomegaly found among sickle cell anaemia patients is due to response to malarial antigen signified by the high level of antimalarial IgM. Improvement in the health education about the condition, observation of precautions and availability of effective antimalarials and antibiotics might have contributed to reduced frequency of sickling as well as the degree of autosplenectomy.

This study therefore shows that sickle cell anaemia patients have longer longitudinal and coronal diameters as well as surface area of the spleen compared to the controls, which conflicts with the generally held view of autosplenectomy. A reduction in the coronal diameter after the age of 30 years is the only indicator of splenic size reduction.

ACKNOWLEDGEMENTS

To the Chairman, Ethical Research Committee, University of Ilorin Teaching Hospital for permission to publish this work.

REFERENCES

- Carrol D.S. and Evans J.W. Recent findings in sickle cell anaemia. *Radiology* 1949; **53**: 834 - 845.
- Kraft E. and Bertel G. Sickle, cell anaemia. *Amer. J. Roentgenol.* 1947; **57**: 224 - 231.
- Ibrahim S.A. and Mustapha, D. Sickle cell haemoglobin disease in a Sudanese family. *Brit. Med. J.* 1967; **2**:715.

- 4 Moore S. Bone changes in sickle cell anaemia. *J. Missouri Med. Ass.* 1929; **26**: 561 - 564.
- 5 Lagundoye S.B. Radiological features of sickle cell anaemia and related haemoglobinopathies in Nigeria. *Afr. J. Med. Sci.* 1970; **1**: 315 - 342.
- 6 Lagundoye S.B. and Ude A.C. Radiology of sickle cell disease, *Dokita.* 1971; **7**: 23 - 29.
- 7 Kolawole T.M. and Bohrer S.P. Splenic abscess and the genetics for haemoglobin S. *Amer. J. Roentgenol.* 1973; **119**: 175 -189.
- 8 Wenz W. and Bodendorfer G. Modern, imaging procedure in splenic disease. *Radiologe* 1987; **27**:11-19.
- 9 Serifini A.N., Spoliansky G., Sfakianakis G.N., Montahiro B. and Jensen W.N. Diagnostic studies in patients with sickle cell anaemia and acute abdominal pain. *Arch. Intern. Med.* 1987; **147**:1061-1062.
- 10 Heyder N. Diagnosis of gastroenterologic diseases with sonography, part 3: pancreas and spleen. *Fortschr. Medica.* 1991; **109**: 692 - 696.
- 11 Gorge C. and Schwerk W.B. Sonographic investigation in the diagnosis of intrasplenic collection. *Bildgebung.* 1991; **58**: 76 - 82.
- 12 Oshibuchi M., Nishi R., Salo M., Ohtake H. and Okuta I.C. Frequency of abnormalities detected by abdominal ultrasound among Japanese adults. *J. Gastroent. Hepatol.* 1991; **6**: 165 - 168.
- 13 Sergent, G.R. Sickle cell disease. Oxford University Press. 1988; 109 -122:206 - 212.
- 14 Weill F., Rohmer P., Didier D. and Coche G. In the patients: Ultrasound of the traumatized spleen: left butterfly sign lesion masked by echogenic blood clots. *Gastroint. Radiol.* 1988; **13**: 169 - 172.
- 15 David-West A.S. Spleen weight distribution in Ibadan and its relationship to disease. *Afr. J. Med. Sci.* 1982; **11**: 53-59.
- 16 Watson M.J., Lichtman H.C. and Shapiro H.D. Splenomegaly in sickle cell anemia. *Am. J. Med.* 1956; **20**:196-206.
- 17 Adekile A.D., Adeodu O.O., Jeje A.A. and Odesanmi W.O. Persistent gross splenomegaly in Nigerian patients with sickle cell anaemia: relationship to malaria. *Ann. trop. Paediat.* 1988; **8**:103-107.
- 18 Adeodu O.O. and Adekile A.D. Clinical and laboratory features associated with persistent gross splenomegaly in Nigerian children with sickle cell anaemia. *Acta Paediat. Scand.* 1990; **79**:686-690.

EAMJ INTERNET ADDRESS

"The East African Medical Journal is now available online as well as in print. Subscribers and readers interested in viewing the Internet version may access it using the following address: <http://bioline.bdt.org.br/ea>

The Online version is distributed by the non-profit service, Bioline Publications, a South/North partnership whose aim is to facilitate global access to bioscience and medical research publications, with emphasis on journals published in the developing world.

Subscription to the online version may be made by completing the Registration Form available from the Bioline home page (<http://bioline.bdt.org.br>). Readers may take out an annual subscription or purchase single documents. Abstracts are available without registration and free of charge."