

East african Medical Journal Vol. 89 No. 5 May 2012

ILIOPSOAS MYOFIBROSITIS – A DIAGNOSTIC CONSIDERATION FOR CHRONIC LOWER ABDOMINAL PAIN IN RURAL KENYA

J. Tjong, MD, PhD, FRCPC and J. Tjong, AIC Kijabe Hospital, P.O.Box 20-00220, Kijabe, Kenya

Request for reprints to: Dr. J. Tjong, AIC Kijabe Hospital, P.O.Box 20-00220, Kijabe, Kenya

ILIOPSOAS MYOFIBROSITIS – A DIAGNOSTIC CONSIDERATION FOR CHRONIC LOWER ABDOMINAL PAIN IN RURAL KENYA

J. TJONG and J. TJONG

SUMMARY

Diagnosis for lower abdominal pain is always challenging clinically and more so in the setting of rural Africa. Eighteen cases of sonographically-shown ipsilateral enlargement and echo alteration of iliopsoas muscle have been compiled in patients with chronic lower abdominal pain. Seventy percent of the cases were treated with antibiotic and 30% with additional anti-inflammatory drug. A telephone interview follow up was done to nine patients, in which eight reported improvement after treatment. One case was biopsied and shown to be myofibrositis of iliopsoas muscle.

INTRODUCTION

The diagnosis of chronic lower abdominal pain can be challenging. Patients often present with longstanding non-specific symptoms, and often in a rather generalised area. In the rural Kenyan setting, these patients might have endured the pain for a long period of time for lack of healthcare, or because the symptom has been treated in various ways with no relief. In Kijabe hospital, a rural Kenyan hospital, the outpatient department is almost daily presented with such cases.

The entity of myofibrositis of iliopsoas muscles has been described in the 1940's as a cause of lower abdominal pain Greene (1). The entity has somehow been lost in the differential diagnosis, or at least it has not been readily included in the daily differential diagnosis. Myofibrositis of iliopsoas muscles is inflammation of the muscle which is usually associated with fibrosis Blair (2).

In rural Africa, where the infection burden is higher, there are many cases of pyomyositis of the muscles in which there is frank and often multifocal pyogenic infection of large muscles.

From October 2010 to May 2011, multiple cases of a sonographically-detected abnormalities in the iliopsoas muscle(s), from patients presenting with chronic lower abdominal pain, were collected. The following is a compilation of 18 cases of iliopsoas myofibrositis.

Cases:

Kijabe hospital, located in the town of Kijabe, is about 50 kilometres northwest of Nairobi, Kenya. Kijabe is

located in the Lari division of the Kiambu District. It has been in existence for more than 100 years, serving mostly the rural Kenyan population. Approximately 400 patients are seen daily. The radiology department has two ultrasound machines (1998 GE Logiq and 1996 Siemens Elegra).

From October 2010 to May 2011, 18 cases of sonographically detected asymmetric enlargement of iliopsoas muscle have been compiled. These patients presented with chronic lower abdominal pain with prior undiagnosed cause.

The iliopsoas muscles were evaluated in two planes of scanning. The thickness of the muscles was measured in AP and in sagittal planes. The bilateral iliopsoas muscles were examined by comparing them side by side. A moderate amount of pressure was applied to remove the sometime overlying bowel and to have better visualisation of the muscles. Color Doppler was performed to the muscles in some cases. In addition, a full evaluation of the pelvis organs was also performed to rule out other pathology in the uterus, ovaries, appendix and bowel.

These patients present with long standing pain in the lower quadrant. The duration of the symptom is from four weeks to nine years. The ages of these patients range from 19 to 63. The gender ratio favours females to males by 8:1. Most complained of pain characterised by intermittence in frequency and about equally divided between a sharp pain and a dull ache. Some described the pain as worsening with walking or bending (24%), or walking uphill (6%). Only one reported an associated chill, while the rest did not. The sidedness of pain is about two to one in favour of the right side versus the left. Upon clinical examination, the psoas sign was solicited in

nine cases and not in three cases, of those examined. A direct compression with the ultrasound probe could invariably solicit pain.

On ultrasound examination, it was noted that the iliopsoas muscle ipsilateral to the symptomatic side would be thickened relative to the non-symptomatic side, and shown to be heterogeneous in echo-texture with increased internal linear echo (which suggest some fibrosis plus / minus small calcification) (Figure 1 and 2). In a small number of cases, the involved muscle showed instead, a decreased echogenicity. This was seen in the cases with shorter pain duration prior to presentation. A small amount of subjacent free fluid was detected in one case. In all these cases no other pathology, such as inflamed appendix, pelvis mass, hydronephrosis, pelvis abscess or ovarian cyst or mass, was detected sonographically.

Figure 1

27 y/o male with four-month history of right lower quadrant pain. The ultrasound scan, in transverse plane, shows asymmetric enlargement of the right iliopsoas muscle. The involved muscle shows increased linear echogenic compared to the left (asymptomatic) side. (white arrows = iliopsoas muscles)

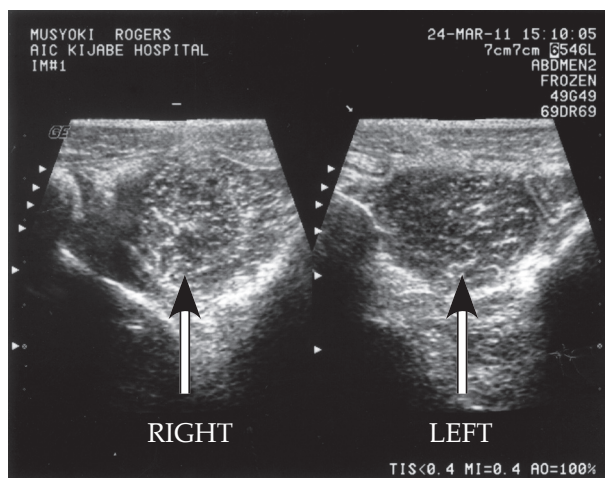
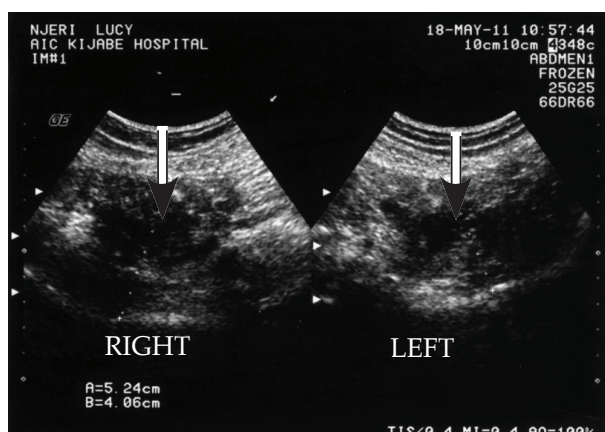


Figure 2

40 y/o female with one year history of right lower quadrant pain. The ultrasound, in sagittal plane, shows an enlarged right iliopsoas muscle (white arrows) and tenderness upon compression



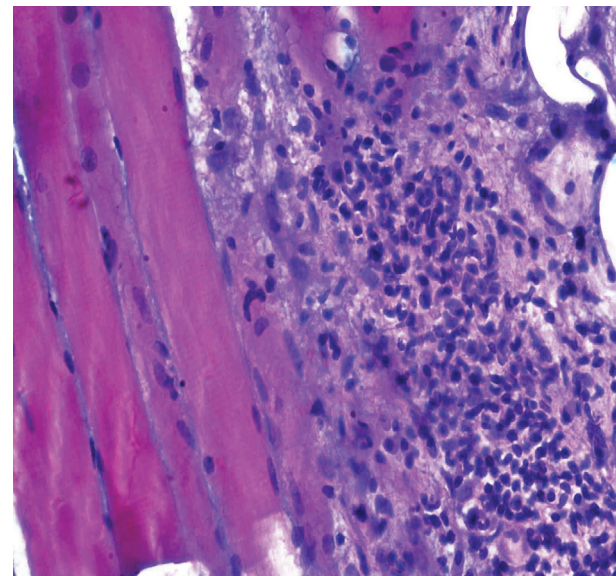
One case, which showed a very enlarged / mass-like iliopsoas muscle, was biopsied and pathologically shown to be "fibrosis between skeletal muscle fibres, and areas of slight chronic inflammation composed of lymphocytes and scattered eosinophils" (Figure 3). This case was subsequently operated on and the iliopsoas muscle was shown to be associated with a chronically inflamed appendix. It was not possible to know which preceded which.

About 70% of the cases were treated with broad-spectrum antibiotics and 30% were also treated with a non-steroidal anti-inflammatory drug.

A telephone follow-up was conducted for nine patients. From this group of followed patients, eight patients subjectively reported improvement, and of these two patients reported complete resolution of their symptom, and the others reported much improvement. The follow up was conducted from approximately one to three months after treatment / hospital visit.

Figure 3

In a 40 y/o female with right lower quadrant pain, the ultrasound showed a mass-like enlargement of the right iliopsoas muscle. Biopsy was performed with a 18 G needle. High power image: slight increased fibrosis between skeletal muscle fibres, and areas of chronic inflammation composed largely of lymphocytes and scattered histiocytes



DISCUSSION

Myofibrositis of iliopsoas muscle should be considered as differential diagnosis of chronic lower abdominal pain in rural Africa, especially when no other causes such as renal obstruction, pelvic, ovarian pathology or appendicitis is noted.

The etiology of iliopsoas myofibrositis is uncertain, but infection is the most likely cause given the subjectively reported improvement in the majority of the patients followed in these cases, after antibiotic treatment. It is also in keeping with the increased burden of infection in rural Africa. It is estimated that around 15% of patients in the hospital

has septicemia Reddy *et al* (3).

It is especially true amongst the population of lower social status in which a hygienic living environment is absent. Other etiology such as diverticulitis cannot be entirely ruled out, although epidemiologically the diverticular disease is rare in this part of the continent when people's diets contain high amount of roughage. Appendicitis can be missed on ultrasound, but it is usually rather acute in the duration of the symptom. Gynaecological causes such as ovarian cysts can, again, usually be detected on ultrasound. Pelvic inflammatory disease should also be considered in an appropriate setting. Other consideration of neuromuscular disease such as degenerative disease of the spine or muscular sprain should be entertained in an appropriate setting. These could be sorted clinically and also using x-rays of the lumbar spine.

A study on ultrasound appearance of tropical pyomyositis showed two kinds of appearance from frank abscess or diffuse infiltration of the muscle Belli *et al* (4). It is thus conceivable that the entity above is either a precursor to tropical pyomyositis or an "arrested" pyomyositis.

An interesting thought is whether myofibrositis has a predilection to iliopsoas muscle. It is a known fact that pyomyositis occurs in larger muscles, such as iliopsoas muscle. Whether it is from the fact that there is more blood perfusion to larger muscle mass or whether it is simply that only involvement of larger muscles produces enough symptoms for patients to seek medical help. An interesting observation is of female gender predomination amongst the cases observed. One may postulate that in this cultural setting, females do most of the day to day household chores, and thus females are more prone to experience trauma – a postulation for pyomyositis is that the muscles may be damaged by trauma McGill, (5).

It is unknown if the entity is related to focal myositis described by Hoffmann *et al.*(6), although the entity of focal myositis is often of short duration of onset and with little or no pain Auerbach *et al* (7).

The HIV status of these cases is unknown. It is a known fact that tropical myositis is more prevalent in patients with compromised immune systems, such as in HIV patients.

Radiographically, the next imaging modality, such as a CT, nuclear (Gallium and PET) scan, and MRI, would be ideal to confirm this sonographic finding. In rural African setting, these are unlikely modalities to be considered for the reasons of limited access and the cost involved. Patients are not prone to pay the high cost of these more advance imaging techniques, especially when their symptoms have lasted for a while.

Therefore, in the appropriate settings when there is no pathology observed in the genitourinary system or appendicitis, diagnosis of myofibrositis should be included and treatment should be attempted to see any relief to the symptom. This is considering the availability and relative affordability of the antibiotics.

ACKNOWLEDGEMENT

To Hyeri Song for assistance in analysis of the patient data.

REFERENCES

1. Greene, J. A. The syndrome of psoas myositis and fibrositis; its manifestations and its significance in the differential diagnosis of lower abdominal pain. *Ann Intern. Med.* 1945; **23**: 30-34.
2. Blair, W. M. Psoas myositis or fibrositis in the differential diagnosis of lower abdominal disease. *Am. Surg.* 1956; **22**: 505-511.
3. Reddy, E. A., Shaw, A. V. and Crump, J. A. Community-acquired bloodstream infections in Africa: a systematic review and meta-analysis. *Lancet Infect. Dis.* 2010; **10**: 417-432.
4. Belli, L., Reggiori, A., Cocozza, E. and Riboldi, L. Ultrasound in tropical pyomyositis. *Skeletal Radiol.* 1992; **21**: 107-109.
5. McGill, P. E. Bacterial infections: pyomyositis. *Baillieres Clin. Rheumatol.* 1995; **9**: 193-200.
6. Hoffmann, A., Buitrago Téllez, C., Tolnay, M., *et al.* Focal myositis of the iliopsoas muscle—a benign pseudotumour: ultrasound appearance in correlation with CT and MRI. *Ultraschall Med.* 2006; **27**: 180-184.
7. Auerbach, A., Fanburg-Smith, J. C., Wang, G. and Rushing, E. J. Focal myositis: a clinicopathologic study of 115 cases of an intramuscular mass-like reactive process. *Am. J. Surg. Pathol.* 2009; **33**: 1016-1024.