

East African Medical Journal Vol. 79 No. 1 January 2002

PLUNGING RANULA: A REPORT OF TWO CASES

H.O. Olasoji, FMCDS, Consultant Department of Oral and Maxillofacial Surgery, University of Maiduguri Teaching Hospital, Maiduguri, Nigeria, A.A Tahir, FMCDS, Consultant, Department of Radiology, University of Maiduguri Teaching Hospital, Maiduguri, Nigeria and G.T. Arotiba, FMCDS, Visiting Consultant, Department of Oral Maxillofacial Surgery, University of Maiduguri Teaching Hospital, Maiduguri, Nigeria.

Request for reprints to: Dr. H.O. Olasoji, Department of Oral and Maxillofacial Surgery, University of Maiduguri Teaching Hospital, P.M.B 1414, Maiduguri., Borno State, Nigeria.

PLUNGING RANULA: A REPORT OF TWO CASES

H.O. OLASOJI, A.A TAHIR and G.T. AROTIBA

SUMMARY

Plunging ranula, a rare differential diagnosis of cervicofacial masses is presented in two Nigerian patients. The authors highlight the pathophysiology and treatment methods of this condition. It is suggested that clinicians be aware of the various modes of presentation and natural history of the disease to facilitate prompt diagnosis and appropriate treatment.

INTRODUCTION

The real ranula is a translucent, bluish cystic swelling which is found at the floor of the mouth. There are two commonly held theories suggesting the aetiology of this cyst. Firstly it could result from the retention of mucous caused by partial obstruction, congenital atresia or extraluminal causes(1,2) and secondly from extravasation of saliva by partial disruption or complete obstruction(3,4) of one or more excretory ducts of the sublingual salivary gland. On histological examination, the mucous retention phenomenon variety contains an epithelial lining whereas the mucous extravasation type is lined with connective tissue, commonly referred to as a pseudocyst(5).

Two varieties of this cyst have been described with different clinical behaviour and appearance. The oral ranula which is entirely located within the oral cavity and the plunging or cervical ranula with an associated cervical extension in communication with the oral ranula. The cervical extension of the plunging ranula which is usually located at the submandibular-cervical region can be confused with other cysts of the neck. The differential diagnosis include branchial cyst, thyroglossal duct cyst, lateral dermoid cyst, cystic hygroma, abscess and teratoid cyst.

Plunging ranula occur infrequently and may pose a diagnostic and therapeutic dilemma for those who are not aware of this clinical entity. The purpose of this communication is to present two cases to draw attention to the clinical presentation and the pathogenesis of plunging/ cervical ranula. The various methods of management of this condition are also reviewed.

CASE REPORT

Case 1: A 25-year old female patient was referred to our hospital from a private clinic for evaluation of a recurrent swelling at the left side of the submandibular/cervical region.

She had a surgical excision of the mass eight months before the referral. Examination showed a painless 4 x 4cm cystic swelling on the left side of the submandibular region (Figure 1) which was said to have gradually increased in size one month after the initial excision. Examination of the oral cavity revealed a small bluish cystic swelling at the floor of the left side of the mouth which the patient claimed to be unaware of. Aspiration of the neck swelling yielded a thick straw-coloured, viscous fluid with an amylase content of 81U/l and a protein content of 8.5g/l. A diagnosis of plunging ranula was made and computed tomography of the lesion showed continuity of a single cystic lesion from the sublingual region to the cervical area. The left sublingual gland was removed along with the cyst via an intra-oral approach under general anaesthesia. Light pressure on the neck mass resulted in outpouring of the cystic fluid content into the mouth which was drained away. No attempt was made to excise the neck mass. There has been no recurrence after 18 months of post operative follow up.

Figure 1

Patient in case 1 with submandibular mass caused by plunging ranula

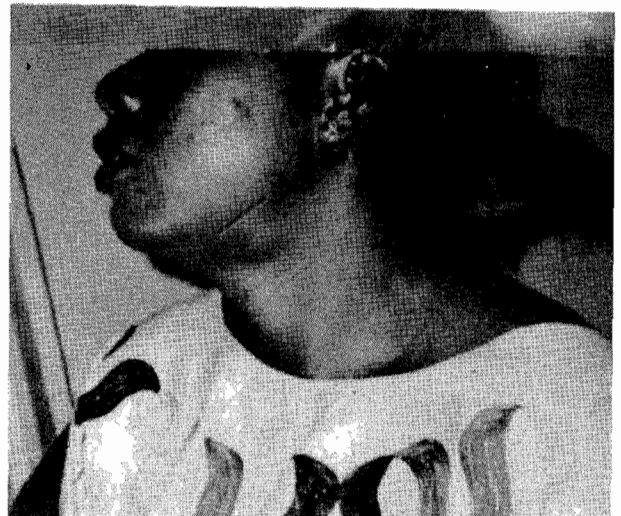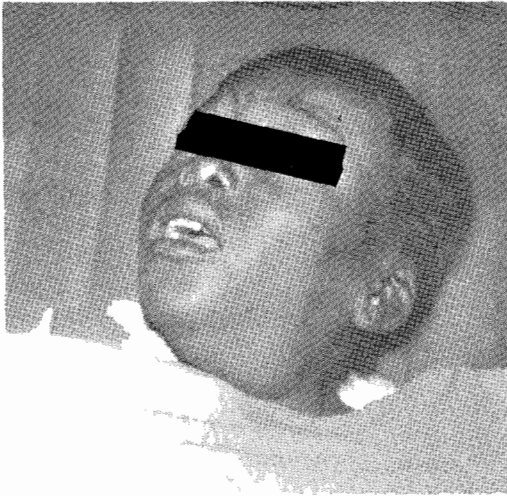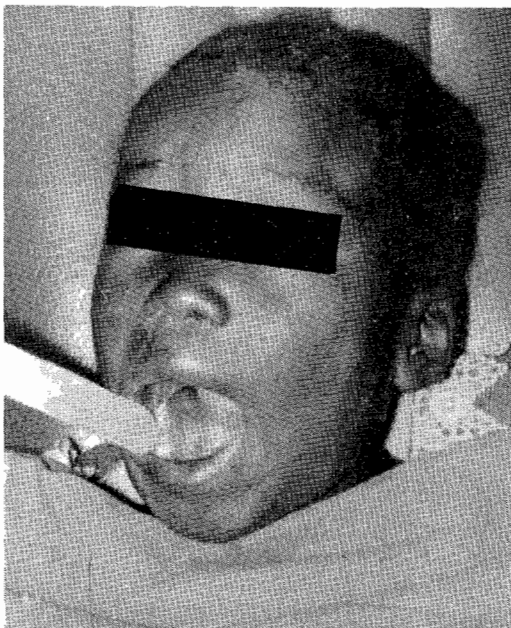


Figure 2

Patient in case 2 with submandibular/cervical mass caused by plunging ranula

**Figure 3**

Sublingual swelling associated with the swelling on the neck in patient in Figure 2



Case 2: The mother of a seven-year old girl notice a slowly increasing right submandibular swelling with cervical extension three weeks prior to the first attendance of the girl in our outpatient clinic (Figure 2) This was preceded with a left sublingual swelling four days before the appearance of the submandibular swelling. The sublingual swelling was bluish in colour elevating the tongue (Figure 3). The regional lymph nodes were not palpable. The amylase level (102U/l) and the total protein content (9g/l) of the aspirated cystic fluid were elevated compared to the serum levels. Contrast enhanced computed tomography (CT) taking at 3 mm intervals in the lower slices showed two separate right sided cystic

masses, a small antero-medial and a larger postero-lateral cystic mass. Slices obtained at higher levels showed evidence of communication between the two cysts resulting in a much larger cystic mass. There was no evidence of enhancement of the cystic masses after contrast injection. The left sublingual gland was removed through an intra-oral approach with evacuation of the submandibular/cervical cyst fluid. One year and four months after removal of the sublingual gland, there has been no evidence of recurrence of the cyst.

DISCUSSION

The need for thorough history, physical examination and investigations in the diagnosis of neck masses cannot be over-emphasised. The fact that they can be due to a wide array of causes may confuse the inexperienced clinician. The extension of the plunging ranula into the cervical region has been confused clinically with other lesion in the neck leading in most cases to inadequate diagnosis and management. The rarity of this condition(6,7), the controversies on its pathogenesis(4) and in some cases the possibility of not examining the oral cavity in the presence of cervical swelling as was observed in case 1 in this report are suggested reasons for this diagnostic dilemma. A plunging ranula should be suspected when a cervical swelling is associated with a ranula in the floor of the mouth or when there is history of earlier treatment of a sublingual cyst swelling without excision of the sublingual gland. However, cases have been reported in which the cervical swelling was the only sign(8). In such cases, diagnostic difficulty may arise, since there is no specific diagnostic test for plunging ranula.

The observed high protein and salivary amylase level in the cystic fluid of the two patients in this report when compared with serum amylase and protein level confirms the findings of previous studies(4,6), which also supported the view that the sublingual gland is the source of secretions in plunging ranula. Since sublingual sialography is often not possible in humans, this cannot be advised routinely for clinical diagnosis. However, using water soluble contrast medium Roediger *et al*(4) showed the interrelationship between the cervical cyst and the sublingual gland or oral ranula. As observed in these two cases, contrast enhance computed tomograph seems to show clearly the interrelation between the sublingual ranula and the cervical extension in patient with plunging ranula. Routine use of this investigation procedure is recommended in suspected cases of plunging ranula.

The pathogenesis and treatment of plunging ranula, in contradistinction to those of oral ranula continues to be subject of conflicting opinion. Patton(9) postulate that aberrant duct from the deep lobe of the sublingual gland often opens into the submandibular duct This abnormal opening may cause stasis of saliva flow in the duct leading to extravasation of saliva into the neck. Several studies(10,11,12) have also showed the presence of anatomical opening in the mylohyoid muscle for the passage of branches of the sublingual artery and vein, submental artery and lymph vessels. Sublingual gland has

been reported to herniate through these opening in 10 - 48% of cases(12). Secretions from this herniated part of salivary gland may encourage cervical mucous extravasations(6). Moss and Hendricks(11) reported the presence of ectopic sublingual salivary gland below the mylohyoid muscle. Visscher *et al*(6) opined that mucous secretion from such ectopic gland may drain directly into the neck tissues.

The theory that plunging ranula are exclusively formed as a result of mucous extravasations from the sublingual salivary gland is widely accepted(4,8). The excision of the sublingual gland and the evacuation of the cyst contents in the neck via an intra-oral approach without excision of the cervical cyst in the two patients reported in this study led to the disappearance of the oral ranula and its cervical extension. This treatment method agreed with the findings in some previous report(6,8). Visscher *et al*(6) emphasised that the aim of treatment of plunging ranula should be towards the secretory tissue from which the ranula originate. They pointed that the cervical ramification is expected to resolve spontaneously once the gland is removed. A review of the literature showed that other forms of treatment method for plunging ranula have been reported. Excision of the cervical extension through an external approach without removal of the sublingual gland was advocated by several authors(13-15). In almost all patients reportedly treated with this method, there was history of multiple recurrence. Other studies(16-18) reported a high success rate of cure when the cervical extension of plunging ranula was excised along with the submandibular and sublingual glands through an incision on the neck. This seems an unnecessarily extensive surgical procedure not based on the pathogenesis of plunging ranula.

Almost all authors agreed that cystic fluid in oral ranula and its cervical extension are secretions of the sublingual gland. Treatment methods based on the understanding of the pathogenesis of this condition will almost in all cases result in better prognoses. The excision of the ipsilateral sublingual salivary gland and intra-oral evacuation of the pseudocyst of the neck without the surgical excision of the cervical component led to successful

outcome without recurrence in this report. The need to recognise plunging ranula as a differential diagnosis of neck masses cannot be overemphasized.

ACKNOWLEDGMENTS

We thank Mr Andy Osakue who produced the photographs.

REFERENCES

- Harrison J.D. and Garrett J.R. Mucocele formation in cats by glandular duct ligation. *Arch. Oral Biol.* 1972; **7**:1403 -1414.
- Shear M. Cysts of the oral regions Wright and Sons. Bristol: 1976, p 145.
- Bhaskur S.N., Bolder T.E. and Weinman. The pathogenesis of mucocele. *J. Dent Res* 1956; **35**:874.
- Roediger W.A.E., Lloyd P. and Lawson H.H. Mucous extravasation theory as a cause of plunging ranula. *Brit. J. Surg.* 1973; **60**:720 - 722.
- Quick C.A. and Lowell S.H. Ranula and the sublingual salivary gland. *Arch. Otolaryngol.* 1977; **103**:397 - 400.
- Visscher G.A.M., Vindel Wal G.H. and Vogel L. The Plunging Ranula. Pathogenesis and Management. *J. Cranio- Max-fac Surg* 1989; **17**:182 -185.
- Catone G., Merrill R. and Henney F. Sublingual gland mucus - escape phenomenon - treatment by excision of sublingual gland. *J. Oral. Surg.* 1969; **27**:774.
- Roediger W.E.W. and Kay S. Pathogenesis and treatment of Plunging Ranula. *Surg. Gynec. Obstet.* 1977; **144**:862 - 864.
- Patton D.W. Recurrent calculus formation following removal of the submandibular salivary gland. *Brit. J. Oral Maxillofac. Surg.* 1987; **25**:15 - 2.
- Gaughran G.R.L. Mylohyoid boutoniere and Sublingual bouton. *J. Anat.* 1963; **97**:565 - 568.
- Moss - Salentju L.M., Hendricks - Klyvert L.M. A bilateral, superficial location of human sublingual gland: report of a case. *J. Maxillofac. Surg.* 1987; **45**:986.
- Engel J.D., Harm S.D. and Cohen D.M. Mylohyoid herniation: gross and histologic evaluation with clinical correlation. *Oral. surg.* 1987; **63**:55 - 59.
- Bronstein S.L. and Clark M.S. Sublingual salivary fistula and mucocele. *Oral Surg.* 1984; **57**:357 - 361.
- McClatchery K.D., Appelblatt N.H. and Zarbo R.J. *et al.* 1984; **57**:408 - 412.
- Zafarulla M.Y.M. Cervical mucocele (Plunging ranula); an unusual case of mucous extravasation cyst. *Oral Surg.* 1986; **62**:63 - 66.
- Mair I.W.S., Schewitsch I. and Svendson E. *et al.* Cervical ranula. *J. Laryngol. Otol.* 1979; **93**:623 - 628.
- Skouteris C.A. and Sotereanos G.C. Plunging ranula: report of a case. *J. Oral Maxillofac. Surg.* 1987; **45**:1085 - 1072.
- Parekh D.M., Stewart C. and Joseph H. *et al.* Plunging ranula: a report of three cases and a review of the literature. *Brit. J. Surg.* 1987; **74**:307 - 308.