

East African Medical Journal Vol. 79 No. 11 November 2002.

NEUROFIBROMATOSIS TYPE 1: REPORT OF TWO CONTRASTING CASES

N. Sheikh, MBChB, Senior House Officer and S.O. McLigeyo, MBChB, MMed, Associate Professor, Department of Medicine, College of Health Sciences, University of Nairobi, P.O. Box 19676, Nairobi, Kenya.

Request for reprints to: Prof. S.O. McLigeyo, Department of Medicine, College of Health Sciences, University of Nairobi, P.O. Box 19676, Nairobi, Kenya.

NEUROFIBROMATOSIS TYPE 1: REPORT OF TWO CONTRASTING CASES

N. SHEIKH and S.O. MCLIGEYO

SUMMARY

We present two cases of neurofibromatosis type 1(NF-1), one a 35 year old male who first recognised his problem at the age of fifteen years and at the time of assessment, satisfied the National Institute of Health (NIH) diagnostic criteria for NF-1 and had a nodular plexiform neurofibroma involving the left fifth dorsal nerve root and a diffuse plexiform neurofibroma involving the left lower limb. The second patient, a 45 year old female recognised her problem at the age of 39 years, did not quite satisfy the NIH diagnostic criteria for NF 1 and had diffuse plexiform neurofibroma involving both lower limbs and buttocks almost symmetrically, a finding which has not previously been described to the best of our knowledge. The scarcity of management options are briefly outlined.

INTRODUCTION

Eight subtypes of neurofibromatosis are currently recognised, of which NF-1 (classic or Von Recklinghausen is or peripheral NF) is by far the commonest(1). Neurofibromatosis type 1 is a familial autosomal dominant disorder that primarily affects cell growth of neural tissues. It affects approximately one in 4000 persons. The genetic disorder lies on chromosome 17q11.2. In 1990, the NF-1 gene was cloned and its protein product neurofibromin was identified. There was a 50% frequency of de-novo mutation, with a mutation rate of 1 in 10,000(2). NF-1 is a distinct entity and does not evolve into other forms of neurofibromatosis.

NF-1 is a progressive genetic disorder with diverse cutaneous, neurologic, skeletal, and neoplastic manifestations. The disorder is characterised by cafe-au-lait macules, intertriginous freckles, neurofibromas, Lisch nodules, optic gliomas, bony dysplasias, and learning disabilities. Neurofibromas are tumours of nerve and fibrous tissue that grow in and along nerves and nerve sheath. The number, location and size of tumours vary greatly from individual to individual. Non-cutaneous tumours of nerve structures may develop and may interfere with function. Dermal neurofibromas may occasionally become malignant. There is an increased risk of other tumours and malignancies associated with NF-1, including gliomas, neurofibrosarcomas, leukaemia, and pheochromocytomas. Numerous benign cutaneous or subcutaneous neurofibromas usually are present in adults with

NF-1. Plexiform neurofibromas are less common but can cause disfigurement and may compromise function or even jeopardise life.

The diagnostic criteria for NF-1 developed by an NIH Consensus Conference in 1987(3) are generally accepted, although they are often inadequate for establishing the presence of NF-1 in small children without a family history of the disease. The NIH diagnostic criteria for NF-1 are met in an individual who has two or more of the following features:

- Six or more cafe-au-lait macules over 5mm in greatest diameter in prepubertal individuals and over 15mm in greatest diameter in postpubertal individuals.
- Two or more neurofibromas of any type or one plexiform neurofibroma. Four types of neurofibromas are currently recognised(4) viz:- cutaneous neurofibromas, subcutaneous neurofibromas, nodular plexiform neurofibromas and diffuse plexiform neurofibromas.
- Freckling in the axillary or inguinal regions.
- Optic glioma.
- Two or more Lisch nodules (iris hamartomas).
- A distinctive osseous lesion such as sphenoid dysplasia or thinning of long bone cortex with or without pseudoarthrosis.
- A first-degree relative (parent, sibling or offspring) with NF-1 by the above criteria.

We report on two contrasting cases of neurofibromatosis, one of which has not been previously described, to the best of our knowledge.

CASE REPORTS

Case 1: N.K., a 35 year old male, presented with an enlarged left lower limb which had been present since the age of 15 years. The enlargement had been progressively increasing in size and over the last six months he had noted ulcerations on the feet and toes which were not-healing, despite treatment at several peripheral health units. In addition, he complained of multiple discolourations on the trunk and a swelling on the lateral aspect of the chest on the left. He was unable to walk due to the size of the left lower limb and the ulcerations. He gave no history of similar illness in the immediate family members.

On examination, he was in a fair general condition, afebrile and not pale. He had multiple café au lait spots varying in size from 0.5cm x 0.7cm to 10cm x 12cm on the anterior and posterior aspects of the trunk. He had freckles in both axillae. The left lower limb (Figure 1) was grossly enlarged as compared to the right and appeared segmented. He had septic ulcerations on the left sole and beneath the heads of the left second and third metatarsal bones. On the lateral aspect of the left side of the chest, just below the nipple, there was a subcutaneous swelling measuring 12cm x 6cm, soft, non-tender and attached to the skin (Figure 1).

He had a pulse of 80/min, regular and of a normal volume. The blood pressure was 130/85 mmHg. The rest of the cardiovascular examination was unrevealing. Ophthalmological review revealed no significant abnormalities in the eyes. Abdominal, central nervous system and respiratory system examination were normal.

The chest X-ray was normal as was the abdominal ultrasonography and CT scan of the abdomen. X-rays of the left tibia and fibula (Figure 2) showed increased bone density, more so the cortex, in the upper two thirds and rarification in the lower third.

There was medial bowing of both the left tibia and fibula in the mid-zone. These findings taken together, were reported as being in keeping with fibrous dysplasia. Additional investigations included a full blood count, urea/ creatinine/ electrolytes, liver enzymes and serum proteins, 24-hour urinary VMA/metanephrines/normetanephrines and a blood sugar, all of which were unrevealing. He was managed conservatively.

Figure 1

- (a) Massive enlargement of the left lower limb with segmentation of the leg (Diffuse plexiform neurofibroma);
(b) Nodular plexiform neurofibroma

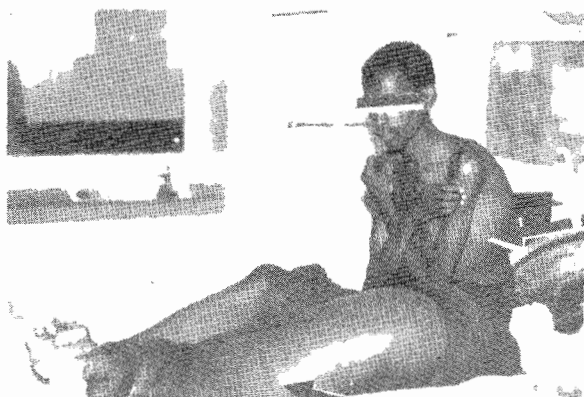

Figure 2

X-ray of the left tibia and fibula showing increased bone density in the upper third and rarification in the lower third



Case 2: A.N.N., a 45 year old female, first presented to the Kenyatta National Hospital in July 2001. She presented with a 6 year history of lower body swelling. The swelling initially involved the feet and the ankle joints, but later progressed to involve the knees, thighs and hips. There would be periods when the swelling would decrease slightly. There was associated "burning" pain at the waist, which radiated down the legs. Seven months prior to admission she developed a "blistering rash" over the affected part, which healed well. This was followed by the development of nodules over the area. There was accentuation of temperature sense in both lower limbs. There was no history of local injury, local pain or local warmth preceding the problem. There was also no history of change in urine output, urine colour or frequency. Enquiry was negative for orthopnoea, dyspnoea, easy fatigability, flushing and abnormal sweating. Sphincter function and sensation remained normal. Vision was reported to be normal, as were bowel habits.

She was functionally impaired, could not stand, walk, or move her lower part of the body without assistance. She was able to use her upper body and could feed herself. She had been bed-bound for six months prior to presentation.

She had had four term pregnancies, the outcome being three still-births and one living child with Erb's palsy due to a difficult delivery. She reported irregular menses at the time, but was not using any contraceptives. Her social history was unremarkable and there was no family history of similar illnesses or of any other chronic illness.

In her past medical history, of significance was an operation to excise a breast lesion, which was found to be benign. On examination, she was a middle aged female in good general condition, but looked gigantic. Findings of significance included a photosensitive malar dermatitis (6 years, duration), two large coffee coloured skin lesions, one near the umbilicus (8cm across) (Figure 3) and the other in the right gluteal region (6cm across).

She was mildly pale. Her blood pressure was 140/90mm Hg and weight 160kgs. On local examination of her waist and lower body which was noted to be grossly enlarged (Figure 4), it was noted that there was marked dimpling of skin, resembling peau d'orange appearance. The legs appeared segmented. Both legs and feet additionally had large sessile

fleshy nodules. There was no tenderness or warmth over the areas. Sensation was normal and capillary refill time was normal. On further examination of the musculo-skeletal system, a venous hum was auscultated in the coccygeal region. Examination of the other systems was unrevealing.

Figure 3

Café-au-lait spot next to the umbilicus

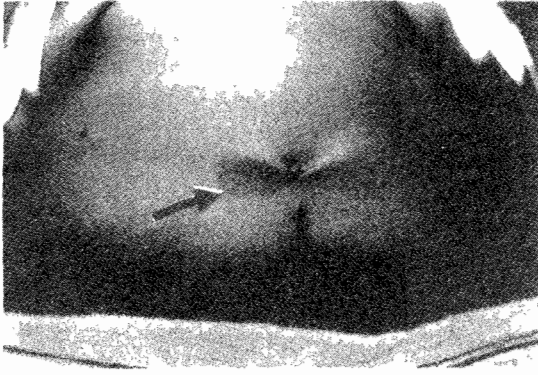
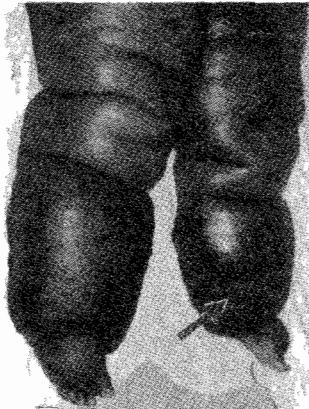


Figure 4

Symmetrically large, segmented lower limbs with sessile neurofibromas



The investigations done included a full haemogram, urea/creatinine/electrolytes, urinalysis, blood sugar, lipid profile, coagulation profile, 24 hour urine for VMA/metanephrines/catecholamines, growth hormone assay, HIV/HbsAg, ELISA and a chest X-ray, all of which were unrevealing. Echocardiography showed a dilated inferior vena cava (3 cm), normal chambers and flows. Abdominal and pelvic ultrasound showed nothing significant except for a mild hepatomegaly. X-rays of both legs showed an increase in soft tissue mass with no bone or joint lesion. CT Scans and MRI of the head, trunk and legs were not possible because the patient could not fit into either machine. The management was conservative with counseling playing a greater role.

DISCUSSION

Two contrasting cases of NF-1. The first case clearly satisfied the diagnostic criteria for NF-1 developed by NIH Consensus Conference in 1987(3), while the second did not. The NIH diagnostic criteria

are thought to be very reliable in distinguishing adults with and without NF-1 on the basis of routine clinical and ophthalmological examinations (5,6). In the first case, there were cutaneous lesions, including numerous large (greater than 1.5cm diameter) café-au-lait spots, axillary freckling and multiple nodular fibromas, not to mention the plexiform neurofibroma, involving only the left lower limb. In addition, the patient had bone involvement in the form of fibrous dysplasia involving the left tibia and fibula. In the second case, the two large café-au-lait spots and the symmetrical diffuse plexiform neurofibromas involving the gluteal regions and both lower limbs were not adequate criteria to make a diagnosis of NF-1. It is, however, worth mentioning that because of the large size of our second patient, it was not possible to carry out comprehensive investigations (particularly radiographic). This is relevant considering the fact that NF-1 is a progressive multisystem disorder that has cutaneous, ophthalmic, central nervous system, vascular and osseous manifestations(7), not to mention its strong association with specific malignancies, including myelogenous leukaemia(8), phaeochromocytoma(9), melanomas and neuroblastomas(10). However, in situations where the diagnosis of NF-1 with plexiform neurofibroma is not clear, the differential diagnoses will include lymphoedema, arterio-venous malformation at the bifurcation of lower limb vessels, proteus syndrome and multiple lipomatosis.

This autosomal dominant disease, whose gene has been localised on chromosome 17q 11.2, affects between 1/2000 and 1/4500 people(2). This makes it not a rare condition, an observation which has been made by our own plastic surgeons (Audi and Aref, personal communication). However, extensive, diffuse plexiform neurofibromas are much rarer and to the best of our knowledge, our second patient is the first report of plexiform neurofibromatosis involving both lower limbs in almost symmetrical fashion. We hypothesise that in this patient, the disease involved the lumbar plexus, spreading to affect the sciatic nerves in both lower limbs. Half of all NF-1 cases are familial, and half are caused by new mutations(2,11). It is, thus, not surprising that we did not get any history of a similar illness in the families of our two patients.

The treatment of such patients remains an enigma, and in our patients was conservative, although the mainstay of therapy for neurofibromas is surgery. Medical therapies which are undergoing trial include ketotifen, interferon alpha 2a, 13-cisretinoic acid (isotretinoin), inhibitors of angiogenesis, farnesyl protein transferase inhibitors in and anti-sense oligonucleotides(4).

In conclusion, we report on two cases of NF-1 the management of which were challenging with one presenting in a way that seems not to have been described before.

REFERENCES

1. Huson, S.M. and Hughes, R.A.C. *The neurofibromatosis*. London, UK: Chapman and Hall. 1994; 13-29.
2. Littler, M. and Morton, N.E. Segregation analysis of peripheral neurofibromatosis (NF 1). *J. Med. Genet.* 1990; **27**:307-310.
3. Stumpf, D.A., Alksne, J.F., Annegers, J.F. *et al.* Neurofibromatosis conference statement. *Arch. Neurol.* 1988; **45**:575-578.
4. Kolf, B.R., Huson, S., Needle, M. *et al.* Report of the Working Group on Neurofibromatosis. File://A:\Task % 20 Force.htm.
5. Gutmann, D.H., Alyswoth, A., Carey, J.C. *et al.* The diagnostic evaluation and multidisciplinary management of neurofibromatosis 1 and neurofibromatosis 2. *J. Amer. Med. Ass.* 1997; **278**:51-57.
6. Wolenstein, P., Freche, B., Zeller, J. and Revuz, J. Usefulness of screening investigations on neurofibromatosis type 1. *Arch. Dermatol.* 1996; **132**:1333-1336.
7. Roos, K.L. and Muckway, M. Neurofibromatosis. *Dermatol. Clin.* 1995;**13**:105-111.
8. Shannon, K.M., O'Connell, P., Martin, G.A., Paderanga, D., Olson, K. and Dinndorf, P. Loss of the normal NF-1 allele from the bone marrow of children with type 1 neurofibromatosis and malignant myeloid disorders. *N. Eng. J. Med.* 1994; **330**:597-601.
9. Gutmann, D.H., Cole, J.L., Stone, W.J., Ponder, B.S. and Collins, F.S. Loss of neurofibromin in adrenal gland tumours from patients with neurofibromatosis type 1. *Genes, Chromosomes and Cancer.* 1994; **10**:55-58.
10. Andersen, L.B., Fountain, J.W. and Gutmann, D.H. *et al.* Mutations in the neurofibromatosis 1 gene in sporadic malignant melanoma cell lines. *Nature Genetics.* 1993; **3**:118-121.
11. Clementi, M., Barbujani, G., Turolla, L. and Tencomi, R. Neurofibromatosis-1: a maximum likelihood estimation of mutation rate. *Hum Genet* 1990; **84**:116-118.

EAMJ INTERNET ADDRESS

The East African Medical Journal is now available online as well as in print. Subscribers and readers interested in viewing the Internet version may access it using the following address: <http://www.bioline.org.br>

The Online version is distributed by the non-profit service; Bioline Publications, a South/North partnership whose aim is to facilitate global access to bioscience and medical research publications, with emphasis on journals published in the developing world.

Subscription to the online version may be made by completing the Registration form available from the Bioline home page (<http://www.bioline.org.br>). Readers may take out an annual subscription or purchase single documents. Abstracts are available without registration and free of charge.