

East African Medical Journal Vol. 80 No. 11 November 2003

SMALL INTESTINAL OBSTRUCTION DUE TO BILHARZIOMA: CASE REPORT

A. E. Ali, MBBS, MD, FRCS (Glasg), Assistant Professor, Department of Surgery, Faculty of Medicine, University of Khartoum and Department of Paediatric Surgery, Soba University Hospital, B. M. Ismail, MBBS, MD, Assistant Professor and F. R. Khogali, MBBS, MD, Assistant Professor, Department of Pathology, Faculty of Medicine, University of Khartoum and Soba University Hospital, P.O. Box 8081, Khartoum, Sudan

Request for reprints to: Mr A. E. Ali, Department of Paediatric Surgery, Royal Manchester Children's Hospital, Hospital Road, Pendlebury, Manchester M27 1HA, UK

SMALL INTESTINAL OBSTRUCTION DUE TO BILHARZIOMA: CASE REPORT

A. E. ALI, B. M. ISMAIL and F. R. KHOGALI

SUMMARY

Schistosomiasis in endemic areas affects all age groups and present with various clinical manifestations. Small intestinal obstruction as a complication of Schistosomiasis was not described in the literature. This is a report of a 10 year old child from an endemic area with an unusual presentation of subacute small intestinal obstruction. Description of the pathological changes in the intestines following infestation with Schistosomiasis and brief presentation of the control modality in this endemic area are given.

CASE REPORT

A 10 year old girl from El Galgala village, close to the Blue Nile in El Gezira area, presented with recurrent episodes of colicky abdominal pain of alarming severity for one month. The attacks were brief and usually subsided spontaneously. She had bouts of bilious vomiting but there was no constipation. She had melaena for three successive days following the first attack. There was no haematemesis, bleeding tendency or use of NSAID. The child looked unwell. She weighed 24 Kg and she was pale but not jaundiced or febrile. Abdominal examination revealed a distended, soft abdomen with visible periumbilical peristalsis during the attacks of colics and a palpable spleen 7 cm below the costal margin. An ill-defined central abdominal mass was palpable. There was no ascites and bowel sounds were frequent with a high pitch. Rectal examination showed no abnormality and there was no other significant systemic finding. The blood count showed an Hb% of 10.4 gm%, TWBC count of 6500/cmm with significant eosinophilia of 18%. Stool examination revealed ova of Schistosoma mansoni. Abdominal ultrasound scan showed hepatic periportal fibrosis and a dilated portal vein (13 mm), however, no bowel mass could be identified. No abnormality was detected on upper GIT endoscopy. Sigmoid polyps were found on sigmoidoscopy. A biopsy showed inflammatory polyps. In view of the frequent bouts of subacute intestinal obstruction and the presence of colonic polyps, a provisional diagnosis of recurrent intussusception was made. Laparotomy was carried out during one of the attacks. A 15 cm long, firm mass of the jejunal wall was found and there was evidence of partial obstruction with proximal bowel dilatation. Mesentery of the affected segment was thickened and hyperaemic. Resection and primary anastomosis was performed. Histopathology revealed several Bilharzial granulomata.

Figure 1

Microscopic appearance of the small bowel wall showing Bilharzial granulomata with dense fibrous tissue and mononuclear inflammatory cells

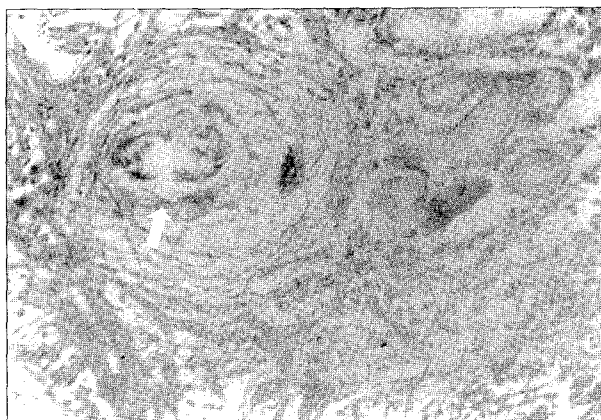
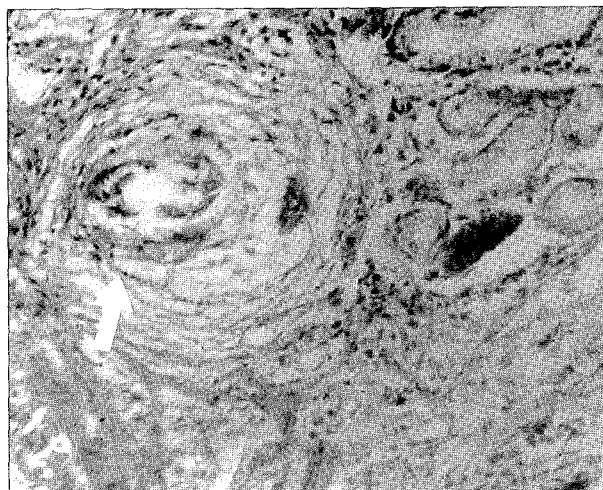


Figure 2

Higher magnification showing a granuloma surrounding Bilharzial egg-shell



The intestinal wall was markedly thickened. Microscopically, there were multiple lesions showing Bilharzial ova surrounded by dense fibrous tissue and mononuclear inflammatory cells (Figure 1). The patient improved dramatically following surgery and administration of the Anti-Bilharzial agent Praziquantel 40 mg/kg as a single dose. Body weight was 29.5 kg on discharge and 31 kg on follow up to four weeks from the date of surgery and she remained well three years afterwards.

DISCUSSION

Schistosomiasis remains an important health problem. It is endemic in 74 countries, affecting a population of over 200 million(1). All age groups may be affected but young adults and children contract the disease more frequently(2). All three Schistosome species are known to affect the bowel. *Schistosoma mansoni* and *Schistosoma japonicum* eggs affect the whole bowel from duodenum to rectum(3). The acute inflammatory lesions around the eggs in the gut wall and the mucosa cause bleeding and diarrhoea. Macroscopically they appear as small elevated granular swellings with petichial haemorrhages. The distal parts of the colon are usually more seriously affected(4). When it is involved with infection, pathology in the small bowel is not as severe as in the large bowel even though in late stage infection(2). Heavy masses of parasitic eggs in the submucosa associated with hyperplasia lead to polyp formation in the large bowel(3). Though usually inflammatory in nature, colonic polyps are directly related to the intensity of infection. The concentration of the eggs within the polyps is higher than in other sites in the intestine(2) and, therefore, polyp biopsy could be diagnostic. Colonic polyps may be asymptomatic. In one study, they were found in 9.1% of autopsies of asymptomatic infected children(5). However, polyps are frequently responsible for life threatening dysentery with loss of fluids, proteins and blood from the ulcerated surfaces (6). The polyps can obstruct the lumen and can form the apex of an intussusception(3). Chronic, dense fibrosis may produce a significant reduction in the circumference of intestinal lumen(4). Bilharzioma implies a localized pseudo-tumour of Schistosoma ova or egg shell surrounded by extensive fibrosis and inflammatory cells(2,4). Predominantly masses occur in omentum, mesenteric lymph nodes, paracaecal region and, infrequently, the bowel wall(2). Bilharziomas, even in endemic areas, are quite uncommon lesions in adults. They have been

reported to cause large intestinal obstruction simulating a colonic tumour in a child(4); however, so far they have not been reported to cause small intestinal obstruction.

Specific therapy can result in the reversal of infection associated morbidity. Although some granulomata from the early stages of infection may resolve entirely as the egg dies, others may progress to irreversible lesions caused by the extensive fibrosis of the granulomata and the surrounding tissues. This fibrosis is responsible for the severe late sequelae of infection and it responds less well to specific Schistosomal treatment(7). Therefore, it is important to treat established infections in young children even if they are asymptomatic.

Since the introduction of Praziquantel, the treatment policy of positive stool cultures in endemic area is oral administration of a single dose of Praziquantel. It is highly effective against Schistosoma species. Complete cure is achieved in up to 85% of treated individuals. Control programmes use either mass chemotherapy, or selective chemotherapy(7). In the endemic area in Sudan, mass chemotherapy remains the most effective way of controlling the disease. More than one round of chemotherapy may be required(8). Gezira in Sudan (the irrigated area between the White and the Blue Niles) is a highly endemic place; the prevalence is about 70% (9). While some patients, perhaps the majority, with intestinal Schistosomiasis are asymptomatic, some present with different clinical manifestations. The most serious complication known is peri-portal fibrosis and associated portal hypertension and oesophageal varices(8). Despite the high prevalence of intestinal Schistosomiasis in endemic areas with the wide range of variation in clinical and pathological manifestations, this child presented in an unusual manner. Schistosomiasis was not initially suspected as an underlying cause of small intestinal obstruction because of the rarity of involvement of the small intestines, even though in late stage of the disease. The ultrasound scan did not show a mass in the bowel wall. It was therefore not reviewed retrospectively to identify positive Bilharzioma. Such a frank lesion of Bilharzioma with signs of small intestinal obstruction has not been reported in the literature. In conclusion, this case raises the awareness that Bilharzioma should be included in the differential diagnosis of intestinal obstruction in endemic areas. Anti-Schistosomal treatment should be given to all individuals with manifestations of chronic Schistosomiasis who have not previously received specific chemotherapy.

ACKNOWLEDGEMENTS

To Prof. A.M. EL Hassan, Institute of Tropical Diseases, University of Khartoum for reviewing the manuscript and Miss Aziza Mustafa, Department of Paediatric surgery and administration of SUH for providing approval for its submission for publication.

REFERENCES

1. Cotran, R.S., Kumar, V. and Robbins, S.L. Robbins Pathologic Basis of Diseases. 5th edition. PP 371-372. *W.B. Saunders Company*. Philadelphia. 1994.
2. Cook, G.C. Mansons Tropical Diseases. Twentieth edition. *W.B. Saunders Ltd*. London. PP 1413-1436. 1996.
3. Mac Sween, R.M.N. and Whaley, K. Diseases Caused by Parasitic Protozoa and Metazoa, *Muir's Textbook of Pathology. Thirteenth edition*. P 1168. *ELBS*. 1992.
4. Farhan, N.E., A/Raheem, M., Badawy, A., Zuberi, S.R. and Matbouli, S.A. Recto sigmoid Bilharzioma causing intestinal obstruction. *J. Pediatr. Surg.* 1997; **32**:631-633.
5. Cheever, A.W. and Andrade, Z.A. Pathological lesions associated with schistosoma mansoni infection in man. *Trans. Royal Soc. Trop. Med. and Hyg.* 1967; **61**:626.
6. Lehman, J.S., Farid, Z. and Bassily, S. Intestinal protein loss in schistosomal polyposis of colon. *Gastroenterology*. 1970; **59**:433.
7. Weatherall, D.J., Ledingham, J.G. and Warell, D.A. Oxford Textbook of Medicine. 3rd edition, Vol. 1: 970-981. *Oxford University Press*. 1996.
8. Homeida, M.M., El Toum, I.A., Ali, M.M., *et al*. The effectiveness of annual versus biennial mass chemotherapy in reducing morbidity due to Schistosomiasis: A prospective study in Gezira-Managil, Sudan. *Am. J. Trop. Med. Hyg.* 1996; **54**:140-145.
9. El Hassan, A.M., Stair, A.A. and Ahmed, M.A. The pathology of Schistosomiasis in Sudan. *Trop. Geogr. Med.* 1977; **29**:56.