

East African Medical Journal Vol. 80 No. 6 June 2003

PURULENT PERICARDITIS COMPLICATING SEPTICAEMIA: REPORT OF TWO CASES

A.A. Musa, FWACS, B.A. Salami, FMCS, FWACS and A.O. Tade, FWACS. FRCS Department of Surgery, Ogun State University Teaching Hospital, PMB 2001, Sagamu, Nigeria

Request for reprints to: Dr. A.A. Musa, Department of Surgery, Ogun State University Teaching Hospital, PMB 2001. Sagamu, Nigeria

PURULENT PERICARDITIS COMPLICATING SEPTICAEMIA: REPORT OF TWO CASES

A.A. MUSA, B.A. SALAMI and A.O. TADE

ABSTRACT

Intrapericardial (Pericardial) abscess is quite rare as a complication of sepsis and as a cardiac complication of typhoid septicaemia. It is rapidly fatal if untreated. We report two cases of a schoolboy eight years old with septicaemia from pyomyositis of the right thigh and another of nine and a half years with typhoid perforation and typhoid septicaemia that developed pericardial abscesses. In well-developed centres, computerised tomography, ultrasonography and other radiological investigations are employed for both diagnosis and therapy. We emphasise that these can be accomplished by good clinical examination, radiography of chest and the use of 18-G intra-venous cannula for percutaneous pericardiocentesis without aggressive surgical intervention.

INTRODUCTION

Intrapericardial abscess (purulent pericarditis) is quite rare(1) but septic shock is quite common with approximately 200,000 cases recognised annually(2). Unfortunately, purulent pericarditis is a rare disorder in which fever and hypotension are common (as in septic shock). Classic signs and symptoms, such as chest pain, pericardial friction rub, elevation of jugular venous pressure are seen in only 50% of cases(1,2).

Again, the diagnostic pitfall of purulent pericarditis presenting as an acute abdomen in children should be noted(3). Though, we emphasise on the use of chest X-ray (CXR) in diagnosis, it should be noted that children with purulent pericarditis may have a normal size on radiograph(3).

CASE REPORT

Case 1: J. M., was an 8-year old student who sustained a blunt injury to the right thigh while playing football with his colleagues on the school playing ground. He could not walk properly afterwards and started having pains in the right thigh. His parents took him to a traditional bone healer where he spent four weeks without any improvement. He was subsequently seen at Muslim Hospital, Saki Oyo State, Nigeria and findings on examination were a young chronically ill looking, wasted boy, pale (PCV 18%) and septicaemic. The right thigh was swollen, shiny and tender with a rag tied round (from the herbalist). He could not walk.

A diagnostic needle aspiration was done which yielded 10mls of pus. A diagnosis of right thigh pyomyositis with septicaemia was made and the aspirate was sent for microscopy, culture and sensitivity, which grew *staphylococcus aureus*. Full blood count and X-ray of right thigh were done. He was rehydrated, had 500mls of whole blood and commenced on broad-spectrum antimicrobial-intravenous cefuroxime 500mg

eight hourly and I.V metronidazole 500mg eight hourly. He subsequently had incision and drainage after full resuscitation. About 1,500mls of pus was drained from the right thigh.

Figure 1 shows radiological features of chronic osteomyelitis and there is suspicion of a dislocated right hip joint as well. He was subsequently placed on daily dressing with honey and full leg back-slab was applied. He had another 500mls of blood after drainage.

He improved remarkably and was gaining weight. His packed cell volume (PCV) had risen to 30% by the second week of admission. However, on the 18th day of admission, he was noticed to be dyspnoeic, tachypnoeic and the neck veins were engorged and became more prominent. The heart sounds were distant and the pulse barely palpable. There were transmitted sounds in the chest. A tentative diagnosis of septic shock with possible pericardial effusion was made (Metastatic abscess). He had chest X-ray immediately which showed gross cardiomegally (Figure 2).

Figure 1

Right thigh with features of osteomyelitis

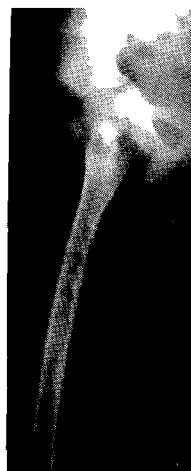
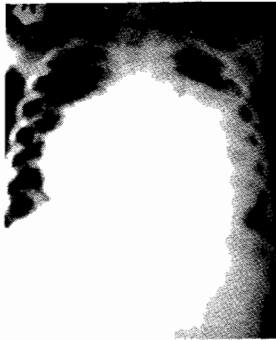

Figure 2

Chest showing enlarged cardiac shadow (due to collection of pus within the pericardial space)



A final diagnosis of pericardial effusion was then made and a diagnostic pericardiocentesis done yielded 5mls of pus. Blood culture done earlier yielded *staphylococcus aureus*, sensitive to gentamicin, cefuroxime, and cefotaxime. This was drained urgently percutaneously by pericardiocentesis using size 18-G intravenous cannula going through the angle of Louis (Figure 3). About 500mls of frank pus was aspirated. The antimicrobials cefuroxime and metronidazole were continued.

Repeat aspirations done on the second and third days yielded only 150mls and 10mls respectively while aspiration on the fourth day yielded nothing. A repeat chest X-ray about three weeks after showed a normal CXR (Figure 4). He had secondary closure of his right thigh wound after five weeks on admission and the wound healed satisfactorily. He could not walk properly initially but had physiotherapy for two weeks and responded well. He was followed up for three months and had since gone back to school.

Figure 3

The chest and the heart with the pericardial space and the angle of Louis

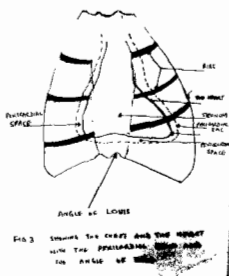
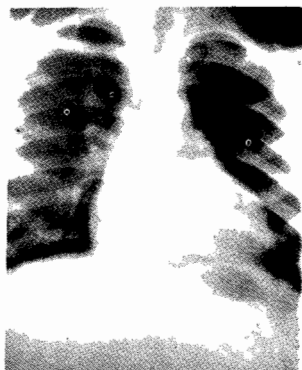

Figure 4

Chest after percutaneous drainage showing normal cardiac size



Case 2: O. S. was a nine and a half year-old boy who was referred from a private clinic to muslim hospital, Saki Oyo State Nigeria on account of fever of two weeks duration and three days history of generalised abdominal pains. According to the referral note, he had had anti-malaria drugs, to no avail and was also given amoxicillin capsules before the generalised abdominal pains started. Findings revealed an acutely ill-looking boy, febrile, pale dehydrated and moribund.

He had features of generalised peritonitis. A clinical diagnosis of typhoid perforation with overwhelming sepsis was made. He was subsequently resuscitated and was transfused with 500mls of blood. He had laparotomy and two perforations about 10cm apart, measuring 0.5cm by 0.5cm were found about 20cm and 30cm respectively from the ileocaecal junction. Closure was done after peritoneal lavage with 2 litres of warm normal saline.

He was commenced on I.V. cefuroxime 500mg 8hourly, chloramphenicol 500mg 6 hourly and 500mg metronidazole 8hourly. He was responding well to treatment until 7th day postoperative when he suddenly became dyspnoeic and tachypnoeic and the pulse was thready. The heart sounds were distant and the neck veins became engorged.

A diagnosis of pericardial tamponade from pericardial effusion as a complication of typhoid septicaemia was made. He had a chest X-ray (Figure 5), which confirmed the diagnosis. An aspirate of the pericardial effusion was sent and yielded *Salmonella typhi*. Earlier blood culture also yielded the same organism.

An urgent percutaneous pericardiocentesis was done through the angle of Louis and about 450mls of pus was aspirated using size 18-G intravenous cannula. The post aspiration status was good and uneventful and the antimicrobials were continued for another one week.

Figure 5

Chest before drainage showing enlarged cardiac shadow (due to collection of purulent material within the pericardial space)

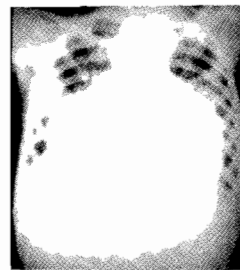
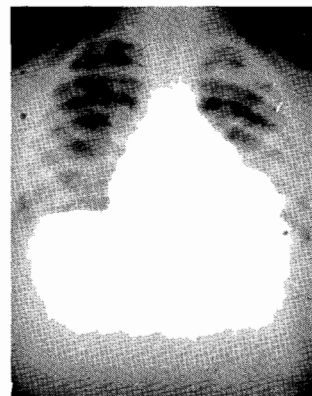
Figure 6

Chest after drainage showing normal cardiac size



Repeat aspirations on the second and third days yielded 80mls and 10mls respectively while the fourth day was just 3mls of very light purulent aspirate. A repeat CXR about four weeks after was normal (Figure 6). He was discharged after spending about four weeks in the hospital and was followed up for two months and had since been doing quite well.

DISCUSSION

Pericardial abscess is a rare complication of sepsis and septic shock(1).The presentations could be many and varied and diagnosis difficult unless there is a high index of suspicion based on clinical signs and symptoms(1-3). The diagnosis is even more difficult in children with presentation varying from acute abdomen, confusion to asystolic cardiopulmonary arrest(1-4).

It is not only common with sepsis or septic shock following staphylococcal infection or *Salmonella enteritidis*(5) but cases have been reported following pneumococcal pneumonia, group A haemolytic streptococcal tonsillitis, non-encapsulated *Haemophilus influenzae*, *Pseudomonas aeruginosa* and even *Streptococcus Milleri* which is a harmless commensal of oral cavity had been implicated. It has also been implicated in patients with oesophago-mediastinal fistula. Cases have also been reported following coronary angioplasty and stenting, cystic fibrosis, patients on long standing corticosteroid therapy and in immunocompromised patients(1,6,7,8-10).

Most of the diagnostic equipments are not readily available but they are very useful in diagnosis e.g. CAT scanning, ultrasounds and echocardiography. Although, the classic signs and symptoms such as pericardial rub, pulses paradoxus, chest pain and elevation of jugular pressure are seen in only 50% of cases, the diagnosis can be easily made as seen in the two cases reported with a high index of suspicion and with a simple investigation like chest X-ray.

Treatment is both surgical and non-surgical. Some of the non-surgical techniques are the use of ultrasound guided percutaneous pericardiocentesis, closed catheter drainage as well as the use of streptokinase(7,8,9,10-13).

The two cases reported here had simple percutaneous pericardiocentesis. The patients were laid supine on bed and under aseptic technique wearing surgical gloves and preparing the skin around the epigastrium with savlon, iodine and spirit. The patients were draped. Then with the size 18-G intravenous troca and cannula directed towards the tip of the left shoulder the pericardial space was entered at the epigastrium (angle of Louis) with the depth of penetration about

3-4cm. The troca and the small 2mls syringe were removed but replaced with a 20mls syringe. Then repeat and regular aspirations were done as a bedside procedure. One of the complications of purulent pericarditis is constrictive pericarditis(12) but this has not been observed in the two cases reported, as ECGs done before discharge were normal. It is part of further studies on these patients. This might be the first time in Africa that pericardial abscess with *Salmonella enteritidis* is reported.

REFERENCES

1. Capov, I., Wechsler, J., Pavlik, M. and Jadlicka, V. Pericardial abscess-a rare complication of sepsis. *Acta Chirurgica Hungarica*. 1999; **38**:19-21.
2. Asura, E.L., Kilgore, W.B. and Strategos, E. Purulent pericarditis misdiagnosed as septic shock. *Southern Med. J*. 1999; **3**:285-288.
3. Donnelly, L.F., Kimball, T. R. and Barr, L.L. Purulent pericarditis presenting as acute abdomen in children: abdomen imaging findings. *Clinical Radiology*. 1999; **54**:691-693.
4. Wass, A.R., Mann, P. and Wilson, J.I. Pneumococcal pericarditis presenting as out of hospital cardiopulmonary arrest. *J. Accident and Emergency Med*. 1997; **14**:261-263.
5. Kuichi, K., Endo T., Nejima, J., et al. Purulent pericarditis with tamponade caused by *Salmonella enteritidis*. *Japanese Circul. J*. 1998; **62**:139-141.
6. Amin, H., Munt, B. and Ignaszewski, A. *Staphylococcus aureus* pericarditis with tamponade complicating coronary angioplasty and stenting. *Canadian J. Cardiol*. 1998; **14**:1148-1150.
7. Baysak, K., Sancak, R., Ozturk, F., Uysal, S. and Gause N. Cardiac involvement due to *Salmonella typhi* infection in children. *Annals of Tropical Paediat*. 1999; **18**:23-25.
8. Altmeier, W.A., Tonelli, M.R. and Aitken, M.L. *Pseudomonas* pericarditis complicating cystic fibrosis. *Paediatric Pulmonology*. 1999; **27**:62-64.
9. Rallidis, L.S., Thomaidis, K.P., Viasseros, I.N., et al. Successful treatment of staphylococcus pericarditis with early catheter drainage and antibiotics. *Acta cardiologica*. 1997; **52**:437-443.
10. Muto, M., Ohtsu, A., Boku, N., Tajiri, H. and Yashida, S. *Streptococcus milleri* infection and pericardial abscess associated with oesophageal carcinoma: report of two cases. *Hepato-Gastroneterology*. 1999; **46**:1782-1784.
11. Defouilby, C., Meyer, G., Slama, M., et al. Intrapericardial fibrinolysis: a useful treatment in the management of purulent pericarditis. *Intensive care Medicine*. 1997; **23**:117-118.
12. Juneja, R., Kothari, S.S. Saxena, R. and Joshi, A. Intrapericardial streptokinase in Pericarditis. *Archive of disease in childhood*. 1999; **80**:275-277.
13. Ligtenberg, J.J., Van der Werf, T.S., Zijlstra, J.G. et al. Non-surgical treatment of purulent pericarditis due to non-encapsulated *Hemophilus influenzae* in an immunocompromised patient. *Netherlands J. Med*. 1999; **5**:151-154.