

East African Medical Journal Vol. 88 No. 9 September 2011

REDUCTION MAMMOPLASTY USING INFERIOR PEDICLE IN HEAVY BREASTS (MACROMASTIA)

S. O. Khainga, MBChB, MMed (Surg) FCS (plast) FCS(CoSECSA), Department of Plastic Surgery, College of Health Sciences, University of Nairobi, P. O. Box 19676-00202, Nairobi, R. W. Wasike, MBChB, MMed (Surg), FRCS (C), Aga Khan University Hospital, P. O. Box 30270-00100, Nairobi and P. K. Biribwa, MBChB, Registrar, Department of Plastic Surgery, College of Health Sciences, University of Nairobi, P. O. Box 19676-00202, Nairobi, Kenya

Request for reprints to: Dr. P. K. Biribwa, Department of Plastic Surgery, College of Health Sciences, University of Nairobi, P. O. Box 19676-00202, Nairobi, Kenya

REDUCTION MAMMOPLASTY USING INFERIOR PEDICLE IN HEAVY BREASTS (MACROMASTIA)

S. O. KHAINGA, R. W. WASIKE and P. K. BIRIBWA

SUMMARY

Symptoms associated with heavy breasts are pain in the upper part of the body; back pains, poor body posture and headache. These patients also have difficulties in finding suitable clothes and experience poor self image and problems such as establishing sexual relationships. Reduction mammoplasty procedure provides weight and volume reduction of the breast as well as enhancement of the aesthetic appearance of the breasts.

In this study, the inferior pedicle technique was used in reduction of thirty five patients over the last four years with macromastia. In all the patients except three, good results were achieved. One patient suffered nipple necrosis of the right breast and the other two had superficial wound infection of T-junction and were appropriately treated. The patient who lost the nipples had nipple reconstruction three months later.

INTRODUCTION

Breast hypertrophy and gigantomastia are conditions poorly understood end product of organ hormone insensitivity, genetic background and overall body weight gain (1).

Reduction mammoplasty represents the interface between reconstructive and aesthetic plastic surgery. The objective of the procedure is reduction in weight, volume and improvement in aesthetic appearance of the breasts (1). Excellent procedures have been described and now the emphasis has shifted to technical refinements for improved safety and more predictable aesthetic results.

Despite well documented clinical symptoms, reduction mammoplasty is still considered more of a cosmetic than a functional operation by general public, many medical professionals and insurance companies (2). Gonzales and co-workers recently presented a new definition for which macromastia was defined as a pain syndrome for at least three locations in the upper part of the body (3).

Indications of breast reduction are both physical and psychological and include; heavy pendulous breasts, neck and back pains, grooves

from the pressure of the brassiere straps, chronic pains in the breasts, maceration and dermatitis in the inframammary area. The psychological reasons are a troublesome focus of attention that result in embarrassment as well as difficulties in establishing a sexual relationship (1,2).

CASE REPORT

This technique has several advantages that include; it is reproducibility, straightforward and easily taught, skin incisions correspond to glandular excision and hence the cutting of tissues and wound closure proceed along the pre-operative planned lines which gives it a great measure of predictability and reliability (1).

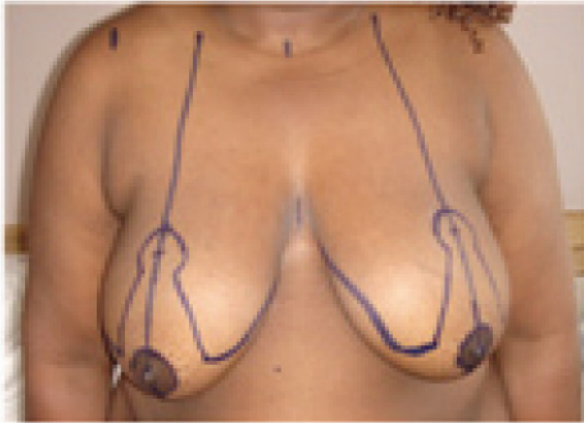Inferior Pedicle technique is the most popular among plastic surgeons (4). With the patient erect, lines are drawn and the breast meridian is established by dropping a line from the mid-clavicle through the nipple and continuing inferiorly across the inframammary line. The new nipple position is marked along this line and the inframammary fold.

Figure 1(a)(b)

The inferior pedicle being advanced into the 'keyhole'

Figure 1a

Markings for inferior pedicle technique



Inferiorly based dermoglandular pedicle is planned with a base of four to nine centimetres at the inframammary line that gradually tapers as it ascends towards the nipple areolar complex. De-epithelialisation is limited to the zone immediately around and inferior to the nipple areolar complex (NAC). Skin and parenchyma resections are performed medial and lateral to the pedicle but also superior to the NAC up to the level of keyhole pattern. The resections are done in a beveling fashion leaving a carpet of breast tissue of the muscle fascia especially laterally so as to preserve sensation to the nipple (5). Immediately superior to the one centimetres de-epithelialised cuff above the NAC, the pedicle is terminated by incision down to the muscle fascia taking care not to undercut the inferior vascular base. After completion of the breast resection, the nipple areola is brought to the desired position in the keyhole pattern and the medial and lateral flaps are brought together over the pedicle and closure is begun working from the extremities towards the centre.

Figure 1b

Advancement of the dissected inferior pedicle

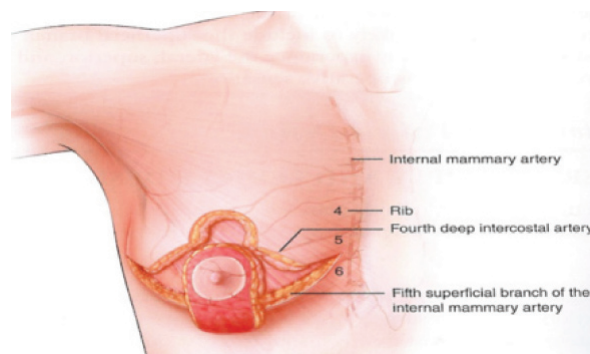
**RESULTS**

Table indicating the age, reasons, investigations, number of patients, excised breast tissue weights and outcome of inferior pedicle reduction mammoplasty

1. Age(Yrs)	No. of Pts	Percentage (%)
15 -20	2	5.7
21 - 30	15	42.9
31 - 40	10	28.5
41 - 50	7	20
>51	1	20
Total	35	2.8
2. Reasons For Surgery		
Physical	5	14.3
Psychological	0	0
Both	30	
3. Relevant Investigations		
U/S	17	48.5
Mammography	13	37.1
Fire needle aspiration cytology	0	0
Biopsy	0	0
None	5	14.3

4. Weight of Breast Tissue Excised wt (gms)		
<400gms	0	0
500 - 100gm	5	14.3
1001 - 1500	8	22.9
1501 - 2000	12	34.2
> 2001	10	28.6
Total	35	
5. Length of Hospital Stay (days)		
1 - 2	4	11.4
3 - 4	20	57.1
5 - 6	10	28.6
> 7	1	2.9
Total	35	2.9
6. Outcome		
Satisfied	34	97.1
Not Satisfied	1	2.9
Total	35	
7. Complications:		
Present	3	8.6
None	32	91.4
Total	35	

Figure 2a
Before frontal view

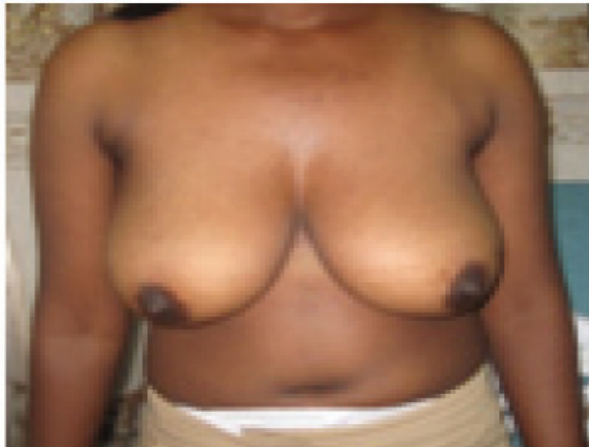

Figure 2b
After frontal view

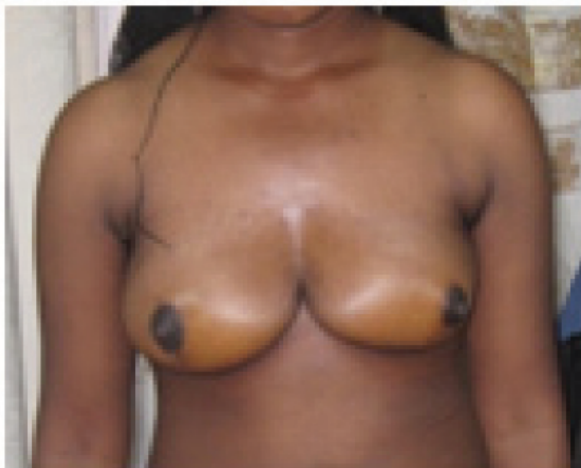

Figure 2c
Before lateral view

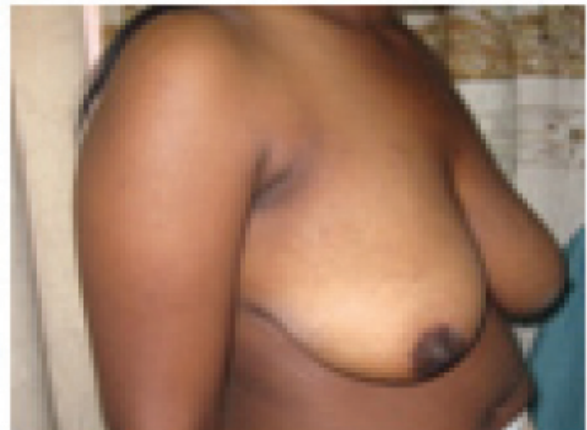

Figure 2d
After lateral view

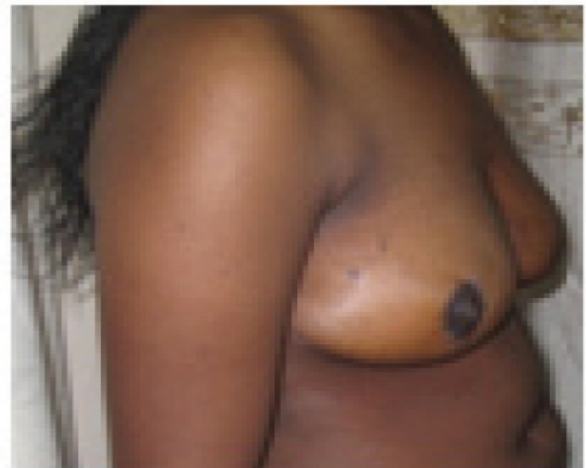

Figure 3a
Before frontal view

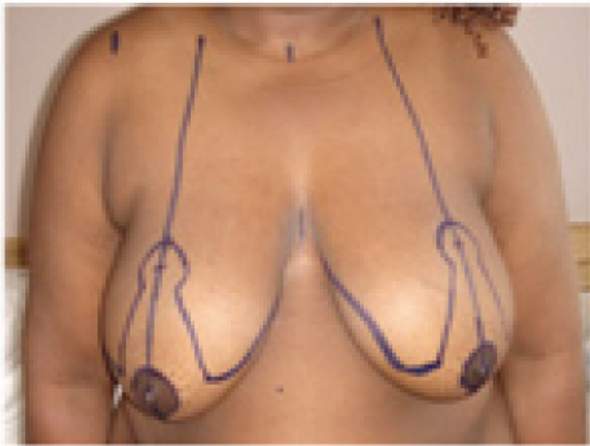

Figure 3d
Lateral view



Figure 3b
After frontal view this patient also had an abdominalplasty

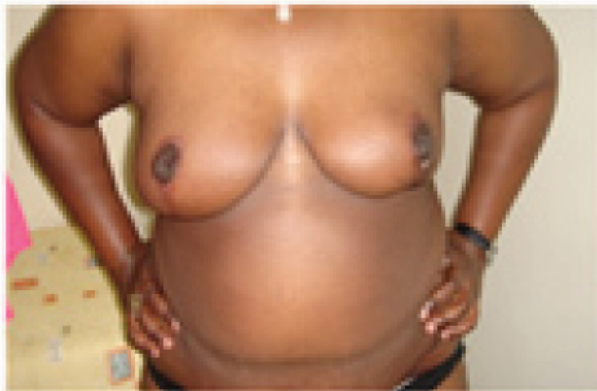

Figure 4a
Before lateral view

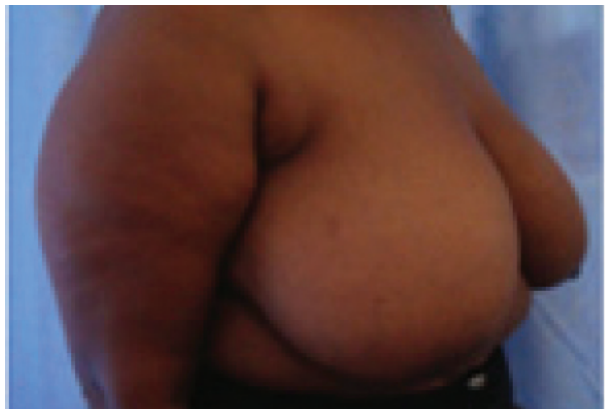


Figure 3c
Before lateral view

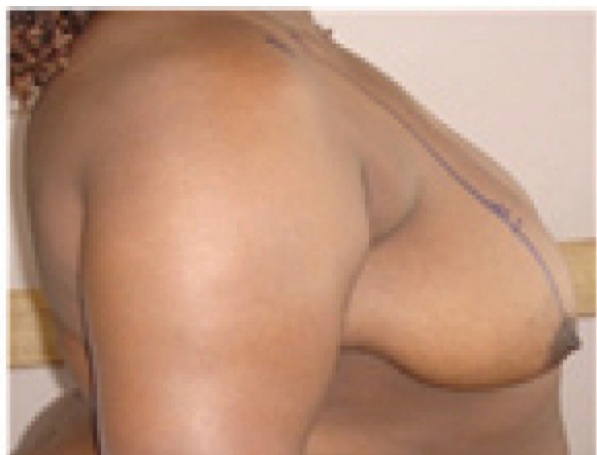

Fig.4b
After lateral view

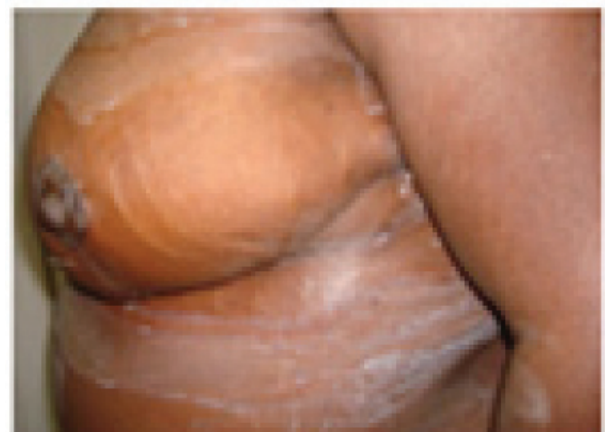

Figure 5a
Before lateral view

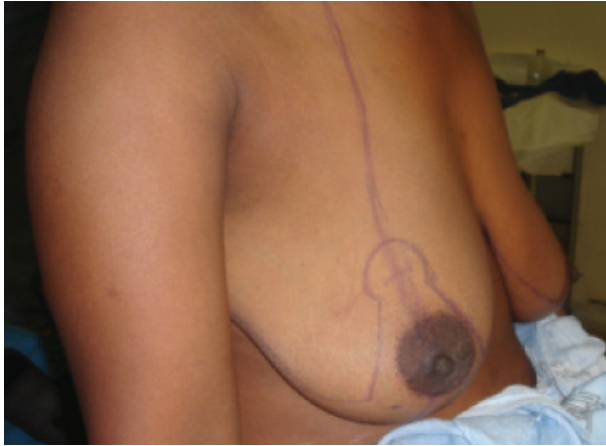

Figure 5b
After lateral view

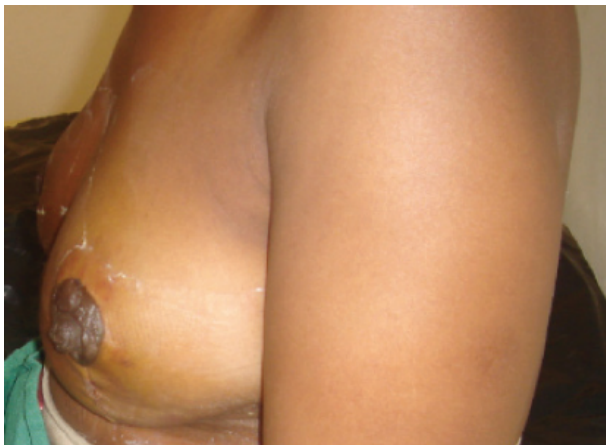

Figure 6a
Before frontal view

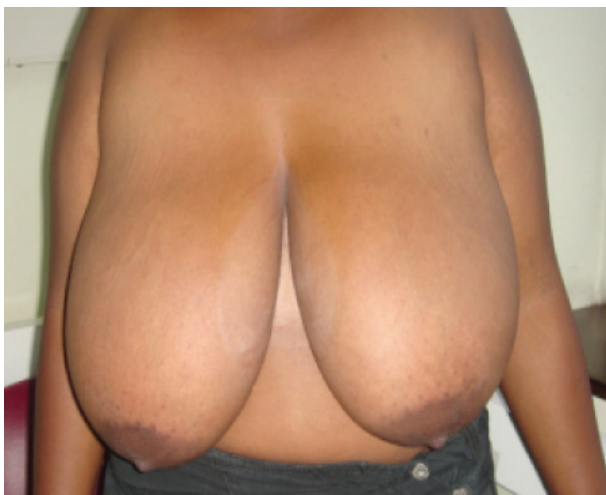
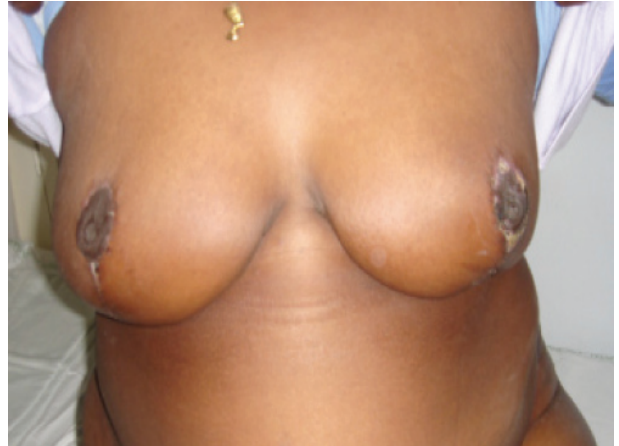
Figure 6b
After frontal view



DISCUSSION

In 1975, Ribeiro described the inferior pedicle technique (6). Two years later, Robins and later Courtiss and Golwyn (8) reported a similar procedure.

A short while later, Riech (9) and Georgiade and associates (10) published their experience using the technique. Since then, this has become one of the most popular methods of breast reduction in use.

In this study, the majority of patients were in the age group of 21-30 years. The oldest patient operated on was 86 years. Most of the patients in this study, the indication was both due to psychological and physical reasons. This study indicated that breast ultrasonography was the most common investigation done in these patients and five of them did not undergo specific investigations to rule out breast pathology at all.

The weight of excised breast tissues in the study was between 500 to >2001kg. The majority of patients had resection with breast tissue per resection weighing more than 1500gms. In a study by Lennart Blomqvist *et al*, the mean resection was 500gm per breast. He noted that the resection weights for insurance claims were 350 to 500gm. All patients in this study, qualify for insurance support.

The length of hospital stay was between three to four days mainly due to pain control and till completion of hematoma drainage or when it was less than 20ml/24 hours.

Several possible complications are reported in literature, such as failure to achieve desirable aesthetic result, decreased or lack of lactation, decrease or loss of nipple sensation or erogenous feeling of nipple or projection, post-operative pseudoptosis (bottoming out), infection, nipple necrosis and wound healing problems. Nipple necrosis is the most frightening complication of reduction mammoplasty. The rate

of nipple necrosis are reported as 0.8% using inferior pedicle technique and increase to 2.3% using the superior technique (11).

In this study, one patient suffered nipple necrosis of the right breast. Two patients suffered superficial wound infection of the inverted-T junction. This resolved on appropriate dressings while nipple reconstruction was performed three months later.

All patients in this study felt satisfied with the final outcome.

REFERENCES

1. Grabb and Smiths' Plastic surgery 6th edition pg 593-Scott L.Spear
2. Reduction Mammoplasty provides long term improvement in Health Status and Quality Of life –Lennart Blomqvist, MD, Agneta Erickson and Yvonne Bradberg. *J. Plastic and Reconstructive Surgery*. 2000.
3. Dabbah. A., Lehman, J., A., Parker, M. G. *et al.* Reduction Mammoplasty An Outcome Analysis. *Ann. Plastic Surgery*. 1995; **35**: 337.
4. Robbins, T. H. A reduction mammoplasty with the areola. Nipple base on an inferior pedicle. *Plast. Reconstructive Surg.* 1977; **59**: 64.
5. Schlenz, I., Kuzbari, R., Gruber, H. *et al.* The sensitivity of Nipple-areolar complex : an anatomic study. *Plast. reconstr. Surg.* 2000; **105**: 905.
6. Ribiero, I. A new technique for reduction mammoplasty. *Plast. Reconstr. Surg.* 1975; **55**: 330.
7. Robins ,T. H. A reduction mammoplasty with the areola-nipple based on an inferior dermal pedicle. *Plast. Reconstr. Surg.* 1977; **59**: 64.
8. Courtis, E. H. and Goldwyn, R. H. Reduction mammoplasty by inferior pedicle technique. *Plast. Reconstr.* 1977; **59**: 500.
9. Reich, J. The advantage of a lower central breast segment in reduction mammoplasty. *Aesthetic Plast. Surg.* 1979; **3**: 47.
10. Georgiade, N. G., Serafin, D., Morris, R., *et al.* Reduction Mammoplasty utilizing an inferior pedicle nipple areola flap. *Ann Plast. Surg.* 1979; **3**: 211.
11. Annals of Surgical Innovations and Research 2009; **3**: 7. www.asr-journal.com/content/3/1/7.