

East African Medical Journal Vol. 88 No. 5 May 2011

TUBERCULOSIS OF THE CERVICAL SPINE MIMICKING A PARAPLEGIC TUMOUR IN IMMUNO-COMPROMISED PATIENT: CASE REPORT

A. Fazal, MBBS, FCPS(Orth) Consultant Orthopaedic and Spine Surgeon, Kenyatta National Hospital, P. O. Box 20723-00202, Nairobi, E. M. Gakunya, MBChB, Lecturer, and R. B. Ombachi, MBChB, Lecturer, Department of Orthopaedics, College of Health Sciences, University Nairobi, P. O. Box 19676-00202, Nairobi, Kenya

TUBERCULOSIS OF THE CERVICAL SPINE MIMICKING A PARAPLEGIC TUMOUR IN IMMUNO-COMPROMISED PATIENT: CASE REPORT

A. FAZAL, E. M. GAKUNYA and R. B. OMBACHI

SUMMARY

Tuberculosis (TB) of the spine is a common problem in Kenya especially since the spread of HIV infection in the 1980's. However immune-compromised patients do not necessarily present in a similar radiological and histopathological way as patients with a competent immune system. It is against this background that we present the case of a 50-year old male living with HIV/AIDS who presented with progressive lower limb weakness and paraesthesia for the past two months. Magnetic Resonance Imaging (MRI) and X-rays revealed an infiltrative lesion of C6-C7 vertebrae. Our main differential diagnosis was a primary or metastatic. Though TB was one of our differential diagnoses, we considered it less likely considering the infiltrative nature of the lesion, and the absence of paravertebral abscess. The patient underwent anterior cervical corpectomy of C6-C7, iliac crest grafting and instrumented fusion from C5-T1. Intra-operatively, the lesion was found to have been a fleshy, non-caseating and suggestive of tumour. However, histopathology results revealed TB with multinucleate giant cells and poor granuloma formation. This case illustrates that TB of the spine in patients who are immuno-compromised may present atypically as fleshy grey necrotic material similar to a tumour when the immune system is not competent enough to mount an adequate response to result in caseation and abscess formation.

INTRODUCTION

Tuberculosis (TB) of the cervical spine used to be quite rare with an incidence of 3-5% in patients with TB (1). Recently however, spine surgeons in Kenya are seeing increasing numbers of these patients primarily due to the HIV infection epidemic. Most patients present with a history of neck symptoms of less than two months and some studies have shown an incidence of paraplegia in up to 42.5% of patients (2). The classic MRI findings of cervical TB consist of vertebral collapse, paravertebral abscess, disc sparing, calcification and cord compression (3). Intra-operative finding generally consist of scarring, necrotic bone and paravertebral abscesses containing cheese-like white necrotic material (4). Though the above is true for immune-competent individuals, those patients living with HIV infection may present quite differently as illustrated in the case present.

CASE REPORT

A 50-year-old male, known case of HIV infection on HAART presented to the Kenyatta National Hospital in October 2011. He complained of neck pains for the last six months and gradually increasing lower limb weakness for the last two months. For the last two weeks he had been unable to walk, and he had been stool and urine incontinent for the past week. He denied fever or night sweats.

On examination, his general build was emaciated. He had pallor and some palpable lymph nodes in the cervical region. Neck examination revealed tenderness of the lower cervical spine. Range of motion of the cervical spine was difficult and painful.

Motor strength bilaterally was 5/5 in C5 and C6, 4/5 in C7, 3/5 in C8 and T1, and 0 in the lower limbs.

Sensation on both sides was present until the inguinal region (L1) suggestive of incomplete cord injury. Biceps reflex (above the lesion) was normal, triceps reflex (at the lesion) was absent, and knee and ankle reflexes (below the lesion) were increased. His CD4 count was 156.

Radiology of the lesion:

Figure 1 a,

Plain x-rays of cervical spine A/P and lateral views revealing destructive lesion at C6-C7 with associated vertebral collapse and disc height lost at the same level (arrow)

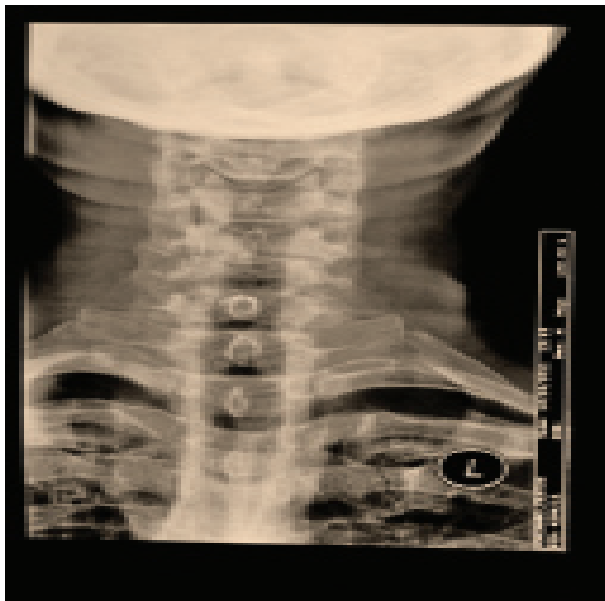


Figure 1 b

Plain x-rays of cervical spine A/P and lateral views revealing destructive lesion at C6-C7 with associated vertebral collapse and disc height lost at the same level (arrow)

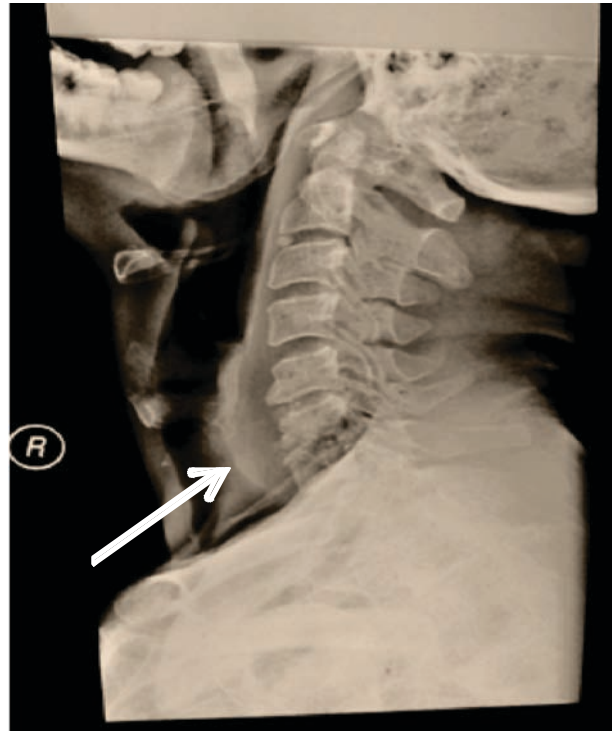


Figure 2 a

MRI cervical spine sagittal view (T2 weighted image) Note the infiltrative nature of the lesion and destruction of the intervertebral disc at C6-C7 (arrow)

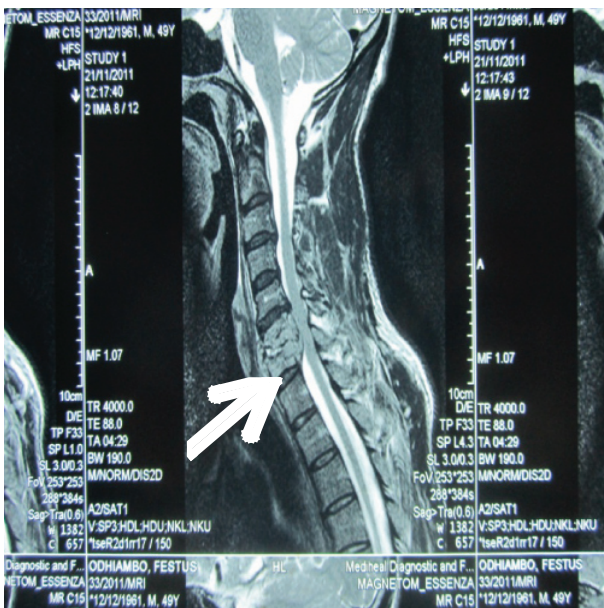


Figure 2 b

MRI cervical spine coronal view (T2 weighted image) Notice the absence of significant paravertebral abscess around C6-C7

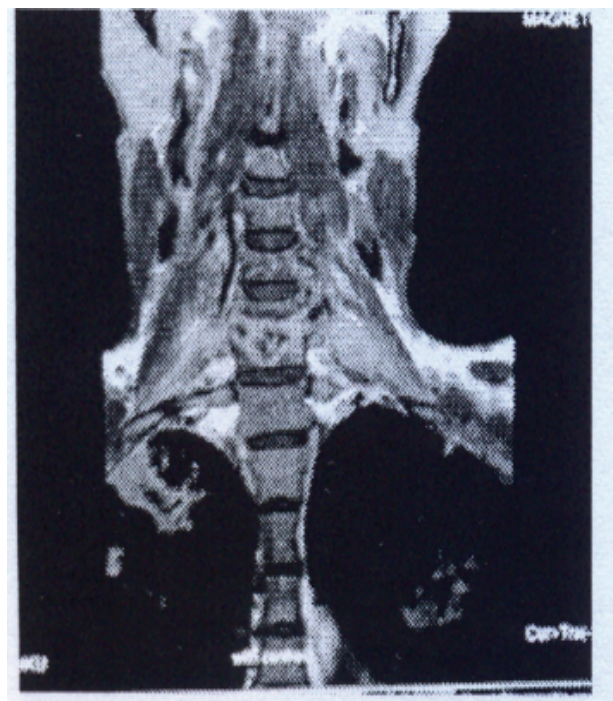
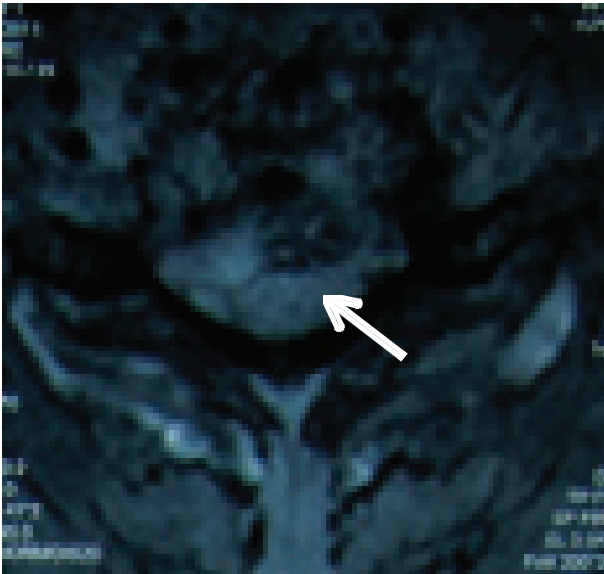

Figure 2 c

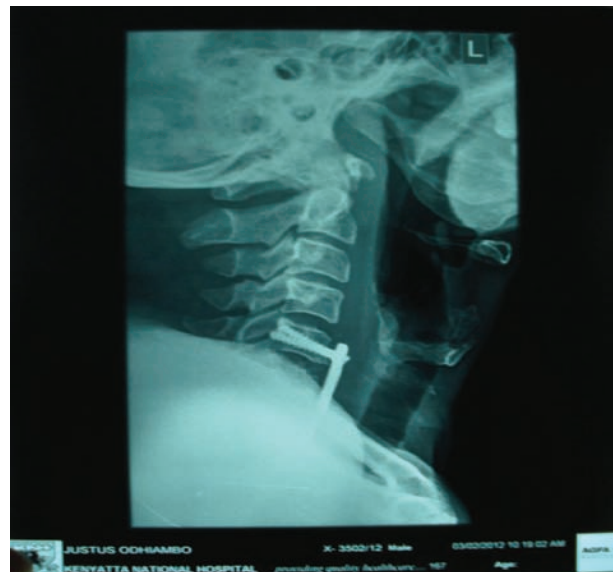*MRI cervical spine axial view (T2 weighted image)
Notice severe cord compression at this level (arrow)*



a Synthes® plate anchored in C5 and T1.

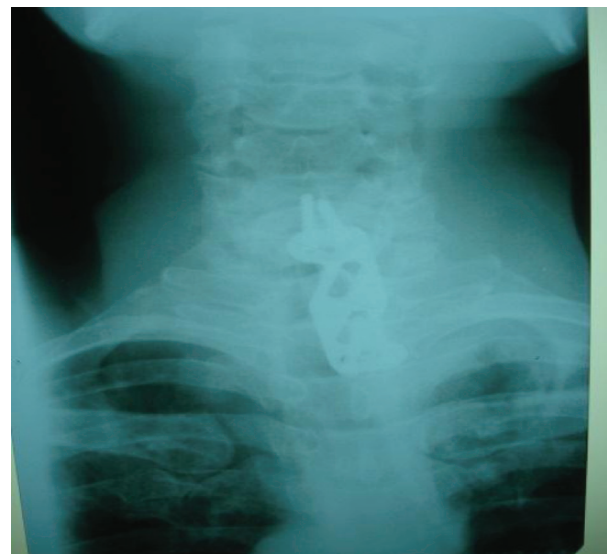
Figure 3

Post-operative radiographs



Surgery for the lesion: Considering the rapidly progressive neurological deficit and instability inherent in the spine due to two-column involvement, decision was made to offer the patient surgery. The aim of surgery were, 1. To obtain specimen for biopsy to establish a diagnosis 2. To decompress the spinal cord and 3. To reconstruct and stabilise the spine to avoid the C6-C7 segment from going into kyphosis.

We performed anterior cervical corpectomy and fusion. We used a right sided approach. We excised the C5-C6, C6-C7 and C7-T1 discs first. We did not encounter any paravertebral abscess. We then went on to do corpectomy of C6 and C7 vertebrae. No cheese-like necrotic material was encountered. All material was greyish and flesh-like reminiscent of a tumour. Care was taken to ensure that the cord was completely free at the end of the procedure and the PLL was clearly visible. We did not find the need to resect the PLL. The lateral limit of corpectomy was the uncinat process to avoid injury to the vertebral arteries. We reconstructed the excised segment with cotico-cancellous iliac crest graft and stabilised it with



Post-operative course: The patient was kept in a hard collar for two weeks and slowly weaned to a soft collar. Histopathology was indicative of TB. It revealed few multinucleated giant cells with a poor attempt

at granuloma formation.

Figure 4 (a)

Presence of scattered multinucleated giant cells (H and E staining) (arrow)

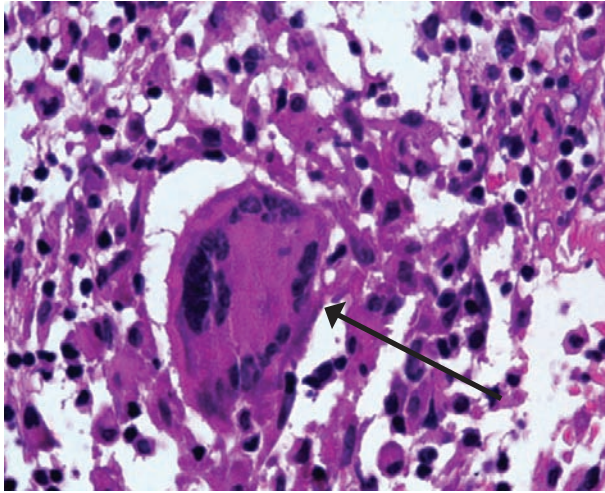
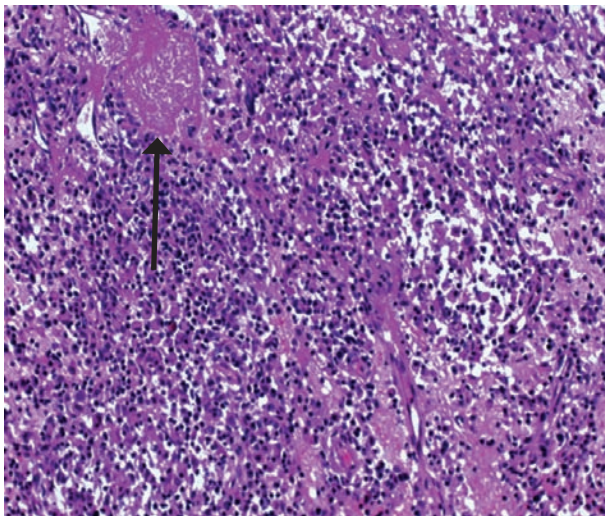


Figure 4 (b)

Some poor attempt at granuloma formation (H and E staining) (arrow)



The patient was started on anti-TB therapy consisting of isoniazid, rifampin, ethambutol and pyrazinamide, in addition to HAART (Zidavudine, Lamuvidine, Efavirenz) that he was already taking. At two months follow up he had regained full power in his upper limb on both sides. His sensation which was at L1 had now reached L5 distribution. He is yet to regain power in his lower limbs or bowel/urinary continence.

DISCUSSION

It is widely accepted that an intact immune system is fundamental to enable the body to fight against TB anywhere in the body(5). HIV infection is known

to specifically target CD4+ cells. These type 1 CD4+ T-lymphocytes (Th1) secrete IFN which activates macrophages to produce a variety of substances including TNF α which are involved in growth inhibition and killing of mycobacteria(6). In addition, Saukkonen *et al* found that activated macrophages in individuals infected with HIV produced significantly less TNF α as compared to immune-competent individuals when infected with the H37Ra strain of *M. Tuberculosis* (7).

It is these same activated macrophages that cluster together to 'wall off' the mycobacteria in the form of granulomas where caseation necrosis occurs leading to paravertebral abscesses and the cheese like material that we find during surgery(8). The presence of HIV infection, therefore, severely curtails the body's ability to mount this effective immunological response resulting in an atypical presentation.

Numerous published reports have described how TB can mimic other pathologies, earning it the title of 'the great imitator' together with syphilis (9-11). Mirzai in 2005 published a report where a cervical spine tuberculoma mimicked a meningioma, whereas Evangelista *et al* reported in 2004 a case of multifocal spine tuberculosis mimicking metastasis(12, 13).

The presence of HIV infection and the resulting immuno-suppression in an already difficult disease further predisposes the patient to present in an atypical manner. Clinicians should, therefore regard all lesions in the spinal vertebrae of HIV infected patients with a high index of suspicion of being TB, even if the nature of presentation may suggest otherwise.

REFERENCES

1. Dobson, J. Tuberculosis of the spine; an analysis of the results of conservative treatment and of the factors influencing the prognosis. *J. bone and joint surg. Brit. vol.* 1951; **33**: 517-531.
2. Fang, D., Leong, J. C. and Fang, H. S. Tuberculosis of the upper cervical spine. *J. of bone and joint surg. Brit. vol.* 1983; **65**: 47-50.
3. Bajwa, J. Evaluation of the role of MRI in spinal Tuberculosis: A study of 60 cases. *Pak. J. Med. Sci.* 2009; **25**: 944-947.
4. Dogulu, F., Baykaner, M. K., Onk, A., *et al.* Cervical tuberculosis in early childhood. *Child's nervous system: official J. Intern. Soc. Ped. Neurol.* 2003; **19**: 192-194.
5. Murray, J. S., Madri, J., Pasqualini, T. and Bottomly, K. Functional CD4 T cell subset interplay in an intact immune system. *J. Immun.* 1993; **150**: 4270-4276.
6. Schluger, N. W. and Rom, W. N. The host immune response to tuberculosis. *Amer. Resp. and crit. care med.* 1998; **157**: 679-691.
7. Saukkonen, J. J., Bazydlo, B., Thomas, M., *et al.* Beta-chemokines are induced by Mycobacterium tuberculosis and inhibit its growth. *Infection and immunity.* 2002; **70**: 1684-1693.
8. Tuli, S. M. General principles of osteoarticular

- tuberculosis. *Clinical orthopaedics and related research*. 2002: 11-19.
9. Kamani, L., Ahmed, A., Shah, M., *et al.* Rectal tuberculosis: the great mimic. *Endoscopy*. 2007; 39 Suppl 1:E227 - 228.
 10. Odejinmi, F., Annan, H. G. and Hussein, S. Y. Tuberculosis, the great mimic again? A report of two cases of pelvic tuberculosis initially suspected to be advanced ovarian carcinoma. *J. obst. gynae.* 2000; 20: 544-545.
 11. El Fakih, R. O., Chehab, B. M., Mortada, R. A. and Assi, M. Can tuberculosis mimic cancer? *Medic. J. of Austr.* 2009; 190: 340-341.
 12. Mirzai, H. Tuberculoma of the cervical spinal canal mimicking en plaque meningioma. *J. of spin. disorders & techniques*. 2005; 18: 197-199.
 13. Evangelista, E., Itti, E., Malek, Z., *et al.* Diagnostic value of 99mTc-HMDP bone scan in atypical