

East Africa Medical Journal Vol. 88 No. 3 March 2011

URETERIC PERFORATION FOLLOWING LAPAROSCOPIC ASSISTED VAGINAL HYSTERECTOMY (LAVH): CASE REPORT

P. L.W. Ndaguatha, MBChB, MMed, Senior Lecturer, Department of Surgery, College of Health Sciences, University of Nairobi, P. O. Box 19676-00202, Nairobi, Kenya

Request for reprints to: Dr. P. L.W. Ndaguatha, Department of Surgery, College of Health Sciences, University of Nairobi, P. O. Box 19676-00202, Nairobi, Kenya

URETERIC PERFORATION FOLLOWING LAPAROSCOPIC ASSISTED VAGINAL HYSTERECTOMY (LAVH): CASE REPORT

P. L.W. NDAGUATHA

SUMMARY

Ureteric injury is one of the most common complications of hysterectomy, both in open and laparoscopic and is a source of serious morbidity. Laparoscopy carries a higher risk because of increased use of electro-surgery close to the ureter when securing the uterine artery and it is more likely to be overlooked or to present late. Prevention is the best approach, which requires the surgeon to have a high index of suspicion. However, when the injury occurs, early recognition is important as the treatment at this stage avoids more serious complications. This case highlights these points and draws attention to this complication.

INTRODUCTION

Pelvic surgery is routinely performed by gynaecologists, urologists, colo-rectal and general surgeons. One of the complications encountered is injury to the lower ureter, it is particularly common during hysterectomy because of the close proximity of the lower ends of the ureters to the uterus. This has to do with the embryological development which brings the urological and reproductive structures in close proximity.

Ureteral injuries have been reported in 1.3 to 2.2 % of abdominal hysterectomies and in 1.3 and 0.03 % of laparoscopic and vaginal hysterectomies respectively (1). Though laparoscopy has been available in Kenya for some time, laparoscopic vaginal assisted hysterectomy is relatively new in Kenya and use of electro-surgery in sealing of the uterine artery during the laparoscopic hysterectomy (abdominal or vaginal approaches) is likely to be fraught with such injuries though rarely reported. This means that unless the surgeons are aware of the risk, the likelihood of high unnoticed ureteric injuries is to be expected with their consequent morbidity. This case report reveals one such complication and demonstrates the pitfalls which led to delayed discovery of the injury.

CASE REPORT

M.N.M. then 49 year old lady was admitted to MP Shah Hospital on 19-11-07 for an elective laparoscopic assisted vaginal hysterectomy (LAVH) because

of perimenopausal bleeding for more than four months. She was otherwise healthy and all routine investigations were normal. The operation was performed four days later on 23rd November 2007. The surgical notes indicated that it was uneventful. She did well post operatively and was discharged two days later on 25-11-07 to be followed up as outpatient. She was however re-admitted 11 days later (13 days post-operatively) complaining of vomiting, abdominal distension, and unrelenting abdominal pains for the previous four days. She also complained of dysuria but no pyrexia. Physical examination revealed a uniformly distended lower abdomen that was not moving with respiration. Generalised tenderness was elicited as well as positive rebound tenderness in the left iliac fossa. The bowel sounds were found to be reduced. The digital rectal examination indicated an empty rectum. She was thought to have an acute abdomen whose cause was not clear and therefore a surgical/urological consultation was made. The blood works revealed haemogram of 11.3g/dl. Leukocytosis (WBC of 15.2), elevated creatinine (164ng/l) but normal urea and electrolytes. The plain abdominal x-rays were reported as showing distended bowel loops, fecal loading in the ascending colon as well as sigmoid colon with no air / fluid level, while abdominal ultrasound showed right hydronephrosis. The diagnosis was revised to intestinal obstruction probable peritonitis and right hydronephrosis. A nasogastric tube was passed and was started on intravenous fluids and the antibiotic, cefuroxime (Zincef). Soap enema was also

ordered but was unsuccessful. The very night, she developed an acute urinary retention necessitating urinary catheterisation that yielded less than 500 ml of urine despite generous intravenous fluids.

The following morning, she was pyretic (temperature of 37.5°C.), abdomen was distended and tender and bowel sounds were absent. She underwent laparotomy and two litres of straw coloured peritoneal fluid was drained. Adhesions were released after which peritoneal lavage was performed and the abdomen closed leaving a tube drain in the pelvis. Despite this the pyrexia persisted and a large volume of clear fluid was recovered via the abdominal drain (> 900ml per day) while the urinary Foley catheter recorded reduced volume. After two days, ureteric injury was suspected and an intravenous urogram (IVU) ordered on 10-12-07. The IVU revealed a normal left ureter and right side hydronephrosis without demonstration of the ureter. A decision was made to re-explore the abdomen the following day intending to perform the right ureteric re-implantation with Boris's flap or psoas hitch. However, the patient's relatives requested for a second urological opinion from the attending urologist on the same day, sixth day post re-admission. A CT Urogram was requested by the author in order to ascertain the level of the injury. The images are as shown in figures 1 - 7.

Figure 1

US Right hydronephrosis and ascites (urinoma)

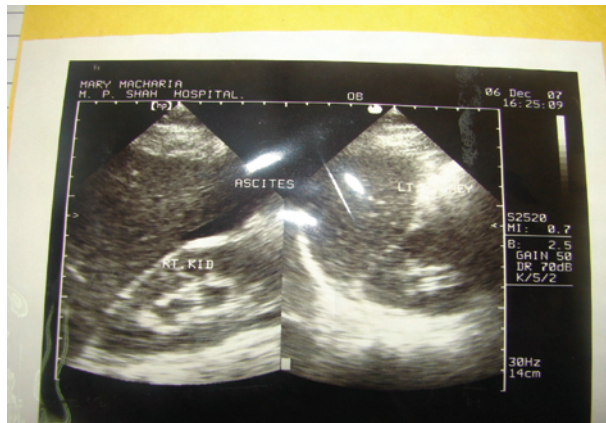

Figure 2

Plain abdominal X-rays (supine/lateral decubitus, distended bowel loops, no free air/fluid, faecal loading in ascending and sigmoid colon)

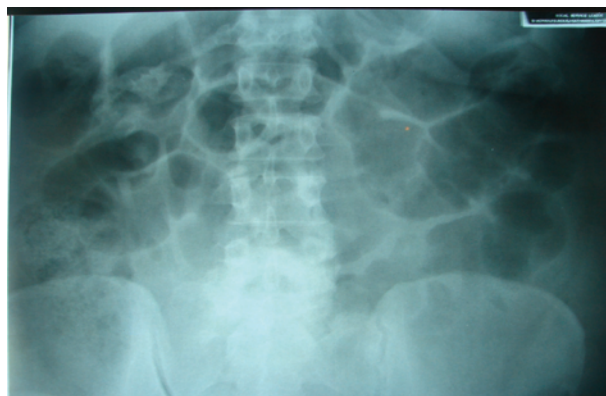


Figure 3

An IVU showing right hydronephrosis

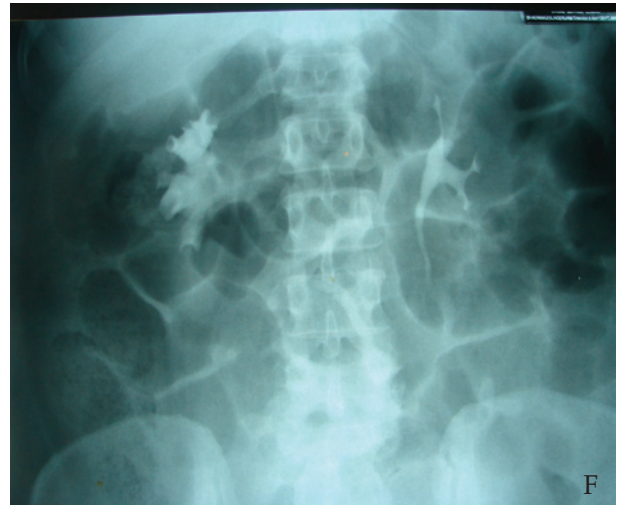

Figure 4

CTU axial view depicting right hydronephrosis

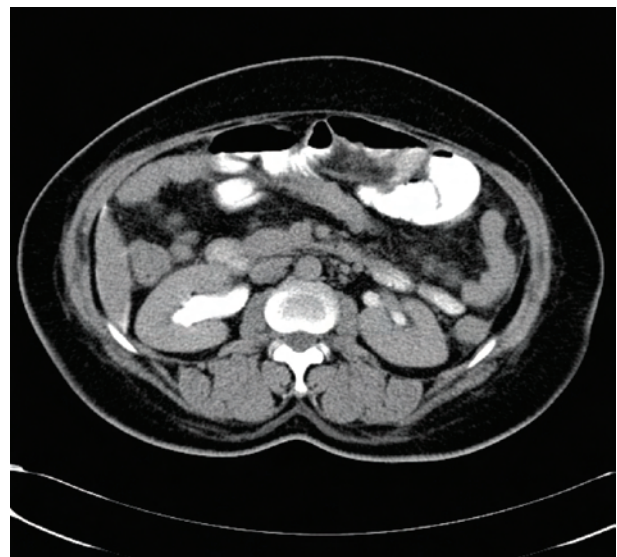


Figure 5

CTU coronial view depicting right hydronephrosis and the dye in the pelvis-depicting the pelvic urinary leak/urinoma

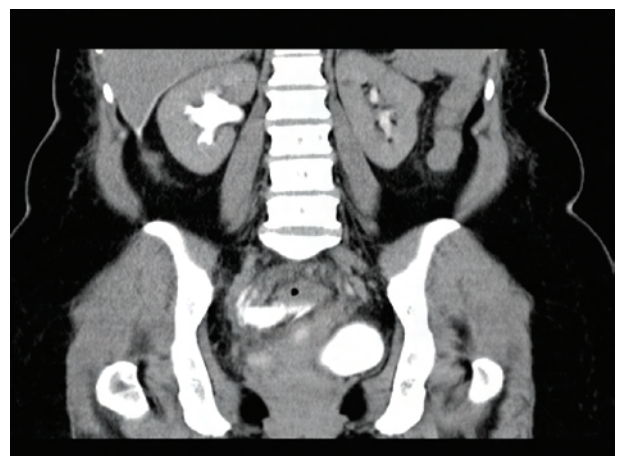
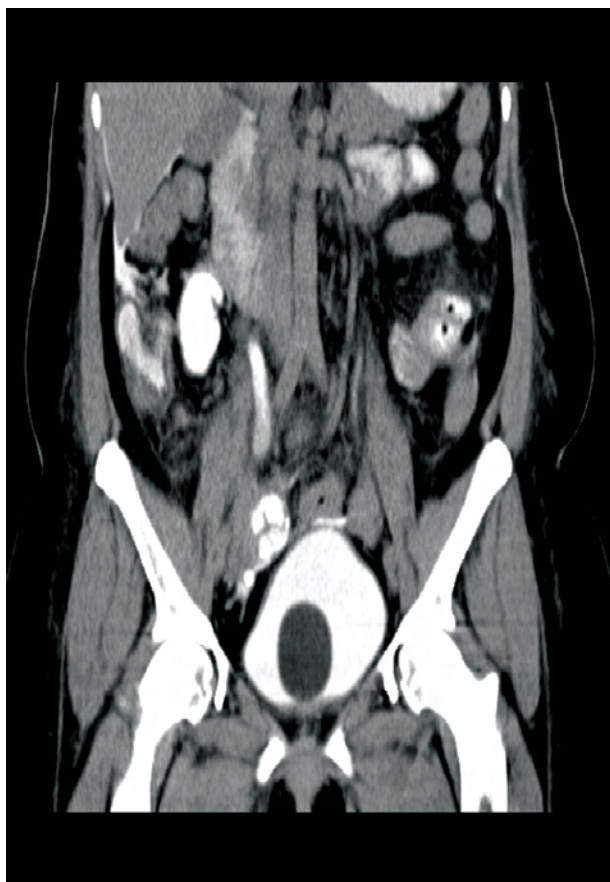
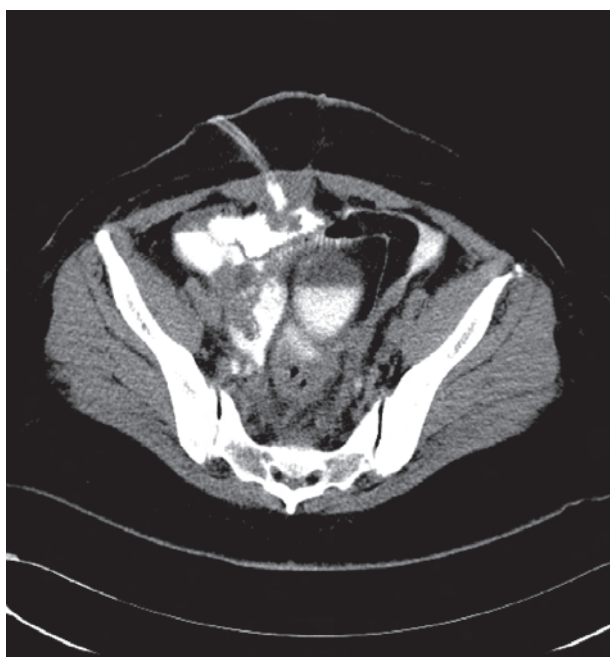Figure 6

CTU Urogram (coronal view depicting the level of right ureteric dye leakage

**Figure 7**

CTU Axial depicting the right ureteric leakage of the dye into the peritoneal cavity and note the drain earlier inserted-drinking clear fluid



Exploration of the ureter was done and a friable oedematous distal ureter with loose vicryl suture ligature about five centimetre from uretero-vesical (UV) junction was identified. Refashioning of both ends was done and since it was not possible to do primary end to end anastomosis due big gap, the distal remnant was ligated and psoas hitch and neo- uretero-cystostomy was done over a tizzard ureteric stent *in situ*, exited via the bladder to the suprapubic region for easy assessment of ipsilateral urine out put. Furosemide (Lasix) was administered intra-operatively and continued for 72 hours. During this period, the urinary output as measured from the stent was more than 1500mls/24 hours and the urethral catheter about 1000 ml /24 hours. The Tizzard catheter was removed on the tenth post-operative day, the patient was able to pass 1600ml within eight hours. Post-operative IVU showed normal flow of the dye in the bladder via the dilated ureter. She continued to be followed up as an outpatient and no complaints were reported. However two years later in mid 2009, she was reviewed and found to have incisional hernia. Advise to have it repaired was declined by the patient citing too may operations in the previous two years.

DISCUSSION

Laparoscopic surgery has several well known advantages over the conventional laparotomy which include reduced post-operative analgesic requirement, faster post-operative recovery which may be translated to shorter hospital stay, reduced costs, earlier return to economic activity as well as improved cosmesis and lower risk of adhesion formation(2). However, this surgery has its own inherent complications, which are particularly liable to occur during the learning curve of the surgeon. This is more so with lower end of the ureter than the mid and proximal ureter, as it lies close to the uterine artery. The injuries are thought to be due to usage of automatic endoscopic linear staplers, bipolar coagulation or harmonic scalpel and ligasure forceps, and in- adverted sutures placement during transvaginal closure of the vaginal cuff (3,4). Ligation or kinking can result from a suture or tie while stapling devices can block the ureter during vascular pedicle control. Haematoma or lymphocele accumulation can obstruct the ureter. Any of these can injure the ureter, but thermal injury due to electro-surgery used either for dissection or diathermy is common. It can happen when heat is applied directly to the ureter, but can also occur when the heat is applied close to, but remote from, the ureter even if the ureter itself is not touched. Experienced laparoscopists avoid applying heat close to the ureter whether for dissection or diathermy. Post-operative avascular necrosis results from a delayed recognition of ureteric injury leading to a leak.

The ureteric injury rate may be high initially but with mastering of the art, the rates have steadily declined from 1.6 to 0.1 % (5). Roger, *et al* (6) analysed their figures and concluded that high figures initially were due to surgical inexperience and technique development rather the instrument failure. They further said that in experienced hands and with perfect technique, the rate is probably similar whether stapling or bipolar diathermy is used to secure the uterine vascular pedicles. Experience, clean bloodless dissection and good knowledge of the anatomy are some of the principles of prevention. Asking for help when one is uncertain can also prevent complications or pick up injuries early. The delay in detecting the injuries can be minimised if the clinicians form a habit of having high index of suspicion (7). If any doubt of injury crops up during surgery, some surgeons will perform cystoscopy and ureteric catheterisation to be sure that the ureter is intact and if not then primary repair of affected ureter is undertaken (8). Further confirmation of the ureteric injury in early post-operative if suspected may be made by doing retrograde or ante grade pyelography or with CT urography scan or when available ureteral jet ultrasonography applicability (8-10). If the patient presents late post-operatively, certain symptoms and signs may point to this injury such as an abnormally increased drainage, fever, flank pain, abnormal vaginal discharge and peritonitis. The persistent leakage of urine eventually result into urinomas that may be occult initially and therefore manifest later with delayed complication of hydronephrosis, paralytic ileus, electrolyte imbalances and abscess formation (11) as evidenced in this patient. The urine leaks and urinomas have a mixed picture and may be confused with ordinary ascitis (figure 1), abdominal or pelvic abscess or haematomas (Figure 6, 7).

Diagnostic imaging plays a crucial role in promptly identifying these leaks and their extent and avoids the delay in managing the complications of the urinary leak. A plain abdominal x-ray may be necessary to rule out GIT causes of abdominal pain. Ultrasonography is cheap, very widely available, non-invasive and informative and must never be omitted. The utilisation of Transabdominal Ultrasonography including colour Doppler mapping has been described in the literature as having a great diagnostic potential as a method for non-invasive evaluation of post-operative ureteral conditions. US triads (absence of ureteric jet, ascitis and the presence or absence of hydronephrosis) are capable of differentiating diagnosis of complete, partial, or non-obstructive surgical ureteral injuries.

IVU has long been the major first line modality in evaluating the genito-urinary tract abnormality and has the advantage that it is widely available. However its reported sensitivity for diagnosing the ureteral injuries is low at 33% (12) thus missing

other leakages. The majority of the clinicians rely on IVU if they suspect any urinary tract pathology, but as shown in this patient, apart from indicating the presence of hydronephrosis, there was no evidence of urine leakage (Figure 3). This clearly shows that the IVU may not be always of any assistance hence the use of recently introduced multi slice helical CT scanner if available, more so the 3D CT urography (figures 4-7).

The CT is more sensitive and accurate after contrast material injection. This clearly identifies the site of the ureteral urine leak. It is less invasive compared to IVU or retrograde pyelography, and quick and is obtainable in 5-20 minutes. Its drawback in our setting is that it is expensive and not widely available. As more hospitals acquire the facility, it will replace the other current tests. In more advanced centres, the helical CT has supplanted the conventional CT and has the advantage of improved sensitivity. The good imaging resolution and rapid examination time of helical CT scan has significantly improved the examination course compared to IVU. Even more innovative is the 3D CT urography which has further improved the resolution. The 3D CT urography reformatted from thin axial-cut multislice CT imaging has helped the clinicians to interpret them better than conventional CT and hence improved the accuracy of diagnosing the urinary tract abnormalities (13).

Absence of these sophisticated tests does not absolve us from applying the sound principles, and these are learning points in this case report. The excessive clear fluid drainage as evidenced by the patient post operatively was sufficient to make the clinician have high index of suspicion of possible ureteric leak. The persistent presence of abdominal pains, distension and fever post LAVH is further ground to suspect the ureteric leak, leading to urinoma. Although the patient was initially clinically suspected to have intestinal obstruction secondary to adhesions, the plain abdominal x-ray films being inconclusive (Figure 2), one would have thought of the alternative, and considering the history, the ureteric injury was relevant differential diagnosis. The Ultrasound findings of ascitis and hydronephrosis really should have alerted the Radiologist had he been furnished with the relevant clinical data Figure 1.

There are few urologists locally, but most surgeons will have a working knowledge of dealing with many of the injuries of the ureter. When the injury is recognised intra-operatively, the management depends upon the type of injury. The ureteral laceration may be repaired or the endoureteric JJ stent catheter inserted, and if the ureter is kinked by the ligature, the simple removal may relieve the obstruction. In thermal or stapling device injury, the damaged area is excised and ureteral anastomosis or re-implantation is performed. In the post-operative

period, the management is guided by many factors. If recognised within the first week of the operation without evidence of infection, a surgical exploration and repair may be done. Repair after seven days may be difficult but all attempts should be made to re-implant the ureter after freshening the proximal severed edge without attempting to do uretero-ureterostomy (primary repair of the edges) as was to this patient. If this manouvre is technically not possible due to excessive oedema, inflammation or the poor condition of the patient, then reconstruction is postponed for about six weeks but diverting the urine by percutaneous nephrostomy. While attempting the repair, it is imperative that surgical principles are adhered to whether in intra or post-operative period. The principles are adequate debridement and use of only healthy ureter for anastomosis; perform tension free anastomosis by adequate ureteric mobilisation and to obtain complete haemostasis if possible, and the use of peritoneum or omentum to surround the doubtful anastomotic site (14).

In conclusion, the risk of ureteral complications after laparoscopic hysterectomy is comparable to that observed with laparotomy, provided the surgeon has sufficient experience. The challenge at hand is to increase the familiarity and skill of surgeons and ensure that injuries are avoided. Routine confirmation of ureteral integrity prior to conclusion of difficult pelvic surgery is vital in recognising the ureteral injury. Early post-operative identification of ureteric injury by appropriate radiological investigation should also be advocated in women who are not recovering satisfactorily on post-operative period. Repair of injury can then be performed as soon as possible to minimise the morbidity as high-lighted in this case report.

REFERENCES

1. Manavita, M. Review article. Complications and management of ureteric injury during laparoscopic hysterectomy. Project submitted towards Completion of Diploma in Minimal Access Surgery, World Laparoscopy Centre. Max Hospital Gurgaon, New Deihl India, April 2008.
2. Ray, C. Various approaches to Laparoscopic Hysterectomy. *Current Opin. in Obste. and Gynaecology*. 1994; **6**: 215-222.
3. Nezhath, C., Nezhath, F., et al. Injuries associated with the use of linear stapler. During operative laparoscopy: A review of diagnosis, management and prevention. *J. Gynaecol. Surg.* 1993; **9**: 145-150.
4. Kadar, N. and Lemmerling, L. Urinary tract injuries during laparoscopically Assisted vaginal hysterectomy: Causes and prevention. *Am. J. Obstet. Gynaecol.* 1994; **170**: 47-48.
5. Sow, A., Nikam, YA, et al. Urological complications of laparoscopic hysterectomy: a 4 year review at KK Women's and Children Hospital, Singapore. *Singapore Med. J.* 2007; **48**: 217-21.
6. Roger, A., McMaster Fay, Robert, A. Jones. *Gynaecol. Surgery*. 2006; **3**.
7. Waihenya, C. G. Ureterovaginal Fistula following laparoscopic assisted vaginal hysterectomy: Case report. *East Afr. Med. J.* 2006; **83**: 346-48.
8. Yudai, T. Hironori A., et al. Ureteral catheter placement for prevention of ureteral injury during laparoscopic hysterectomy. *J. Obstet. Gynaecol. Res.* 2008; **34**: 1-67
9. Hung, M. J., Huang, C. H., et al. Ultrasonic diagnosis of ureteral injury after Laparoscopically assisted vaginal hysterectomy. *Ultrasound in Obstet. and Gynaecol.* 2000; **16**: 279-283.
10. Hysin-Hung Wu, Pei Yin Yang, et al. The detection of ureteral injuries after hysterectomy. *Minimally Invasive Gynaecol.* 2006; **13**: 403-408.
11. Lukasz, E. S., Nagger, C. W. Ureteral injury presenting with hyponatremia. *Obstet. Gynaecol.* 2001; **98**: 974-976.
12. Ghali, A. M., El Malik, E. M., et al. Ureteric injuries: diagnosis, Management and outcome. *J. Trauma*. 1999; **46**: 150-158.
13. Van Beers, B. E., Dechambre, S., et al. Value of multislice helical CT scans and maximum-intensity projection images to improve detection of ureteral stones at abdominal radiography. *Am. J. Roentgen.* 2001; **177**: 1117-1121.
14. Brandes, S., Coburn, M., et al. Diagnosis and management of ureteric injury: an evidence-based analysis. *BJU Int.* 2004; **94**: 277-289.