

*East African Medical Journal Vol. 88 No. 1 January 2011*

#### RESTORATION OF ANAL SPHINCTER TONE BY GRACILOPLASTY: A REPORT OF FIVE CASES

S. O. Khainga, MBChB, MMed(Surg), FCS(Plast) FCS(CoSecSa), Lecturer, Department of Surgery, College of Health Sciences, University of Nairobi, P. O. Box 19676-00202, Nairobi, R. K. Tenge, MBChB, MMed(Surg), FCS(ECSA), Department of Surgery and Anaesthesiology, and P. W. Kituyi, MBChB, MMed(anaesthesia), Lecturer, Moi University, School of Medicine, P. O. Box 4606-30100, Eldoret, Kenya

Request for reprints: Dr. S. O. Khainga, Department of Surgery, College of Health Sciences, University of Nairobi, P. O. Box 19676-00202, Nairobi

## RESTORATION OF ANAL SPHINCTER TONE BY GRACILOPLASTY: A REPORT OF FIVE CASES

S. O. KHAINGA, R. K. TENGE and P. W. KITUYI

### SUMMARY

Stool incontinence can be as a result of congenital or acquired anal sphincter problems. It is a devastating state for a patient not to be able to control stools resulting into continued fecal soiling. It reduces an individual to a dejected and depressed person who becomes a social misfit. Hence any procedure that can alleviate this state is normally highly appreciated. Various techniques have been quoted in literature and use of gracilis muscle to form a neosphincter is one of them. Dynamic graciloplasty, is a technique whereby electrodes have been implanted into gracilis muscle and is connected to an implantable pulse generator which provides progressive levels of stimulation to convert the fast twitch, fatigue prone muscle fibres to a slow twitch, fatigue resistant fibres over eight week training period (1,2,3). This has shown improved efficacy over the static graciloplasty (3). In this case report, five patients with stool incontinence from different aetiologies are presented, all having been managed by static graciloplasty and intense physiotherapy with good outcomes reported.

### INTRODUCTION

The use of gracilis muscle is applicable in many aspects of perineal reconstruction such as: fecal incontinence, repairs following trauma, septum reconstruction, rectourethral, rectovaginal, rectovesical fistula repairs, recurrent rectal prolapse and others. The vital requirement in this technique is the absence of pudendal/neuropathy that provides a functional gracilis muscle that is wrapped around the anus to add onto the non-functional sphincter or to form a totally new sphincter following anorectal excision in low lying malignancy (2,3).

Unlike in the dynamic graciloplasty where electrodes are implanted into gracilis, transforming it from a fast twitching type II muscle fibre to a slow twitching type I muscle fibre (1), the static graciloplasty is followed by intense post-operative physiotherapy which educates the patient to use the adduction movement of the muscle to provide sphincteric function. The small finger was used to estimate

appropriate tension of the muscle wrapped around the anus. There are modified devices to perform intra-operative and manometry pressure measurements (1) which we did not have access to in this study.

### CASE REPORT

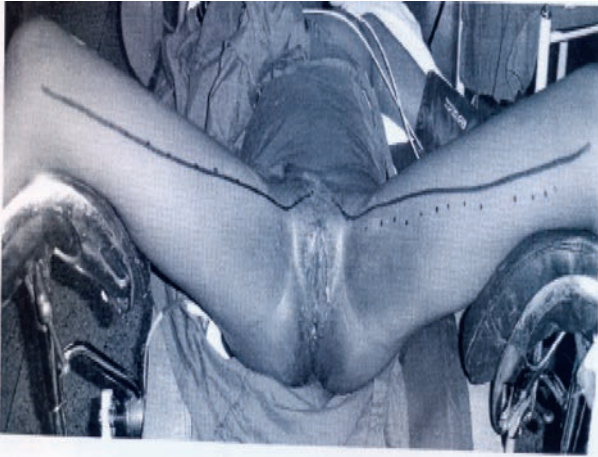**Case 1:** A 12 year old female, patient was referred from a neurosurgical clinic for plastic surgery review in September 2002. A diagnosis of "Currarino syndrome" which describes a triad of anorectal malformation, sacral bony abnormality and presacral mass was made. This patient had anal stenosis, large anterior defect of vertebra with thecal sac protruding anteriorly.

Anal dilatation was done but patient developed sacral abscess with anocutaneous fistula plus stool incontinence.

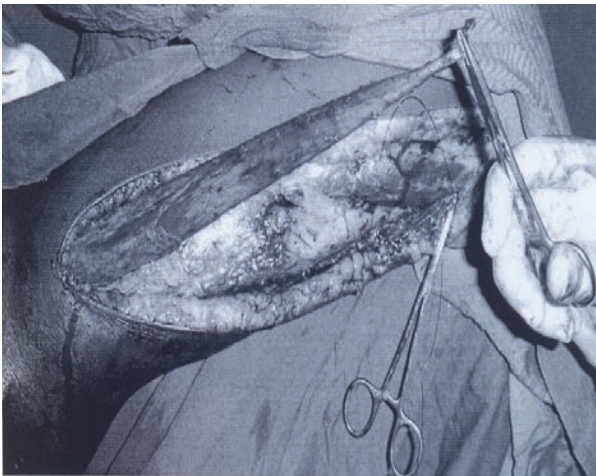
A diversion sigmoid colostomy was done in February 2001. In April/May 2005 graciloplasty was performed to provide stool continence.

**Figure 1**

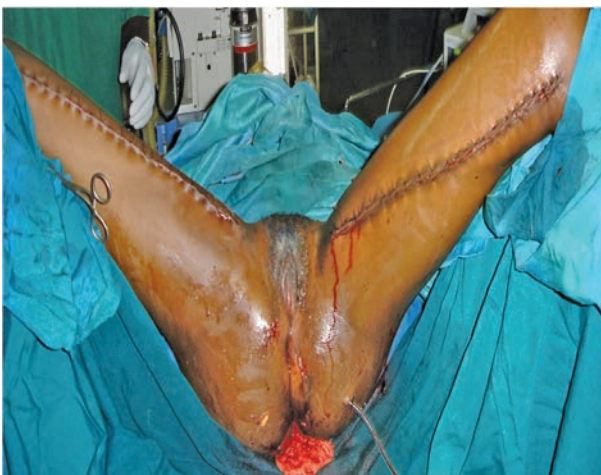*Markings designed for dissection of gracilis muscle*

**Figure 2**

*Gracilis muscle dissected based on superior neurovascular pedicle*

**Figure 3**

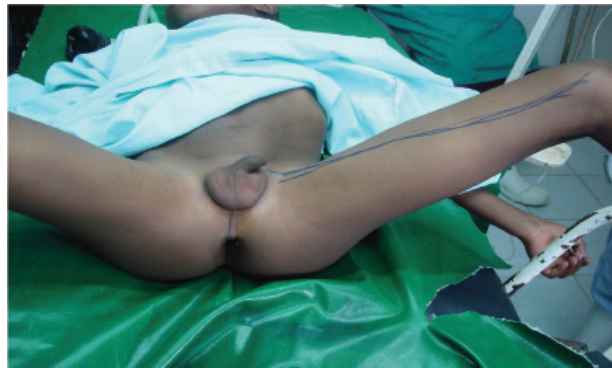*Gracilis muscle wrapped around the anal canal*



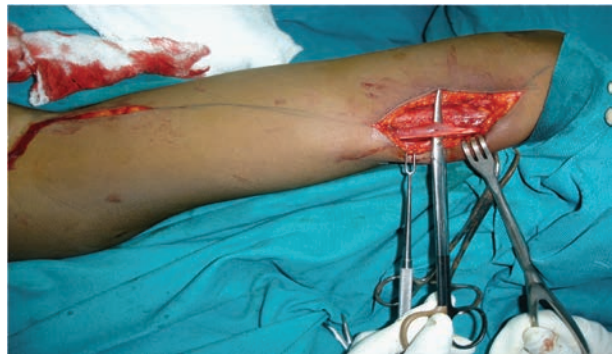**Case 2:** A seven year old Masai boy was admitted on 5/9/2006 with a one year history of recurrent rectal prolapse. He underwent a Thiersch stitch at a local district hospital which was complicated with abscess formation and later the stitch broke and extruded. Rectal prolapse recurred accompanied with stool incontinence. Graciloplasty was performed on 7/10/2006.

**Figure 4**

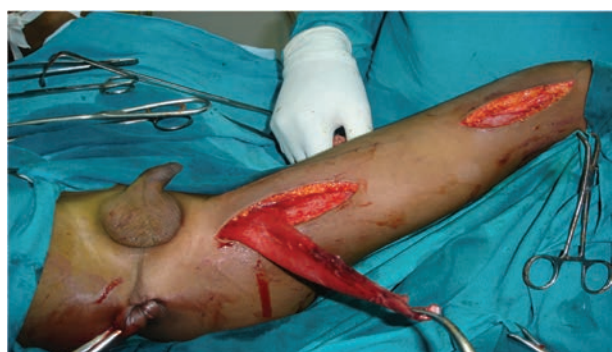*Patient in Lithotomy and landmarks for left gracilis muscle marked*

**Figure 5**

*Distal end of left gracilis muscle dissected upto point of insertion.*

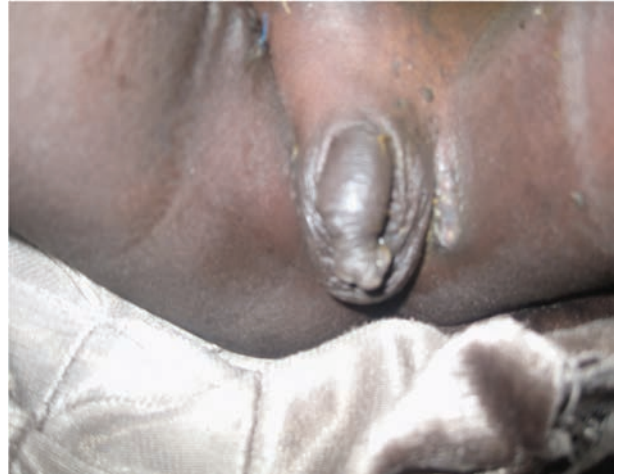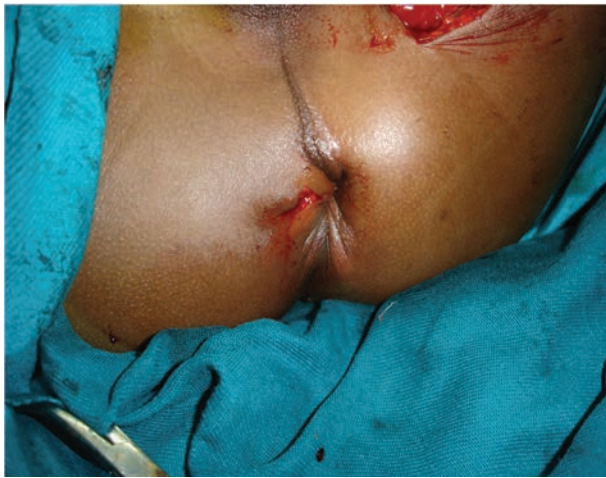**Figure 6**

*Left gracilis muscle already detached from point of insertion. Major Neurovascular pedicle identified and acts as fulcrum to rotate and insert gracilis muscle around the anus*



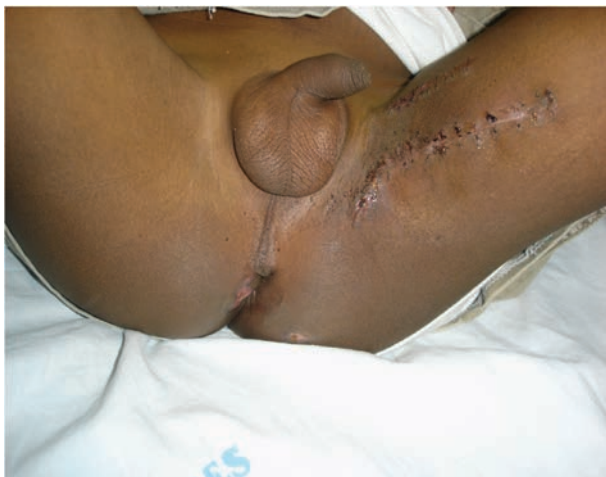**Figure 7**

*Gracilis muscle already wrapped around the anus. Note the slight bulge on left side at point of fulcrum*

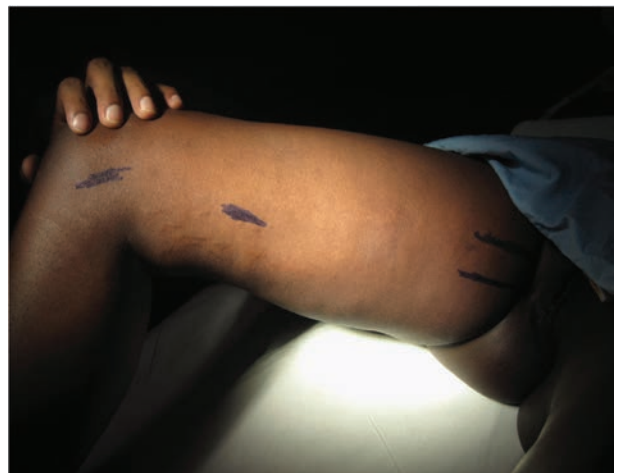

**Figure 8**

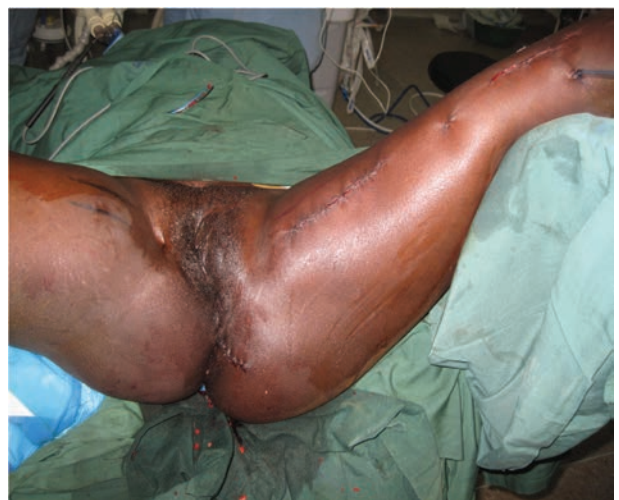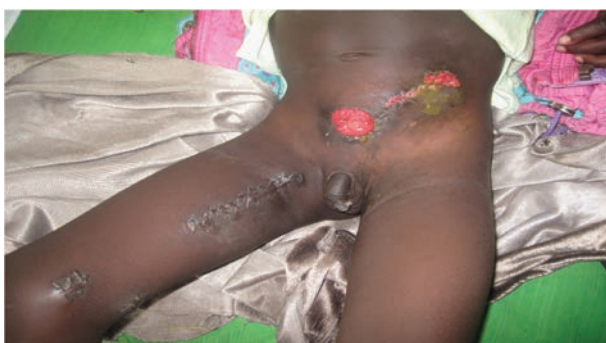*Two weeks after surgery both perianal and thigh wounds have healed*

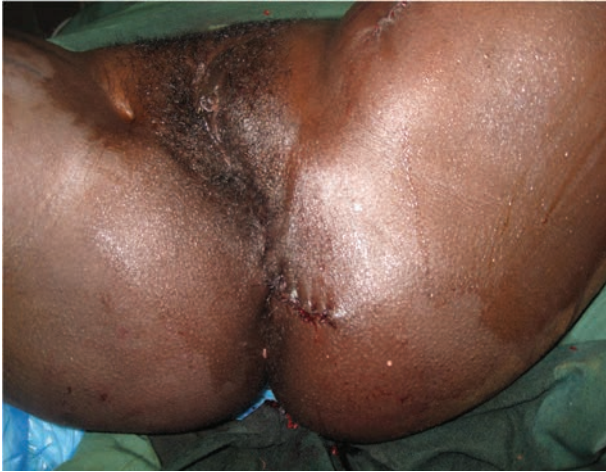

**Case 4:** A seventeen year old Burundani girl was referred to a plastic surgeon by a general surgeon in March 2009 with a history of a road traffic accident five years prior resulting into extensive perineal injury. Attempt to repair anal sphincter were unsuccessful and she was given a permanent colostomy. Graciloplasty was performed five years later in a relatively scarred perineum.



**Case 3:** A six year old male patient was referred to a plastic surgeon by a paediatric surgeon with a diagnosis of anorectal malformation with urine incontinence in May 2008. He had a colostomy before a definitive PSARP procedure. Graciloplasty was done on 28/5/2008 for stool continence by wrapping the muscle around the anus.





**Case 5:** A 14 year old boy, with mild spina bifida presented with both urine and stool incontinence. He however had power grade five in both lower limbs. He was noted to have a lot scarring in the perianal area due to incessant excoriation from urine and stools with subsequent infection. Graciloplasty was performed for stool incontinence with good results.

### RESULTS

All the five patients with stool incontinence gracilis muscle was tunneled around the anus. The patients started on sitz baths on day two post operatively. They were all started on perineal exercises by end of first week. The patients had healed by end of second week and a patients successful continence was achieved were no major

complications were reported.

### DISCUSSION

Use of gracilis muscle dates over many decades. The gracilis is a thin long (25cm long and 4-6cm width) thigh adductor muscle. It derives blood supply from minor pedicles (1-2), superficial femoral vessels and a major pedicle and from profunda femoris or medial circumflex femoral artery. Its nerve supply is from anterior branch of obturator nerve.

In all the five patients, the major pedicle was used with an intact obturator nerve to provide motor activity and hence tone to the neosphincter. We used the index finger to approximate appropriate anal tone. Gracilis muscle is a skeletal muscle that is prone to fatigue, however, the patients we operated reported benefits from this procedure. This experience could be replicated in patients with stool incontinence that have normal thigh muscle power.

### REFERENCES

1. Herald, R., Rosen, M. D., Gabriele, N., *et al*: Restoration of Anal Shpincter function by Single Stage Dynamic graciloplasty with a modified (split sling) Technique. *The Amer. J. Surg.* 1998; **175**: 187 – 193.
2. Robert, D., Madoff, Harald, R., Rosen and Cor, G. Baeten Safety & Efficacy of Dynamic Muscle Plasty for anal Incontinence: Lessons from a prospective, multi Centre Trial: *Amer. gastroenterol. Assoc.* 1999; **116**: 549 – 556.
3. Susan, M. and Steven, D. Muscle Transposition: Does It Still have a Role? *Clinics in Colon and Rectal. Surg.* 2005; **18**: