

East African Medical Journal Vol. 96 No. 5 May 2019

SUCCESSFUL RETRIEVAL OF AN EMBOLISED INTRACARDIAC UMBILICAL VENOUS CATHETER FRAGMENT IN A 1190 GM PRETERM

Dr. Sean Del-Rossi Quadros, MD, MMed, Department of Pediatrics and Child Health, Aga Khan University Hospital, Nairobi, P. O. Box 45680-00100 Nairobi, Kenya, Stanley Mugambi, MBChB, MMed, Department of Surgery, Aga Khan University Hospital, Nairobi, Bashir Admani, MBChB, MMed, Department of Pediatrics and Child Health, Aga Khan University Hospital, Nairobi, Fathimath Amal Abdul Sattar, MD, MMed Anesthesiology, Department of Anaesthesia, School of Medicine, University of Nairobi.

Corresponding author: Dr. Sean Del-Rossi Quadros MD, MMed, Department of Pediatrics and Child Health, Aga Khan University Hospital, Nairobi, P. O. Box 45680-00100 Nairobi, Kenya. Email: del-rossi.sean@aku.edu

SUCCESSFUL RETRIEVAL OF AN EMBOLISED INTRACARDIAC UMBILICAL VENOUS CATHETER FRAGMENT IN A 1190 GM PRETERM

S. D. Quadros, S. Mugambi, B. Admani and F. A. A. Sattar

ABSTRACT

Umbilical venous catheters (UVC) can be lifesaving in preterms and sick neonates. Although safe and effective, they are prone to various rare complications, most importantly, embolization of catheter fragments. We report a case of accidental transection of an UVC that was lodged in the left atrium appendage (LAA), with its inferior end within the inferior vena cava (IVC) and a challenging, however, successful retrieval using an EN Snare Catheter technique with improvised use of a Fogarty Balloon. To our knowledge, our case is the first reported in East Africa.

INTRODUCTION

Umbilical venous catheters (UVC) and umbilical arterial catheters (UAC) are used in critically ill neonates as well as premature low birth weight babies. Umbilical venous catheters are crucial for the administration of intravenous medications and fluids and delivery of parenteral nutrition, as well as for blood sampling. These venous catheters can be lifesaving as peripheral venous access can be difficult and the need for long term use in preterms as well as sick neonates. Umbilical arterial catheters are usually used for central blood pressure monitoring as well as blood sampling.^[1] Although UVCs are generally safe, they have been associated

with infrequent complications such as infection, thrombus formation and embolised catheter fragments that mandate its removal.^[2] Embolised catheter fragments usually have the risk of sepsis, cardiac arrhythmias, cardiac perforation and pulmonary embolism which necessitate its retrieval either surgically or percutaneously.^[3] Herein, we report a case of accidental transection of an UVC that was lodged in the left atrium (LAA), with its inferior end within the inferior vena cava (IVC) and its successful retrieval using a snaring technique with improvised use of a Fogarty Balloon.

CASE REPORT

A twenty-day-old 1190g preterm, born at 27 weeks' gestation had a size 3.5 Fr UVC inserted on the first day of life. With no indication to keep the catheter in situ, its removal was attempted. During manipulation, the catheter was accidentally transected with a scalpel while removing the holding suture at the umbilical base. An urgent attempt to retrieve the fractured portion by local exploration was unsuccessful as it had already retracted into the umbilical vein and the tip was not visible. To ensure reduced risk of embolization of the catheter fragment, an urgent exploration via a small supra

umbilical transverse incision was attempted under sedation. Despite our efforts, the UVC was not found within the distal umbilical vein, and the decision was taken to close the incision and plan for surgical or percutaneous removal of the catheter fragment.

An abdominal x-ray showed the catheter fragment distal tip located in the left atrium (LA) and its lower end within the inferior vena cava (IVC) (Fig 1). Echocardiography confirmed that the distal tip of the catheter fragment had crossed from the right atrium (RA) to the left atrium (LA) via the patent foramen ovale (PFO) and lodged within the left atrial appendage (LAA).

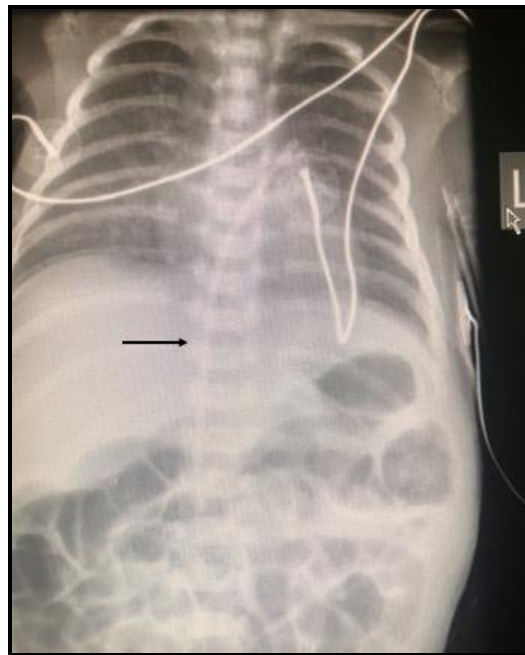


Figure 1: Roentерogram showing umbilical venous catheter fragment (bold arrow), with its proximal end within the inferior vena cava and its distal end within the left atrium.

After, discussion with the medical team (neonatologist, cardiologist, pediatric surgeon), we decided to retrieve the catheter fragment percutaneously due to the extreme surgical risk involving a 1190g preterm. Within the cardiac catheterization laboratory, under general anesthesia, trans-femoral access was extremely difficult and

in view of the extreme risk of perforation of LAA, we decided to take the baby to theatre and attempt percutaneous retrieval in with the help of a C-arm imaging scanner intensifier as the first option and surgical retrieval as our second option.

Due to the extreme difficulty in achieving trans-femoral access and the lack of small

french (Fr) gauge snare catheters for extreme preterm neonates, a supra umbilical transverse incision was done by the surgeon, the falciform ligament was identified and divided with the umbilical vein isolated and opened. A 6 Fr EN snare (Merit Medical) was introduced through a 6 Fr EN snare catheter (smaller size snares were not available). Under image intensifier fluoroscopy, the lower end of the catheter fragment was identified and the EN snare was introduced towards the tip. Due to the large sized snare in comparison to vascular lumen's internal diameter, the snare, with each attempt, kept pushing the catheter fragment's lower end upwards with the distal end coiling in the LAA (Fig 2). With risk of perforation of the LAA, this maneuverer was abandoned. A 3 Fr Fogarty balloon was introduced, through a 4 Fr sheath, pushed through the IVC into RA. The balloon was inflated at 4 atmosphere pressure within the RA and pulled down towards the IVC-RA junction, this maneuverer allowed the catheter tip mid segment to shift down into the IVC as the fogarty balloon and catheter fragment held snugly within the IVC, with its distal end being pulled back from LAA to LA and into

the RA (Fig 3) with slow pull back of the balloon. The SVC was accessed via a surgical cut-down and the 6 Fr EN snare was reintroduced through a 6 Fr EN snare catheter towards RA from SVC. The catheter fragment tip, after release of the fogarty balloon, was immediately snared within the RA (Fig 4), an 8cm catheter fragment together with the entire snare system was pulled out through the SVC access.

There was minimal blood loss during the entire procedure. Post-procedure, haemostasis achieved surgically. Total fluoroscopy time was 30 minutes. A post procedure echocardiography demonstrated a 6mm atrial septal defect with adequate cardiac function. Baby was transferred back to the neonatal intensive care unit (NICU) with stable haemodynamics. The baby was discharged uneventfully three weeks later with a weight of 2kg. Follow-up reviews in the neonatal and cardiac clinics show that the baby is doing well with adequate weight gain and normal developmental milestones. During her last cardiac review at 6 months of age, echocardiography showed a very tiny septal defect measuring 2mm, with anticipated closure in the new future.

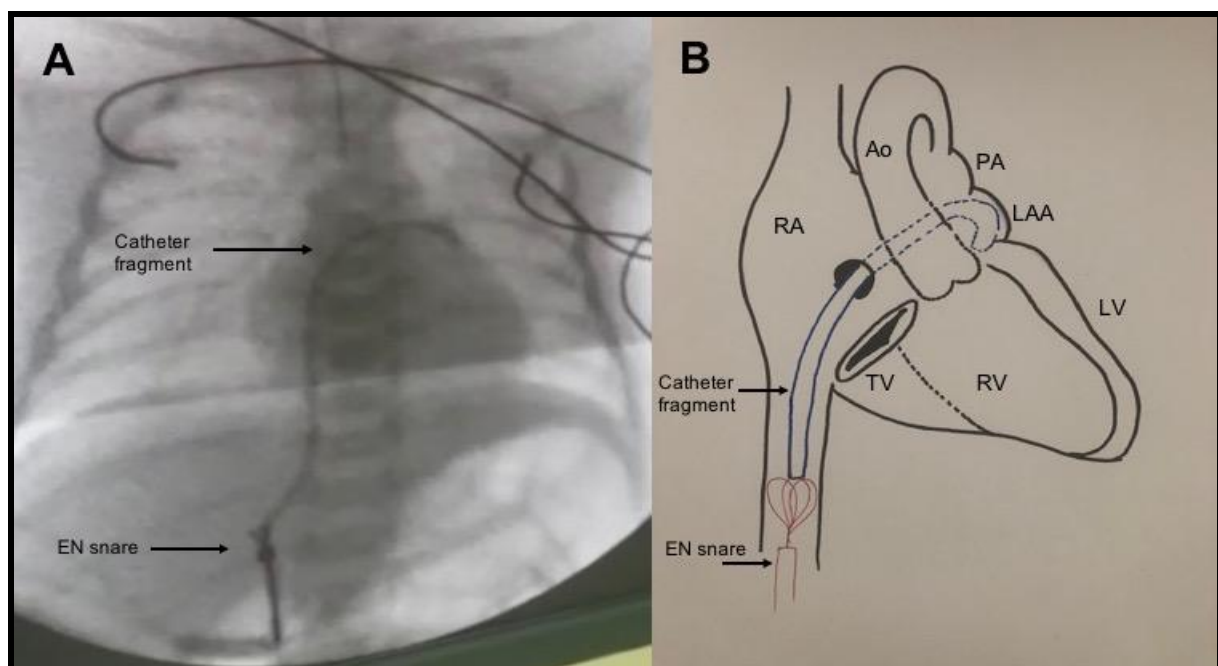


Figure 2: Fluoroscopic image showing snaring attempt of the lower tip of catheter fragment by an EN snare, with distal end of catheter tip being pushed up and coiling within left atrial appendage. RA: right atrium, RV: right ventricle, TV: tricuspid valve, Ao: Aorta, PA: pulmonary artery, LAA: left atrial appendage, LV: left ventricle

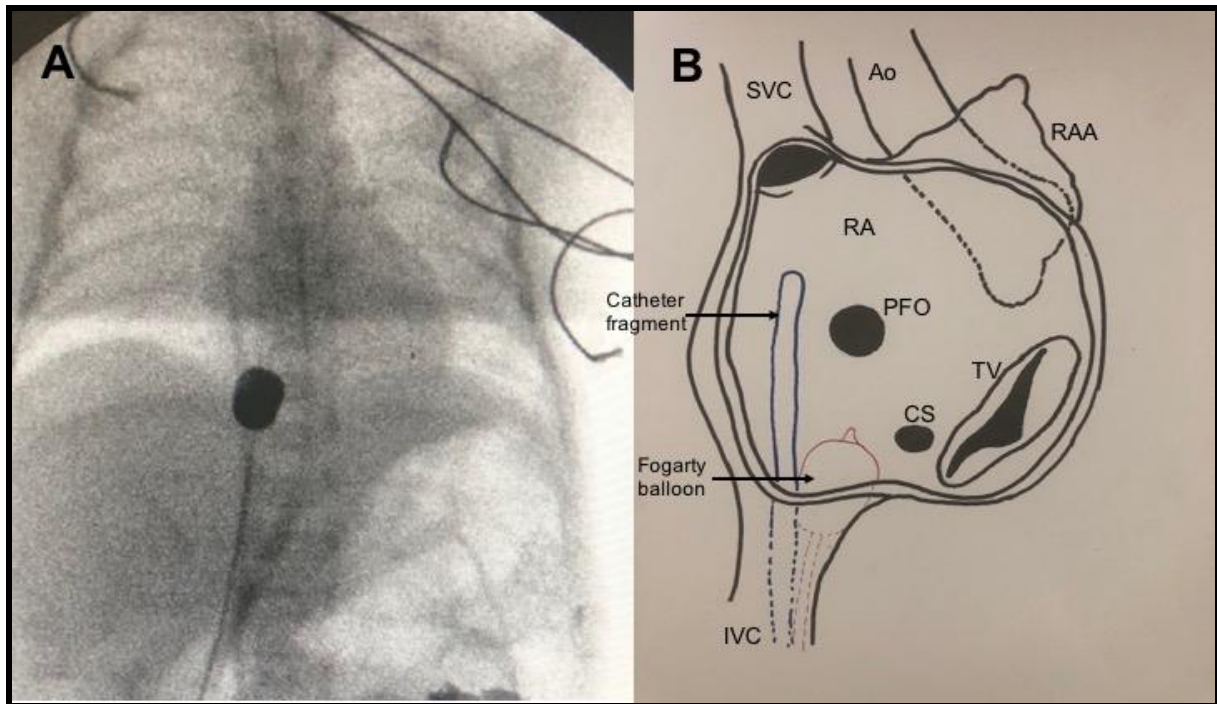


Figure 3: Fluoroscopic image showing a fogarty balloon inflated and snugly holding catheter fragment mid segment at the inferior vena cava-right atrium junction, with the distal end of the catheter fragment pulled back into right atrium. RA: right atrium, TV: tricuspid valve, Ao: Aorta, SVC: superior vena cava, IVC: inferior vena cava, CS: coronary sinus, PFO: patent foramen ovale

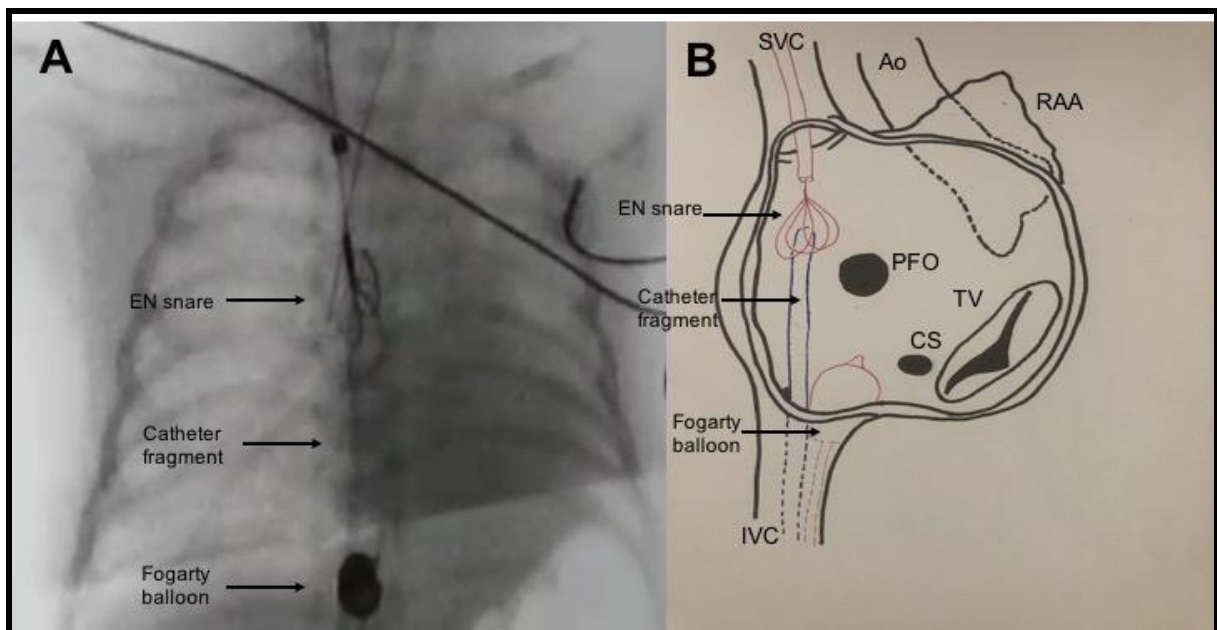


Figure 4: Fluoroscopic image showing snaring of the umbilical catheter fragment from the superior vena cava, with a fogarty balloon inflated and snugly holding the catheter fragment at the inferior

vena cava-right atrium junction, an 8cm catheter fragment retrieved. RA: right atrium, TV: tricuspid valve, Ao: Aorta, SVC: superior vena cava, IVC: inferior vena cava, CS: coronary sinus, PFO: patent foramen ovale

DISCUSSION

Umbilical venous and arterial catheters have become not only reliable intravascular accesses in both the sick neonate and low birthweight neonates while in the neonatal intensive care units (NICU), but have also been generally easy to insert, safe and effective. Although infrequent, they have been associated with complications such as thrombus formation, infections and embolised catheter fragments,^[2] and therefore, used for the shortest period until an alternative peripheral venous access is obtained.

Embolised catheter fragments appear to be the most challenging of all the complications reported in literature. Both percutaneous^[2-7,10] and surgical^[8,10] retrieval of such fragments has been reported, and to the best of our knowledge published data has been limited to case reports only. Retrieval of catheter fragments is usually performed percutaneously, due to high risks involved with the surgical approach, since the first report by Thomas et al. of non-surgical percutaneous removal of an intra-cardiac foreign body in 1964.^[11] However, in low birth weight infants (<1500g), percutaneous retrieval can be challenging due to micro cardiovascular structures and the availability of the interventional expertise as well as small catheter sizes to cater for such small infants. Attempts at retrieval of catheter fragments, in small neonates, may be made after obtaining vascular access with larger sheaths, however at the expense of vascular damage.

From the original use of a simple wire loop, various methods have been described in reported literature for percutaneous retrieval of foreign bodies, including snaring techniques, micro balloon techniques,

retrieval baskets and biopsy forceps.^[9] The most common technique for embolised catheter fragments is the snaring technique with goose-neck snares, available in various sizes.^[10]

In our case, our initial challenge was the lack of adequate snare size to cater for such a low weight preterm (1190g) as well as difficulty in obtaining vascular access in this neonate. We sought to have a surgical cut down to access the umbilical vein distally with a larger internal lumen diameter to allow introduction of the 6 Fr EN snare, which was the only available snare. Due to the small lumen diameter of the IVC, this 6 Fr snare was unable to grasp the inferior tip of the catheter fragment and with each attempt we kept pushing the distal tip within LAA. Due to high risk of its perforation, this maneuver was abandoned. Our second challenge was the inability to get to the distal end of the catheter fragment lodged in the LAA, so we improvised with a Fogarty balloon inflated in the RA and with each pull down, where the catheter and the balloon were held snugly at the IVC-RA junction, we managed to pull back the fragment across the PFO into the RA, and gain access to the distal end of the catheter from the SVC with successful snaring of the catheter fragment within the RA.

To the best of our knowledge, this case of successful retrieval of an embolised umbilical venous catheter fragment, is the first reported in the region. Our intention is to highlight some of the challenges faced with regard to retrieval of umbilical catheter fragments and to emphasize, that although simple, removal of umbilical catheters must be done carefully by the right medical personnel and with the right instrumentation with appropriate steps to ensure successful removal and to emphasize

inspection of the umbilical catheter tip to ensure that no fragment remains within the infants' cardiovascular system.

CONCLUSION

Umbilical venous catheters are frequently used in the NICU. Although safe and effective they are prone to various rare complications, most importantly, embolization of catheter fragments. We have described the successful retrieval of an umbilical catheter fragment with a snaring technique with improvised use of a Fogarty Balloon, despite challenges faced with vascular access and inadequate sized snares for preterms. To our knowledge, our case is the first reported in East Africa.

REFERENCES

1. Butler-O'Hara M, Buzzard CJ, Reubens L, McDermott MP, DiGrazio W, D'Angio CT. A randomized trial comparing long-term and short-term use of umbilical venous catheters in premature infants with birth weights of less than 1251 grams. *Pediatrics*. 2006; 118(1):e25-35.
2. Young T, Shaddy RE. Successful percutaneous retrieval of an intracardiac catheter fragment in an 800-g premature infant. *J Perinatol*. 2003;23:67-8.
3. Bautista AB, Ko SH, Sun SC. Retention of percutaneous venous catheter in the newborn: A report of three cases. *Am J Perinatol*. 1995;12:53-4.
4. Ruiz CE, Nystrom GA, Butt AI, Zhang HP. Percutaneous retrieval of a broken umbilical catheter from left atrium in a premature newborn. *Cathet Cardiovasc Diagn*. 1995;36:265-8.
5. Gasparis PA, Santana D, Blewett C, Bohannon WT, Silva MB., Jr Endoluminal retrieval of a dislodged umbilical vein catheter. *Vasc Endovasc Surg*. 2004;38:583-6.
6. Gross DM, Cox MA, Denson SB, Ferguson L. Unique use of a tip-deflecting guide wire in removing a catheter embolus from an infant. *Pediatr Cardiol*. 1987;8:117-9.
7. Simon-Fayard EE, Kroncke RS, Solarte D, Peverini R. Nonsurgical retrieval of embolized umbilical catheters in premature infants. *J Perinatol*. 1997;17:143-7.
8. Abbruzzese PA, Chiappa E, Murru P, Stefanini L, Longo S, Balagna R. Surgical retrieval of an embolized central venous catheter in a premature baby. *Ann Thorac Surg*. 1998;66:938-9.
9. Paulus BM, Fischell TA. Retrieval devices and techniques for the extraction of intravascular foreign bodies in the coronary arteries. *J Interv Cardiol*. 2010;23:271-6.
10. Anjan KD, Bijender S, Dilip K, Neeraj A. Broken umbilical vein catheter as an embolus in a neonate - An unusual preventable complication. *J Neonat Surg*. 2013;2:45.
11. Thomas J, Sinclair-Smith B, Bloomfield D, Davachi A. Non surgical retrieval of broken segment of steel spring guide from right atrium and inferior vena cava. *Circulation*. 1964;30:106-108