

East African Medical Journal Vol. 94 No. 5 May 2017

**VENTILATOR INDUCED LUNG INJURY (VILI) IN ACUTE RESPIRATORY DISTRESS SYNDROME (ARDS). "BAROTRAUMA" TO "BIOTRAUMA": CASE REPORT**

P.C. Saini, MBBS, FCCM, FICM, FCC, FD, Intensivist, J. Atina, MBBS, MMed, Pulmonologist, Department of Intensive Care Unit, The Nairobi West Hospital, Nairobi, Kenya

Request for reprints to: P.C. Saini

**VENTILATOR INDUCED LUNG INJURY (VILI) IN ACUTE RESPIRATORY DISTRESS SYNDROME (ARDS). "BAROTRAUMA" TO "BIOTRAUMA": CASE REPORT**

P.C. Saini and J. Atina

**SUMMARY**

**Acute respiratory distress syndrome is the most severe manifestation of acute lung injury and it is associated with high mortality rate. ARDS is characterized by the acute onset of diffuse neutrophilic alveolar infiltrates protein-rich edema due to enhanced alveolar-capillary permeability and hypoxemic respiratory failure. Mechanical ventilation is the main ARDS supportive treatment. However, mechanical ventilation is a non-physiologic process and complications are associated with its application. Mechanical ventilation may induce lung injury; referred to as ventilator-induced lung injury (VILI) and it is in form of alveolar rupture due to over distension of alveoli due to positive pressure ventilation i.e. Volutrauma, Barotrauma, Biotrauma. The Biotrauma is a form of VILI is the ability of inflation volume to disrupt the alveolar-capillary interface and promote proinflammatory cytokine released from the lungs and trigger the systemic inflammatory response syndrome, and can lead to inflammatory injury in the lung as well in other organs. The biotrauma is the leading cause of mortality in patient with ARDS. The lung protective ventilation strategy- Low tidal volume ventilation has shown some reduction in mortality in patients with ARDS but mortality is still high in patient with severe ARDS secondary to Pneumocystis jiroveci pneumonia (PJP) despite of lung protective ventilation strategy. In patients with Severe ARDS due to PJP, the outcome can be improved with the use of Extracorporeal life support (ECLS) techniques, such as extracorporeal membrane oxygenation (ECMO) or extracorporeal CO<sub>2</sub> removal (ECCO<sub>2</sub>R), because with such technique the patient can be given very low tidal volume 2-4ml/kg/PBW and risk of VILI can be avoided.**

**INTRODUCTION**

Acute respiratory distress syndrome (ARDS) is the most severe manifestation of acute lung injury (ALI) and is relatively common

in the ICU setting (1, 2). Despite advances in our understanding of the pathophysiology and management of ALI/ARDS, it is still associated with high mortality rate (3, 4). Mechanical ventilation (MV) is the main

ARDS supportive treatment (4). It is intended to deliver air/oxygen at tidal volumes and frequencies sufficient to provide adequate alveolar ventilation to reduce the work of breathing and to improve oxygenation. However, MV is a non-physiologic process, and complications are associated with its application, including increased risk of pneumonia, impaired cardiac performance and lung injury. During MV, pressures, gas volumes, respiratory rates, and concentration of inspired oxygen are often applied at values that exceed those normally experienced by healthy lungs during spontaneous breathing (5). Mechanical ventilation may induce lung injury, referred to as ventilator-induced lung injury (VILI). Frequently, VILI is related to macroscopic injuries associated with alveolar rupture. Clinical manifestations include interstitial emphysema, pneumothorax, pneumomediastinum, and Pneumoperitonium (5). It is generally accepted that alveolar stretch applied to the lung parenchyma, induced by either large inspired tidal volumes (volutrauma) or high ventilator pressures (barotrauma), to shear stresses occurring at the interface of open and closed lung regions (known as atelectrauma), and to cellular inflammatory response (biotrauma), play an important role in the genesis of ventilation induced lung injury, increasing vascular permeability, accumulation of lung fluid and inflammation induced by MV (6,7). The four mechanisms that lead to increased VILI are better described as follows.

The volutrauma as a result of alveolar over distension of alveoli and disruption of the alveolar-capillary interface, leading to inflammatory infiltration of the lungs and a clinical condition that resemble ARDS (8, 9). The effects of high inflation volumes are more marked in infiltrative lung disease with a decreased functional lung volume, like pneumonia and ARDS because the inflation volumes are distributed

preferentially to region of normal lung function and this predispose to volutrauma from over distension of alveoli in normal lung regions.

The Atelectrauma is a lung injury of small airway epithelium as a result of repetitive opening and closing of small airways during positive pressure ventilation, possibly by generating excessive shear forces (11). It can be mitigated by the use of positive end-expiratory pressure (PEEP), which provides a pressurized "stent" to keep the small airways open during expiration.

The Barotrauma is a type of lung injury due to positive pressure ventilation in which air leaks from rupture in the airways and distal airspace. The air that escapes can enter the pleural space (pneumothorax), or it can move along the bronchovascular bundle into the mediastinum (pneumomediastinum), or up into subcutaneous tissue (subcutaneous emphysema), or it can track in down the mediastinum and enter the peritoneal cavity (pneumoperitoneum). This form of VILI is called barotrauma (figure 4) even though the sources of injury can be high alveolar volume (i.e., volutrauma) (19).

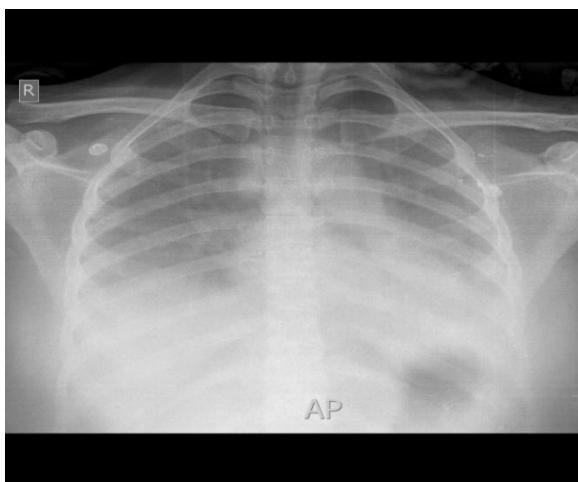
The Biotrauma is a form of VILI is the ability of positive pressure ventilation to promote proinflammatory cytokine released from the lungs at inflation volumes that do not produce any structural damage in the lungs (12). This is called biotrauma, and it can trigger the systemic inflammatory response syndrome, and can lead to inflammatory injury in the lung as well in other organs. This means that mechanical ventilator can be a source of inflammatory-mediated multiorgan failure (13), like that seen in severe sepsis and septic shock.

## CASE REPORT

30 years female patient was admitted with Respiratory distress secondary to

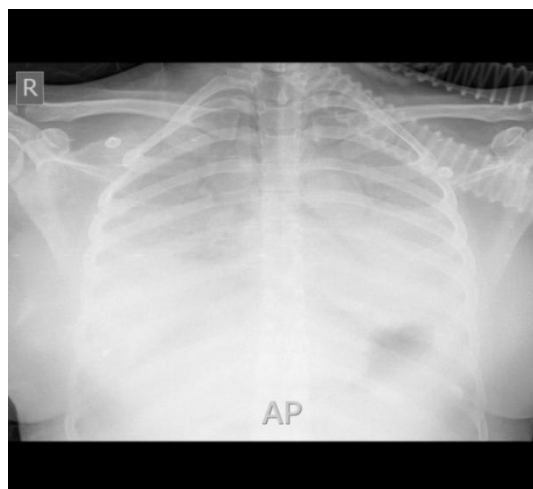
Pneumonia. She was a known case of Retroviral Disease on treatment with very low CD4 count. On admission she was tachypnoeic RR-36/min, Tachycardia HR-120/min, SpO<sub>2</sub> 85% on simple Facemask with Oxygen 10L/min, Normotensive. She was fully awake and oriented to time, place and person. Provisionally she was diagnosed as "Pneumocystis jiroveci pneumonia in Retroviral Disease". She was put on Non Rebreather Mask (NRM) with Oxygen 20L/min, SpO<sub>2</sub> increased up to 90-92% and PaO<sub>2</sub> was 56mmhg. She was put on High Dose Cotrimoxazole and Steroid as per the Guidelines. She remained stable overnight. On Day 2nd she was put on Non-invasive mechanical Ventilation because of decreasing PaO<sub>2</sub> in Arterial Blood Gas. She was tolerating NIV alternative with NRM with 20L/min Oxygen. She remained in same condition for next 2 days.

**Figure-1**  
Chest X ray on NRM oxygen mask



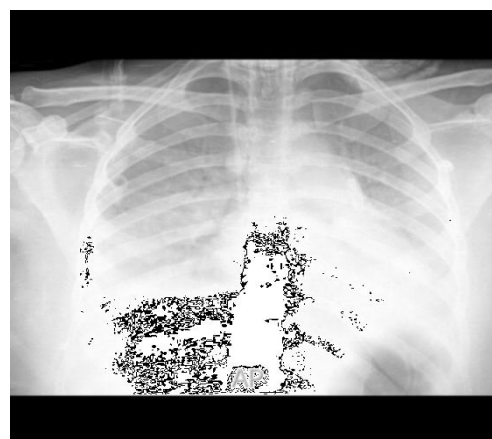
On day 5th, morning hours, she had developed Altered sensorium with worsening respiratory distress, worsening Chest X ray, severe hypoxemia (SpO<sub>2</sub> <85%, PaO<sub>2</sub> <40 mmhg).

**Figure-2**  
Chest X ray on Non-invasive Mechanical Ventilation



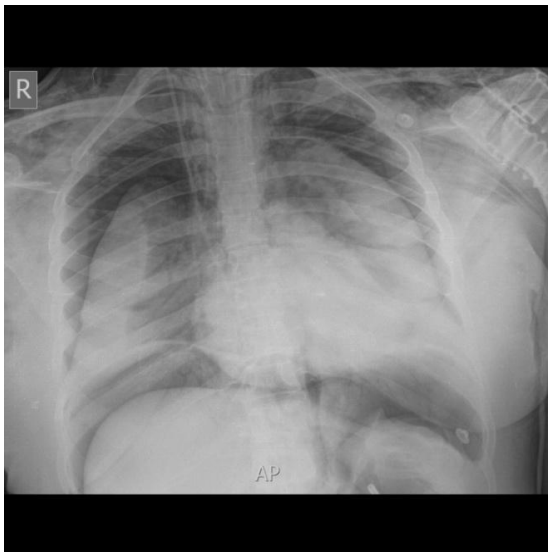
She was put on Invasive Mechanical Ventilation and Lung protective ventilation strategy applied with Pressure control mode:-Peak Inspiratory Pressure-28cmH<sub>2</sub>O, Respiratory Rate-26/min, PEEP-8cmH<sub>2</sub>O, FiO<sub>2</sub>-100%, the Tidal Volume was 300 ML, which was almost 5.5 ML/Kg (Her Predicted Body Weight was 54.7 Kg). Sedation and Analgesia initiated via an infusion pump and Neuromuscular Blocking agent PRN. The ABG was taken after one hour of ventilation which revealed moderate respiratory acidosis (PH-7.23, PaCO<sub>2</sub>-72mmHg PaO<sub>2</sub>-90 mmHg).

**Figure-3**  
Chest X ray after one hour of Invasive Mechanical Ventilation



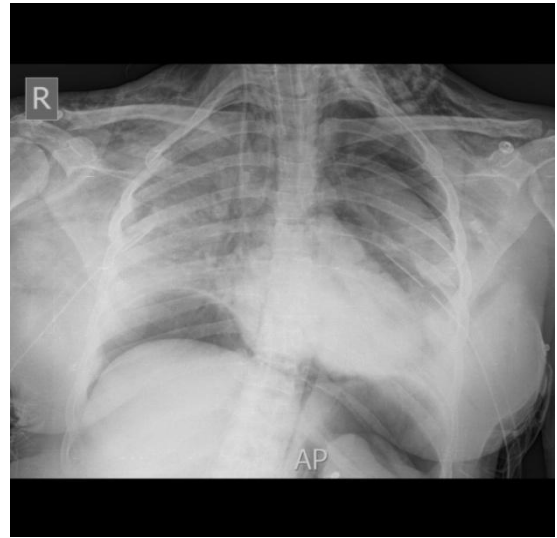
Respiratory rate was increased from 26 to 28/min .After 2 hour she had developed hypotension and desperate breathing on ventilator, ventilator was alarming high peak pressure and tidal volume had reduced 160-180ml, Vasopressor support initiated and ABG was repeated which revealed Severe Respiratory Acidosis (PH-6.85, PaCO<sub>2</sub>-154mmhg, PaO<sub>2</sub>-103 mmhg). Her chest expansion was reduced on inspection and subcutaneous Emphysema was noted during palpation on both sides of base of neck and suprasternal region. Urgent chest x ray was done which revealed bilateral extensive Pneumothorax with both lungs collapsed, Pneumomediastinum and Pneumoperitonium.

**Figure-4**  
Chest X ray after 3 hrs of Invasive Mechanical Ventilator



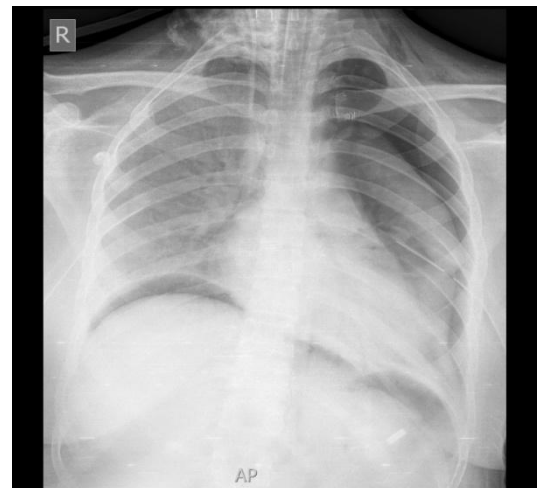
Bilateral Intercostals Drains were inserted and were connected to the underwater seal drainage.

**Figure-5**  
Chest x ray after insertion of bilateral chest tubes



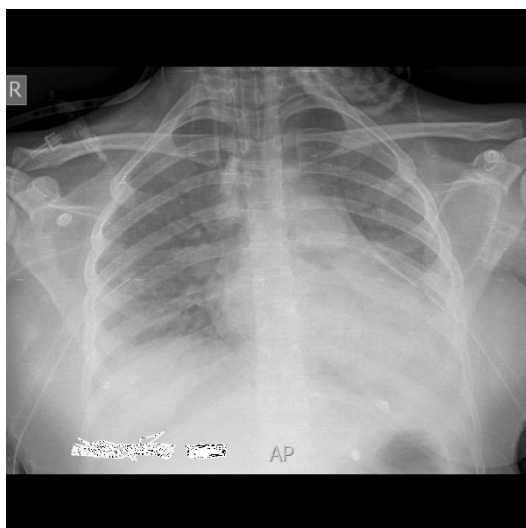Over next 24 hours the right lung was expanding, resolving Pneumothorax and Pneumoperitonium, the patient's ventilation and oxygenation was improving but PaO<sub>2</sub>/ FiO<sub>2</sub> was still <150.

**Figure-6**  
Chest x ray expanding right lung and resolving Pneumothorax



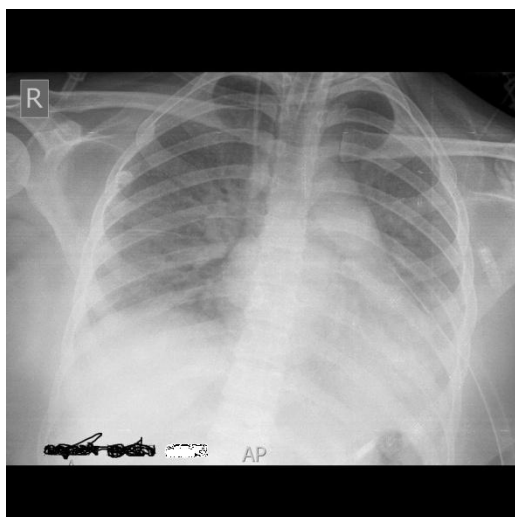
On day 7th, the right lung expanded very well, Right chest tube was removed; patient still remains sick, on vasopressor support and PaO<sub>2</sub>/FiO<sub>2</sub> ratio dropped to 110

**Figure-7**  
**CXR expanded right lung resolved**  
**Pneumoperitonium and resolving**  
**Pneumothorax**



On day 8th, both lungs expanded well, resolved Pneumothorax and Pneumoperitonium but the patient was developing metabolic acidosis and going towards Multi-organ Dysfunction Syndrome despite of improving radiological feature of chest.

**Figure-8**  
**CXR, well expanded both lungs and after**  
**removal of right chest tube.**



Unfortunately the patient had developed Multi-organ failure due to biotrauma and could not survive.

## DISCUSSION

The main determinant of VILI is lung regional over distension of alveoli and disruption of alveolar-capillary interface (14) resulting from the application of a high inflation volumes are more marked in infiltrative lung disease like pneumonia and ARDS because the inflation volumes are distributed preferentially to region of normal lung function.

**Many factors contribute to the development of VILI:** the type, duration and intensity of physical forces generated by the ventilation (volume and pressure) as well as the cause, timing of lung injury and the general progression of the disease, and a large number of trials reported the clinical efficacy of a “protective ventilatory strategy” (3, 10) based on the reduction of tidal volume to 6 ml/kg of ideal body weight and the limitation of end-inspiratory pressure to 30cmH<sub>2</sub>O, but still this is desperate method in case of Severe ARDS due to Pneumocystis Jiroveci Pneumonia and the mortality is still high despite using lung protective ventilator strategy (17-20).

**Protective Ventilatory Strategy - Low-Volume Ventilation:** Concern for the risk of lung injury during conventional, high – volume ventilation promoted clinical studies evaluating lower tidal volumes during mechanical ventilation, mostly in patients with ARDS. The largest study to date included over 800 patients with ARDS (3, 10), and compared ventilation with tidal volume of 6ml/ kg and 12ml/kg using predicted body weight (which is the weight at which lung volumes are normal). Ventilation with low tidal volumes was associated with a shorter duration of mechanical ventilation and 9% (absolute) reduction in mortality.

**Ultra-Protective Ventilatory Strategy:** Extracorporeal life support (ECLS) techniques, such as extracorporeal membrane oxygenation (ECMO) or

extracorporeal CO<sub>2</sub> removal (ECCO<sub>2</sub>R), are known to provide adequate gas exchange in patients with ARDS (15, 16). Vast improvements in ECLS technology over the last decade have made these devices less invasive, more biocompatible, and easier and safer to use. Moreover, ECLS can facilitate the use of 'ultra' protective mechanical ventilation (e.g., employing tidal volume < 6 ml/kg PBW lower airway pressures) in patients supported with ECLS, minimizing the risk of VILI. More radically, patients supported with ECLS may not require intubation or invasive mechanical ventilation at all: no ventilation, no VILI.

### CONCLUSION

Mechanical ventilation is the most important treatment for acute lung injury and acute respiratory distress syndrome. From a theoretical perspective, all patients receiving ventilator support should benefit from non-injurious strategies. It is advisable for clinicians to integrate physiological principles with clinical data through a 'running assessment' of respiratory mechanics at the bedside so useful to contain VILI by the early identification of specific lung alterations and the resulting most-protective ventilatory strategy.

The development of methods for measuring the aerated lung volume at bedside could allow for individual adjustments of tidal volume. Importantly, tidal volumes in the same order of magnitude should probably be used in patients with so-called normal lungs in order to prevent the development of an ARDS, particularly if a systemic insult is associated. The EOLIA trial (ECMO to rescue lung Injury in severe ARDS; ClinicalTrials.gov NCT01470703) is going to evaluate the impact of ECMO, instituted early after the diagnosis of ARDS not evolving favourably after 3–6h under optimal ventilatory management and

maximum medical treatment, on the morbidity and mortality associated with this disease, whereas the SUPERNOVA trial (A Strategy of Ultra Protective lung ventilation with Extracorporeal CO<sub>2</sub> Removal for New-Onset moderate to severe ARDS; ESICM trial group registration ongoing) will evaluate whether a strategy of enhanced lung-protective (lower tidal volume and lower pressure) ventilation, along with control of the ensuing hypercapnia using the latest generation ECCO<sub>2</sub>R devices, will improve clinical outcomes.

### REFERENCE

1. Del Sorbo L, Goffi A, Ranieri VM (2011) Mechanical ventilation during acute lung injury: current recommendations and new concepts. *Presse Med* 40: e569-e583.
2. Dernaika TA, Keddissi JI, Kinasevitz GT (2009) Update on ARDS: beyond the low tidal volume. *Am J Med Sci* 337: 360-367.
3. Wheeler AP, Bernard GR (2007) Acute lung injury and the acute respiratory distress syndrome: a clinical review. *Lancet* 369:1553-1564.
4. Dahlem P, van Aalderen WM, Bos AP (2007) Pediatric acute lung injury. *Paediatr Respir Rev* 8: 348-362.
5. Villar J, Blanco J, Zhang H, Slutsky AS (2011) Ventilator-induced lung injury and sepsis: two sides of the same coin? *Minerva Anesthesiol* 77: 647-653.
7. Ware LB, Matthay MA (2000) The acute respiratory distress syndrome. *N Engl J Med* 342: 1334-1349.
8. Imai Y, Nakagawa S, Ito Y, Kawano T, Slutsky AS, et al. (2001) Comparison of lung protection strategies using conventional and high-frequency oscillatory ventilation. *J Appl Physiol* 91: 1836-1844.
9. Dreyfuss D, Soler P, Basset G, et al. High inflation pressure pulmonary edema: Respective effect of high airway pressure, high tidal volume, and positive end - expiratory pressure. *Am Rev respir Dis* 1988; 137:1159-1164.

10. Timby J, Reed C, Zeilander S, Glauser F. "Mechanical" cause of pulmonary edema. *Chest* 1990; 98:973-979.
11. The Acute Respiratory Distress Syndrome Network. Ventilation with lower tidal volume as compared with traditional tidal volume for acute lung injury and the acute respiratory distress syndrome. *N Engl J Med* 2000; 342 (18):1301-1308.
12. Muscedere JG, Mullen JBM, Gan K, Slutsky AS. Tidal ventilation at low air-way pressure can augment lung injury. *Am J Respir Crit Care Med* 1994; 149:1327-1334.
13. Ranieri VM, Suter PM, Tortorella C, et al. Effect of mechanical ventilation on inflammatory mediators in patients with acute respiratory distress syndrome: A randomized controlled trial. *JAMA* 1990; 282:54-61.
14. Ranieri VM, Giunta F, Suter P, Slutsky AS. Mechanical ventilation as a mediator of multisystem organ failure in acute respiratory distress syndrome. *JAMA* 2000; 284:43-44.
15. Dreyfuss D, Saumon G. Ventilator-induced lung injury: Lessons from experimental studies (State of the Art). *Am J Respir Crit Care Med* 1998; 157:1-30
16. Brodie D, Bacchetta M. Extracorporeal membrane oxygenation for ARDS in adults. *N Engl J Med* 2011; 365:1905-1914.
17. Peek GJ, Mugford M, Tiruvoipati R, Wilson A, Allen E, Thalanany MM et al. Efficacy and economic assessment of Conventional ventilatory support versus extracorporeal membrane oxygenation for severe adult respiratory failure (CESAR): a Multicentre randomized controlled trial. *Lancet* 2009; 374:1351-63.
18. Staikowsky F, Lafon B, Guidet B, Denis M, Mayaud C, Offenstadt G. Mechanical ventilation for *Pneumocystis carinii* pneumonia in patients with the acquired immunodeficiency syndrome. Is the prognosis really improved? *Chest* 1993 Sep; 104 (3):756-62.
19. *Pneumocystis carinii* pneumonia requiring intensive care management: survival and prognostic study in 110 patients with human immunodeficiency virus. Bédos JP, Dumoulin JL, Gachot B, Veber B, Wolff M, Régnier B, Chevret S. *Crit Care Med*. 1999 Jun; 27(6):1109-15
20. Eisner MD, Thompson BT, Schoenfeld D, Anzueto A, Matthay MA; Acute Respiratory Distress Syndrome Network. Airway pressures and early barotrauma in patients with acute lung injury and acute respiratory distress syndrome. *Am J Respir Crit Care Med*. 2002 Apr; 165 (7):978-82
21. Confalonieri M, Calderini E, Terraciano S, Chidini G, Celeste E, Puccio G, Gregoret C, Meduri GU. Noninvasive ventilation for treating acute respiratory failure in AIDS patients with *Pneumocystis carinii* pneumonia. *Intensive Care Med*. 2002 Sep; 28 (9):1233-8