

East African Medical Journal Vol. 94 No. 5 May 2017

"MAXILLARY SINUS -A POISONED CHALICE" - CLEAR CELL ODONTOGENIC MAXILLARY CARCINOMA - A CASE REPORT

M.S. Mathew, PG Resident, H. K. Velankar, Professor, A. A. Saberwal, Assistant Professor, Y. Shetty, Senior Resident and Y. G. Dabholkar, Professor and HOD, Department of ENT, D.Y. Patil Hospital and Research Centre, Nerul, Navi, Mumbai.

Request for reprints to: Dr. M.S. Mathew, B 601, Neel Paradise, Sector 9, Nerul, Navi, Mumbai 400706, Maharashtra, India.

"MAXILLARY SINUS -A POISONED CHALICE "- CLEAR CELL ODONTOGENIC MAXILLARY CARCINOMA- A CASE REPORT

M. S. Mathew, H.K. Velankar, A.A. Saberwal, Y. Shetty and Y.G. Dabholkar

ABSTRACT

Background: Malignant tumours in the nose and paranasal sinuses are challenging problems in the head and neck tumours. They represent the area of greatest histological diversity in the body with every tissue type represented. Clear cell odontogenic carcinoma (CCOC) is a rare neoplasm of the jaws and was first described by two separate groups of researchers, Hansen et al., and Waldron et al., in 1985

Case presentation: We report case of a male with right maxillary tumour. The patient presented with painful swelling over right side of face with mucopurulent nasal discharge on applying pressure over the swelling. The histopathology of specimen taken during total maxillectomy confirmed the diagnosis.

Conclusion: In most cases of maxillary sinus tumours, the medial spread into nasal cavity is seen primarily followed by the superior spread through the infra-orbital canal or the inferior spread, as a result of which nasal blockage, epistaxis, mass or hyposmia are the most common presenting symptoms along with dental symptoms. It is a diagnostic challenge and clinicians should be aware of similar association as it may result in delayed treatment with fatal consequences. Also, Clear cell odontogenic carcinoma is a rare malignant odontogenic neoplasm with benign looking histology. The acknowledgment of this rare tumour and its distinction from other clear cell neoplasms is crucial in establishing the appropriate therapeutic plan.

INTRODUCTION

Malignant tumour in the nose and paranasal sinus are the most challenging of all the head and neck carcinomas. This legion of individual histology with individual natural histories make statistical analysis difficult. The initial symptoms are relatively

innocuous and are habitually ignored as an aftermath patients often present with extensive tumours with significant invasion of important adjacent structures. This report presents, a case of Carcinoma of Maxillary Sinus mimicking Odontogenic infection later proved to be Clear cell odontogenic carcinoma (CCOC). In 1992, it was included

in the World Health Organization (WHO) classification of odontogenic tumours and was defined as a benign neoplasm with a capacity for locally invasive growth, and was considered more aggressive than ameloblastoma.

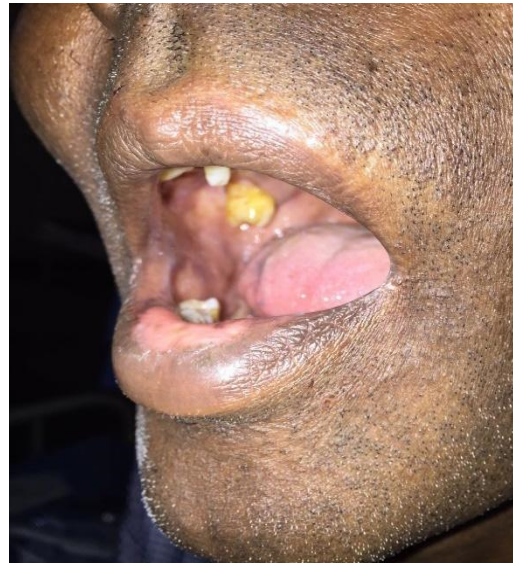
CASE REPORT

A 55 year old male patient presented at our institution with pain and swelling over the right side of the face since 2 months following upper molar tooth extraction on the same side. He also gave history of adjacent three teeth extraction on the same side only to have no significant improvement along with no response to antibiotics after multiple dentist visits. He also complained of mucopurulent nasal discharge on applying pressure over the swelling. Patient did not experience any bleeding/discharge from swelling. His past history was unremarkable except for the addiction of tobacco chewing for 20-25years and a carpenter handicraft. On examination, a diffuse swelling was evident over the mid face extending superiorly from the lower border of the orbit and inferior along the angle of mouth (Figure 1). Skin over the swelling was erythematous, stretched, and shiny. The lesion was bony hard, tender with no local rise of temperature. Intraoral examination revealed a right gingivobuccal obliterated sulcus (Figure 2).

Figure 1
Diffuse swelling over right mid-facial region

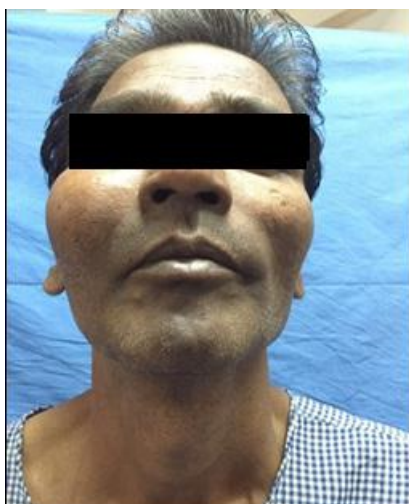

Figure 2
Right Gingivobuccal obliterated sulcus

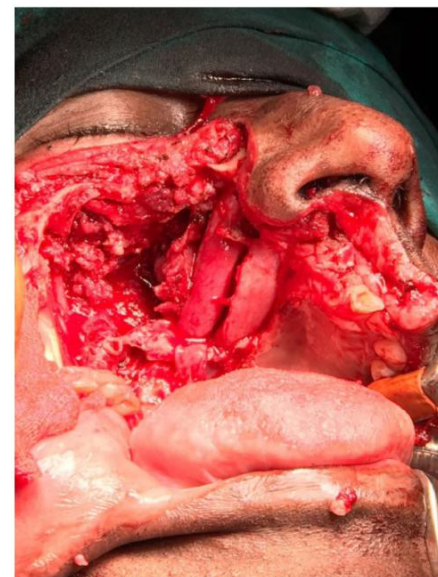


Investigations included a USG guided FNAC through intraoral approach showing malignant epithelial islands in the superficial connective tissue, margins showing severe dysplastic epithelium giving the possible diagnosis Adenocarcinoma . The CT scan of paranasal sinuses and face showed soft tissue mass in right maxillary, ethmoid, sphenoid and frontal sinus with expansion of the sinuses cortical breach and extension into the pre-maxillary region and right masticator space and extraconal space of right orbit. Right osteomeatal unit widened and blocked with soft tissue extending into the right nasal cavity more likely to represent neoplastic aetiology (Figure 3). However, Histopathology postoperatively was suggestive of Clear cell odontogenic carcinoma.

Figure 3
CT PNS showing soft tissue infiltration & destruction of bony margins

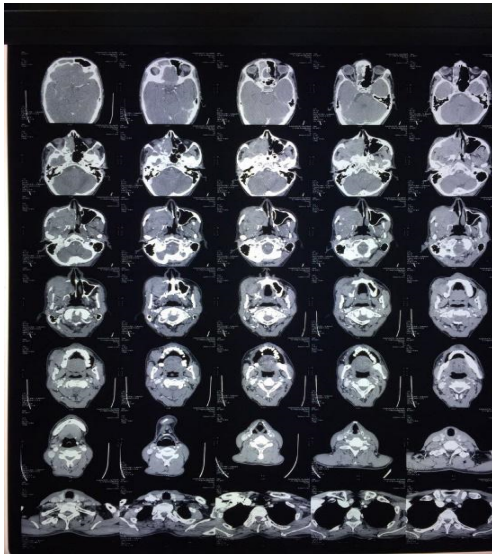

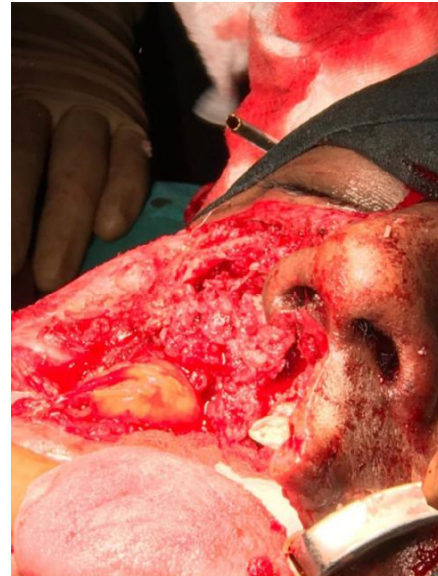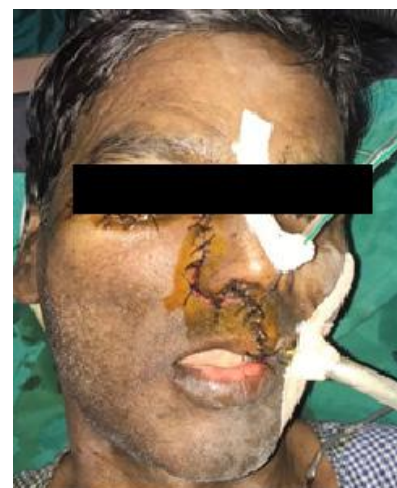Figure 4,5
Intraoperative maxillary mass, post excision of the mass



Surgery remains the first treatment of choice combined with chemotherapy and radiotherapy in advanced disease which is the most common scenario leading to poorer prognosis. The complexity of the anatomy of the maxillary sinus and its proximity to vital structures like eyes, brain and cranial nerves makes the complete surgical removal a challenge leading to even treatment failure (Figure 4,5). Also functional aspects like eyesight and cosmetic aspects do make patients reluctant. In the present case, a combination of surgery and post-operative radiotherapy with reconstruction for function and aesthetics was considered. Excision of lesion with total maxillectomy was performed as per the FNAC report which was suggestive of Adenocarcinoma (Figure 6). But to our surprise the postoperative histopath report was suggestive of Clear cell Odontogenic Carcinoma of the Right maxilla. Patient was discharged with medications and instructions to follow up. Post op radiotherapy was also advised.

Figure 6
Post-operative care



During the follow up visits, the patient had significant improvement and the intra-oral defect was rehabilitated with palatal obturator.

DISCUSSION

Malignant neoplasms of maxillary sinuses are rare (1). Clear cell odontogenic tumour was originally considered a benign, but locally invasive neoplasm. Later on, its local aggressive growth, frequent recurrences, and occasional metastases recorded in several cases led some authors to consider it as an odontogenic carcinoma.

Clear cell odontogenic carcinoma has a female predilection with M/F ratio of 1:1.8 where as carcinoma maxilla has predilection for males (male/female ratio-2.3/1) and majority of cases have been diagnosed in patients older than 40 years. Mean age at the time of diagnosis was 50 years (range 17-89). Mandible was involved in almost 77% cases and maxilla in about 23%. Posterior region of jaws is the more frequent site in comparison to anterior. In only 13% of cases, both anterior and posterior regions of the jaws were involved. The clinical presentation is in most cases of a painless swelling in the mandible or maxilla. Pain and regional teeth mobility are occasionally associated symptoms often misleading as dental infections.

Regarding maxillary sinus carcinomas, the most common risk factors are smoking and history of chronic sinusitis. Other factors including air pollution or occupational exposure to chemical substance such as formaldehyde, chromium, nickel have also been found to be associated with an increased risk for maxillary sinus carcinoma (4). In majority of patients, it is diagnosed in the advanced stages (5,6). The early symptoms being pain followed by oral, nasal obstruction or chronic sinusitis or even lacrimal gland obstructions (7).

The present case reported with pain in relation to decayed tooth, which aggravated and developed into swelling in the right maxillary region following extraction. Carcinoma of maxillary sinus usually presents with nasal obstruction or discharge, epistaxis, epiphora, proptosis, diplopia, orbital pain and sometimes paraesthesia in case of nerve involvement unlike inflammatory lesions of odontogenic origin. When these classic signs are not present, the chance of malignant tumour reduces, our case was detected in its advanced stage wherein none of the above features of carcinoma maxillary sinus was noticed except for non-specific features like pain and swelling (8,9). The reason for delay in clinical symptoms in sinus malignancy is due to the presence of large air space which allows asymptomatic expansion of the tumour. Symptoms are produced only when the malignancy erodes walls of the maxillary sinus showing its dependency on the wall perforated by the disease. If the medial wall of the sinus is eroded nasal obstruction, epistaxis or discharge can occur. Cancer causing erosion of the floor produces dental signs and symptoms like unexplained pain, enlargement of alveolar ridge or palate and loose teeth. When the lesion penetrates the lateral wall, facial and vestibular swellings become apparent (9). Superior extension of the malignancy in the maxillary sinus can result in the displacement or protrusion of the eyeball. Skull base invasion and intracranial extension can cause headache (2).

The site of occurrence of maxillary sinus carcinoma is significant in prognosis and treatment planning. Maxillary sinus can be divided coronally into three zones, suprastructure, mesostructure and infrastructure. Tumours involving mesostructure and infrastructure require partial or total maxillectomy whereas tumours involving suprastructure have poor prognosis and require total maxillectomy. If

orbital periosteum is involved orbital exenteration is needed.

The incidence of lymph node metastasis is low in maxillary sinus carcinoma, but if present it has a poor prognosis. However, invasion of the tumour to the adjacent structures with rich lymphatic network, such as the oral cavity and nasopharynx, increases lymph node metastases (7). Patients with neck metastasis at presentation must undergo a neck dissection. A prophylactic treatment of the neck in patients with N0 (no node involvement) tumours is controversial. Few authors emphasize the indication for prophylactic neck treatment. On the other hand, few with the opposite conclusion, considers it useless to treat the N0 neck (8). Morphological evaluation of lymph node can be done by Ultrasound, CT and MRI, while PET provides metabolic data of the metastatic lymph nodes. CT-PET has shown to have a high sensitivity in diagnosing the primary tumour and regional lymph node metastases. CT with contrast is superior for the evaluation of the bony walls of the maxillary sinus and skull base. The estimation of the tumour vascularity and its relation to the carotid artery can also be done with contrast CT. MRI is superior in distinguishing tumour from adjacent inflammatory disease. However, micro metastases, if present cannot be diagnosed by the above method. With improved imaging technology and superior tumour mapping permits more realistic treatment planning with regard to cure versus palliation.

Surgery remains the primary treatment modality, combined chemotherapy and radiation therapy has a significant role in patients with advanced disease. A majority of maxillary sinus tumours are diagnosed in their advanced stage, leading to poorer prognosis. In the present case, a combination of surgery and post-operative radiotherapy

with reconstruction for function and aesthetics was considered as the treatment.

CONCLUSION

Maxillary sinus carcinomas have a poor prognosis due to the delay in diagnosis and limitations in the treatment because of the close proximity of sinus to the vital structures. The delay in diagnosis may be attributed to the fact that the clinical signs and symptoms of carcinoma of maxillary sinus may masquerade an inflammatory condition. Though rare, Clear cell odontogenic carcinoma should be considered in the differential diagnosis of jaw tumours with conspicuous clear cell component. Curettage or conservative resection inevitably results in recurrences and/or metastasis and more radical resection is warranted in these tumours, especially when they are large and show soft tissue invasion. Early identification of clinically silent malignant neoplasms of sinuses requires highly advanced imaging modalities. Furthermore, as only small number of cases of Clear cell malignant tumours are reported in the literature, long-term follow-up studies might help in understanding the biological behaviour of this tumour.

REFERENCES

1. Ashraf, M., Biswas, J., Dam, A., Bhowmick, A., Jha, J.K., Sing, V., et al. Results of treatment of squamous cell carcinoma of maxillary sinus: A 26-year experience. *World. J. Oncol.* 2010;1:28-34.
2. Som, P.M. and Brandwein, M. Sinonasal cavities. Tumours and tumour like conditions. In: Som PM, Hugh D, editors. *Head and neck imaging.* 4th ed. St. Louis: Mosby Year Book, 2003. Pp.262-71
3. Santos, M.R., Servato, J.P., Cardoso, S.V. et al. Squamous cell carcinoma at maxillary sinus: clinicopathologic data in a single

- Brazilian institution with review of literature. *Int. J. Clin. Exp. Pathol.* 2014;7
4. Won, H.S., Chun, S.H., Kim, B. et al. MS, JH. Treatment outcome of maxillary sinus cancer. *Rare Tumours.* 2009;1:e36:8823- 32.
 5. Bhattacharyya, N. Factors affecting survival in maxillary sinus cancer. *J. Oral. Maxillofac. Surg.* 2003;61:1016–21
 6. Manrique, R.D., Deive, L.G., Uehara, M.A., et al. Maxillary sinus cancer review in 23 patients treated with postoperative radiotherapy. *Acta Otorrinolaringol.* 2008;59:6-10.
 7. Vasudevan, V., Kailasam, S., Radhika, M.B. et al. Well-differentiated squamous cell carcinoma of maxillary sinus. *Journal of Indian Academy of Oral Medicine and Radiology.* 2012;24:250-54.
 8. Hone, S.W., O'Leary, T.G., Maguire, A., Burns, H. and Timon, C.I. Malignant sinonasal tumours: The Dublin Eye and Ear Hospital experience. *Ir. J. Med. Sci.* 1995;164:139-41.
 9. Selden, H.S., Manhoff, D.T., Hatges, N.A. and Michel, R.C. Metastatic carcinoma to the mandible that mimicked pulpal/periodontal disease. *J. Endod.* 1998;24:267- 70.