

East African Medical Journal Vol. 93 No. 1 January 2016

EALES' DISEASE: CASE REPORT

P. W. Atipo-Tsiba, MD, FEBO, Ophthalmology Department-University Hospital of Brazzaville (Congo), F. O. Atipo-Tsiba, Haematology Department-University Hospital of Brazzaville (Congo), Y. Tapsoba, Clinique la Providence-Ouagadougou (Burkina Faso) and B. Ossibi Ibara, Infectious department - University Hospital of Brazzaville (Congo)

P. W. Atipo - Tsiba, Ophthalmology Department, Head of clinic - University Hospital of Brazzaville (Congo), Assistant Professor at Marien Ngouabi University of Brazzaville (Congo), Email: atipo.kani@gmail.com

EALES' DISEASE: CASE REPORT

P. W. ATIPO - TSIBA, F. O. ATIPO-TSIBA, Y. TAPSOBA and B. OSSIBI IBARA

SUMMARY

Eales' disease is a retinal vasculopathy of unknown origin. Ischaemic step associated retinal perivasculitis. Neovascularisation step after the previous one, characterised by vitreous haemorrhage in relation with retinal neo vessels. This observation presents the first reported case of this pathology in Brazzaville. A man of 32 was followed for more than five episodes of vitreous haemorrhage over three years. These episodes had an average duration of two months, inter-spersed with complete clinical silence period of variable duration. During crises, visual acuity was under 2/10, and then it went back up to 10/10 spontaneously. Successive tests were normal: blood count, serologies (syphilis, HIV, Lyme), blood tests (converting enzyme, angiotensin II, calcium), tuberculin skin test, fluorescein angiography (FA), chest x-ray. The last episode was unusual, by the depth of visual impairment (light perception), by the existence of retinal neovascularisation (sea fan aspect). The outcome was favorable after retinal photocoagulation and corticotherapy.

INTRODUCTION

Several factors are involved in Eales' disease (autoimmunity, oxidative stress, Mycobacterium tuberculosis, coagulopathy) (1-3). Symptoms are usually bilateral. Peripheral retinal phlebitis is the first step, then an ischemic step and finally a proliferative step with neo vascularisation (1-4). The elimination of some pathologies is essential (sarcoidosis, syphilis, Lyme, other proliferative retinopathies) (5-7). Corticosteroids and/or immunosuppressives agents are used for peri vasculitis (1, 8, 9). Retinal photocoagulation is the rule in proliferative step. Surgery is indicated in vitreous hemorrhage of more than three months and retinal detachment (2-5, 9-10). This observation presents the first reported case of this pathology in Brazzaville.

CASE REPORT

A patient of 32 years old consulted for floating body (Myodesopsia) on both sides for almost a week, associated with decreased visual acuity forcing him to work stoppage.

He describes five other similar episodes, with an average duration of three months, followed in

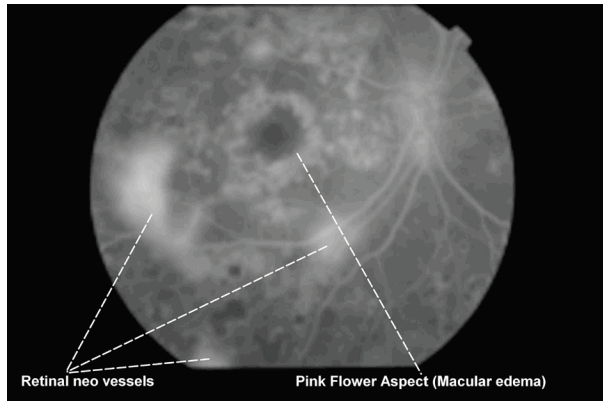
another health centre in Brazzaville, with spontaneous positive development. The cause was never found, no substantive treatment was therefore administered apart from some anti-inflammatory eye drops. Consulting his medical records, we found that during crises, visual acuity was under 2/10, and clinical recovery was complete each time with a final visual acuity at 10/10 without sequelae outside a discrete vitreous condensation. In addition, haematology review and others biological tests (complete blood count, erythrocyte sedimentation rate, syphilis serology, HIV serology, tuberculin skin test, FA) were normal.

His examination (both sides) at admission noted: visual acuity reduced to light perception, mild vitreous haemorrhage, and important retinal neovascularisation.

We achieved the basic laboratory tests as before, extending it to include some tests to rule out mellitus (blood sugar rate), Lyme's disease (Lyme serology), sarcoidosis (blood rate of converting enzyme and angiotensin II, blood calcium rate), Vogt-Koyanagi-Harada's syndrome (HLA DR1, HLA-DR4), and coagulation disorders (Von Willebrand's disease, Thrombocytopenia, Haemophilia). This assessment was normal. The chest x-ray was also normal.

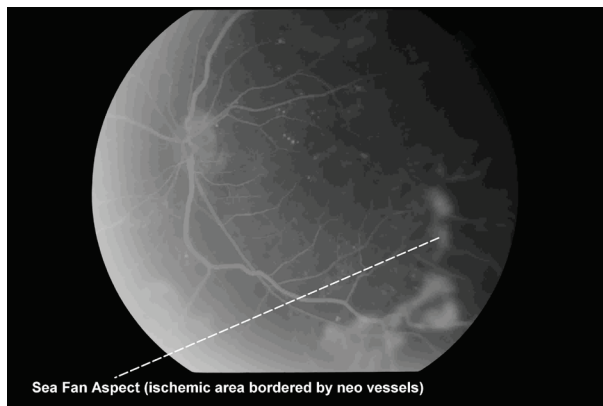
The FA showed on both eyes multiple retinal neo vessels. Macular oedema on right eye with a typical "pink flower petal" aspect (Figure 1).

Figure 1



On left eye a typical "sea fan" aspect, witness of a large ischaemic retinal area bordered by an important neovascularisation (Figure 2).

Figure 2



Eales' disease diagnosis had been selected based on the following arguments:

- recurrent vitreous haemorrhage and spontaneous resolution repeatedly;
- elimination of the following diseases: sarcoidosis, branch occlusion of the central retinal vein and other proliferative retinopathies;
- "Sea fan" aspect that is typical of Eales' disease. This patient received the following treatment:
- four sessions per eye of retinal photocoagulation, one session a week. Laser parameters were: power 275 mW; impact diameter 200 μ ; number of impacts 700 per session;
- an under Tenon injection of Triamcinolone Acetonide (1.5ml). After 5 months of follow-up, the last examination has noted:
- visual acuity 8/10 on both sides
- retinal hypo pigmented scars sequelae of laser

impacts (Figures 3 and 4).

Figure 3

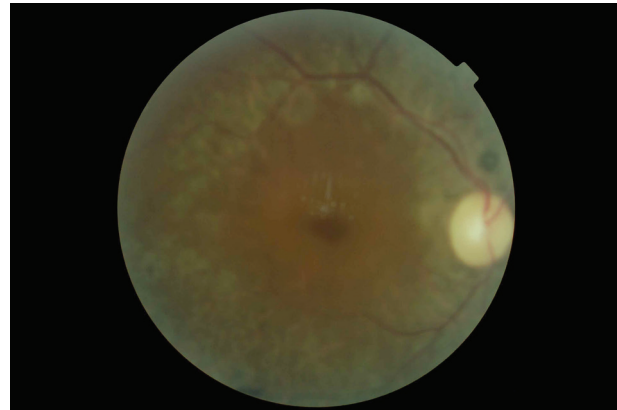
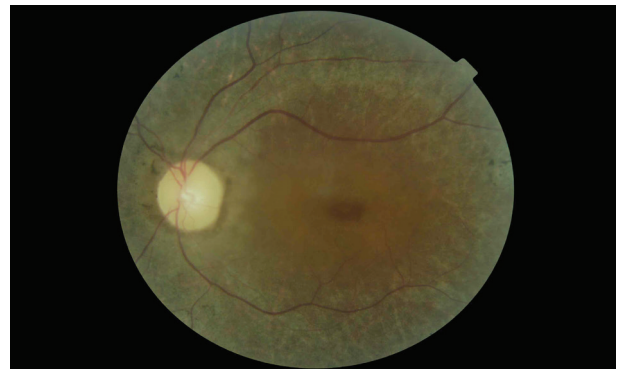
Figure 4



DISCUSSION

The exact etiology of Eales' disease is unknown. Clinical and basic research in recent years has provided important elements for understanding the etiology of this pathology. In particular, HLA antigens study, retinal immunity, Mycobacterium tuberculosis genome *in vitreous*, and anormal high rate of free radicals mediators in vitreous (2, 8).

This pathology presents initially as a retinal perivasculitis affecting preferentially the periphery of the retina. Then, sclerosis of retinal vein leading retinal ischaemia, responsible of retinal and/or pre papillary neovascularisation with or without retinal detachment (1, 3, 10).

At the initial step, patients are often asymptomatic. Some patients may present myodesopsia, blurred vision or even a significant visual loss due to a massive vitreous haemorrhage. Visual acuity can range from a normal value even a simple light perception (2-5). Anterior uveitis is rare; it is non-granulomatous without hypopion. The fundus may show very different aspects depending on the step. Recurrent vitreous haemorrhage is typical of Eales' disease. Macular involvement is quite rare, macular oedema is the most common lesion (2, 9, 10). Peripheral

neo vascularisation of retina is common, while pre papillary neo vessels are rare. Although it is not always necessary routinely to identify all cases of Eales' disease, FA is particularly useful at the step of ischaemia to define areas of non-capillary perfusion, easy diagnosis of retinal and/or pre papillary neo vessels, and macular oedema. Neo vascularisation can be characteristic, showing a typical "sea fan" aspect. FA is also useful to define and locate ischaemic areas that will be treated by laser photocoagulation. At follow-up, it also helps to judge the effectiveness of photocoagulation and the need for a new treatment (4, 8-10). Ultrasound is used for the diagnosis of a possible retinal detachment in the case of cataracts or massive vitreous haemorrhage.

The management of Eales' disease depends on the clinical step (2-4, 8-10). At the step of perivasculitis, oral or topical (periocular) steroids treatment is the rule. In case of neovascularisation, laser photocoagulation must be performed. Vitreous surgery is indicated in two cases, lasting vitreous haemorrhage (over three months) and retinal detachment. The role of hyperbaric oxygen therapy and tuberculosis treatment remains questionable. There are no specific recommendations for doses of oral corticosteroids at the step of retinal vasculitis. The dosage should be individualised for each patient depending on the severity of inflammation (number of retinal quadrants involved). In most cases, oral Prednisolone at 1 mg/kg is required. The dose is reduced by 10 mg per week of 6 to 8 weeks. If macular edema is associated, periocular injection of corticosteroids can be used. In case of no response or absolute prohibition of corticosteroid therapy, the use of immuno-suppressive agents such as Cyclosporine or Azathioprine is recommended. Transscleral cryotherapy is sometimes used in cases of important cataract or massive vitreous haemorrhage.

Related blindness Eales' disease is rare. Vitreous haemorrhage frequently resolve within four to eight weeks spontaneously, but may also persist, organise and form multiple vitreoretinal traction and causing retinal detachment (7, 9).

Eales' disease can mimic many other ocular and systemic disorders presenting as retinal vasculitis or

vascular proliferative retinopathy. Immunological, biochemical and molecular biology are in favour of a multifactorial etiology. HLA Group, retinal autoimmunity, Mycobacterium tuberculosis genome and free radicals mediators play a role in the pathogenesis of this pathology.

REFERENCES

1. Das T, Pathengay A, Hussain N, Biswas J. Eales' disease: diagnosis and management. *Eye (Lond)*. 2010;**24**:472-482.
2. Bharathselvi M, Biswas J, Selvi R *et al*. Increased homocysteine, homocysteine-thiolactone, protein homocysteinylated and oxidative stress in the circulation of patients with Eales' disease. *Ann Clin Biochem*. 2013;**50**:330-338.
3. Rajpal, Singh UB, Mohapatra S, Wagh VK, Porwal C, Kaushik A. Association of mycobacterium tuberculosis in the causation of Eales' disease: An institutional experience. *Indian J Med Microbiol*. 2015;**33** **Suppl**:S43-S45.
4. Cp J, Al G, Jd L. Combination of intravitreal bevacizumab and peripheral photocoagulation: an alternative treatment in eales disease. *Med Hypothesis Discov Innov Ophthalmol*. 2013;**2**:30-34.
5. Adil B, Rajaa D. Eales disease: no typical clinical presentation. *Pan Afr Med J*. 2014 **26**:17:136.
6. Murugeswari P, Shukla D, Kim R, Namperumalsamy P, Stitt AW, Muthukkaruppan V. Angiogenic potential of vitreous from Proliferative Diabetic Retinopathy and Eales' Disease patients. *PLoS One*. 2014;**9**:e107551.
7. Khanduja S, Gupta S, Sinha S, Venkatesh P, Vohra R, Garg S. Surgical outcomes of minimally invasive vitrectomy surgery in Eales' disease. *Nepal J Ophthalmol*. 2013;**5**:182-189.
8. Cai SJ, Su G, Li H, Xie B, Luo JM. Profiling of human leukocyte antigens in Eales disease and tuberculosis. *Int Ophthalmol*. 2013;**33**:475-479.
9. Fung AT, Nicolò M, Yzer S, Traverso CE, Yannuzzi LA. Eales disease associated with serpiginous choroiditis. *Arch Ophthalmol*. 2012;**130**:1484-1486.
10. Saxena S, Pant AB, Khanna VK, Singh K, Shukla RK, Meyer CH, Singh VK. Tumor necrosis factor- α -mediated severity of idiopathic retinal periphlebitis in young adults (Eales' disease): implication for anti-TNF- α therapy. *J Ocul Biol Dis Infor*. 2010;**3**:35-38.