

*East African Medical Journal Vol. 92 No. 6 June 2015*

#### OPERATIVE MANAGEMENT OF ANKLE FRACTURES DURING PREGNANCY: CASE SERIES

F. C. Sitati, MBChB, MMed, FCS (ECSA), Lecturer, Department of Orthopaedic Surgery and R. J. Kosgei, MBChB, MMed, MSc, Lecturer, Department of Obstetrics and Gynecology, College of Health Sciences, University of Nairobi, P.O. Box 19676-00202, Nairobi, Kenya

## OPERATIVE MANAGEMENT OF ANKLE FRACTURES DURING PREGNANCY: CASE SERIES

F. C. SITATI and R. J. KOSGEI

### SUMMARY

**Trauma affects approximately 5% of pregnancies and is the leading non-obstetric cause of maternal death. Ankle fractures occurring in pregnancy although minor, can nonetheless create diagnostic and therapeutic challenges for the patient and the surgeon. There is limited information on the operative management of ankle fractures during pregnancy in literature. We retrospectively reviewed hospital records of pregnant patients with ankle fractures who underwent surgery over a six month period from January to June 2013 in a private hospital in Nairobi. We present four cases of displaced ankle fractures in pregnancy that were fixed with good pregnancy outcomes. These case series highlight the management considerations of ankle fractures in pregnant women whose time to delivery is more than six weeks.**

### INTRODUCTION

Approximately 5% of pregnant women experience various degrees of trauma (1). Trauma in pregnancy, is the leading cause of non-obstetric death with an overall mortality rate of up to 7% (2). Ankle fractures occurring in pregnancy although minor can create a diagnostic and management challenge (3). Use of radiograph to confirm the diagnosis, poses a risk of radiation exposure to the fetus, though with lead shielding the risk is reduced. The risk of operative stress during surgery to both the mother and fetus is another challenge (2). Adverse pregnancy outcomes such as abruption placenta, preterm birth and foetal death may occur even in minor trauma in these patients (4). The main causes of ankle fractures are motor vehicle accidents, falls and assault (5). There is a paucity of data on the operative management of ankle fractures in the pregnant patient. These case series highlights management considerations of ankle fractures in a pregnant patient, whose time to delivery is more than six weeks.

### CASE SERIES PRESENTATIONS

We present four cases of pregnant women with ankle fractures between January and June 2013 managed operatively during pregnancy. For all the patients, a written informed consent was obtained for surgery as well as publication. All the patients in our series had no significant past medical or surgical history

or allergies. All initial radiographs were done before referral to our hospital, and whether or not lead shielding was used could not be ascertained. Obstetric ultrasounds were normal for all the patients.

Pre-loading with one litre of normal saline and one gram ceftriaxone prophylactic antibiotics were given. All surgeries were under spinal anaesthesia using 3cc mercaine, with the patient in the left lateral decubitus position. In all cases, intra-operative foetal heart monitoring was done with a pinard foetoscope, due to lack of continuous foetal heart rate monitoring equipment. Post-operatively the patients were mobilised first on non-weight bearing for six weeks, then weight bearing as tolerated for two weeks and thereafter full weight bearing. Lead shielding was used to reduce radiation exposure to the foetus in all post-operative follow up radiographs. Pethidine and Paracetamol were given for post-operative analgesia. In our series, to reduce the risk of deep venous thrombosis, aspirin 75 mg was used for anti-coagulation because of the prohibitive cost of low molecular heparin. In addition, all patients were mobilised on the first post-operative day and encouraged to do regular knee and foot exercises on the injured side.

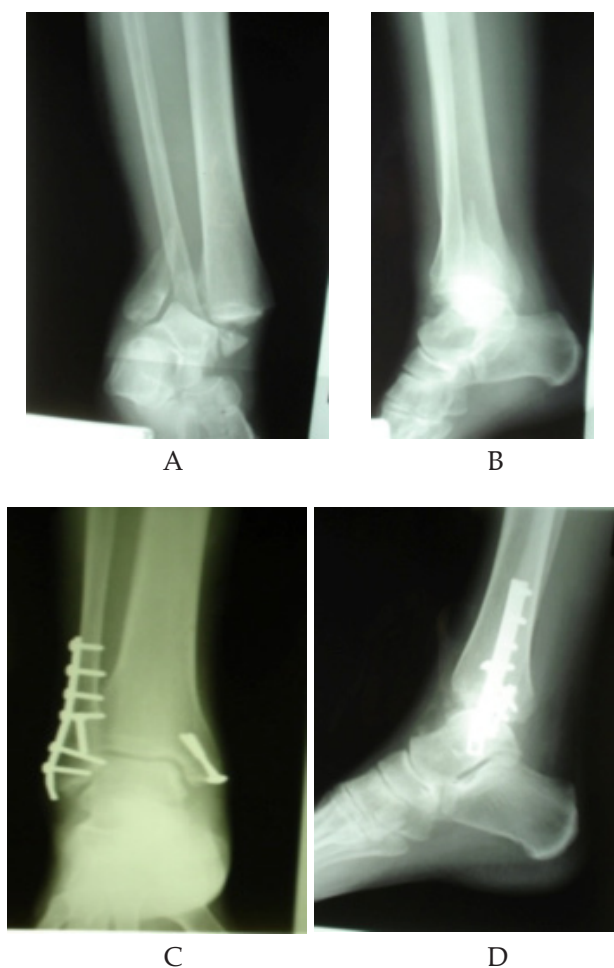#### *Patient 1: Displaced bimalleolar Ankle Fracture*

A 22 year old at 28 weeks gestation of pregnancy was involved in a road traffic accident. She was a passenger on a motor cycle that was hit by a car. She sustained a closed right bimalleolar ankle fracture (Figure 1.A

and B). She was referred to our hospital having been treated with analgesics and a plaster backslab for one week in another facility. Open reduction and fixation with plates and screws was done (Figure 1.C and D). She had an uneventful post-operative period and started full weight bearing two months post surgery. She had spontaneous vertex delivery at 40 weeks gestation to a healthy infant.

Figure 1

*Bimalleolar ankle fracture. Pre-operative anteroposterior (A) and lateral (B) radiographs of the right ankle. Immediate post-operative anteroposterior (C) and lateral (D) radiographs*

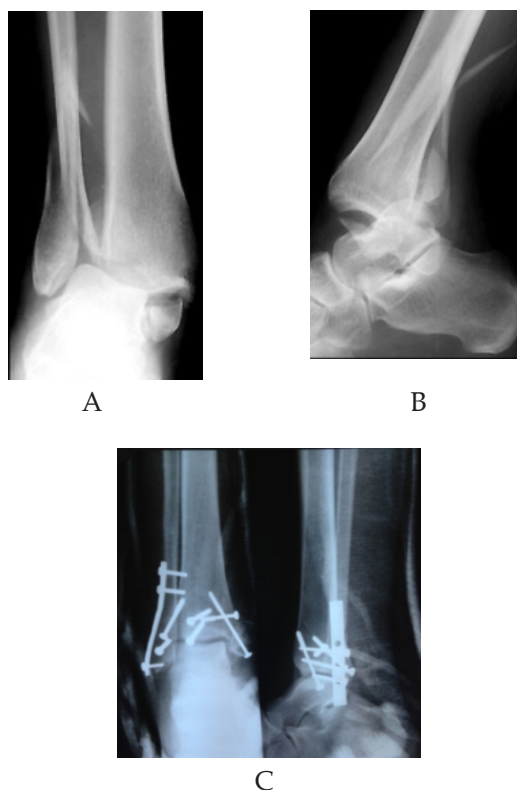


*Patient 2: Displaced Trimalleolar Ankle Fracture.*

A 27 year old female at 20 weeks gestation of pregnancy who presented with a displaced right trimalleolar fracture three days after a fall (Figure 2 A and B). She underwent fixation of the ankle fracture and had an uneventful post-operative period (Figure 2 C). She started full weight bearing at six weeks. She had spontaneous vertex delivery at 40 weeks gestation to a healthy infant.

Figure 2

*Trimalleolar ankle fracture. Pre-operative anteroposterior (A) and lateral (B) radiographs of the right ankle. Immediate post-operative anteroposterior and lateral (C) radiographs*



*Patient 3: Displaced Bimalleolar Ankle Fracture*

A 30 year old female at 30 weeks gestation of pregnancy who fell on a slippery surface and landed on her right foot. She sustained a displaced right bimalleolar ankle fracture. She was seen one week later in our hospital. She underwent ankle fixation and had an uneventful post-operative period. She started full weight bearing at six weeks. She had spontaneous vertex delivery at 39 weeks gestation to a healthy infant.

*Patient 4: Displaced lateral malleolar ankle fracture.*

A 32 year old female at 28 weeks gestation of pregnancy who fell on a flight of stairs and landed on her left foot. She sustained a displaced left lateral malleolar ankle fracture. She was admitted on the same day. She underwent ankle fixation and had an uneventful post operative period. She started full weight bearing at six weeks. She had spontaneous vertex delivery at 39 weeks gestation to a healthy infant.

## DISCUSSION

Trauma sustained during pregnancy is a cause of great uncertainty and anxiety for the patient, obstetrician

and orthopedic surgeon. Even with minor trauma, pregnant women experience a significant increase of adverse pregnancy outcomes (3). In many cases, it is recommended where feasible, to delay surgery in pregnant patients until the post-partum period. This is because of the inherent risk of adverse outcome in the peri-operative period (4). However in the patients presented in this series, the fractures were displaced, and differing surgery to post-partum period could increase the risk of early post-traumatic ankle arthritis.

A multidisciplinary team of an orthopedic surgeon, obstetrician, anaesthesiologist and neonatologist is required for optimum management of trauma in pregnancy. Though none of our patients had unstable vital signs after sustaining their injuries, prompt and effective resuscitation of the pregnant patient is the first management step. Management thereafter should be dictated by a balance between maternal and foetal well being (6). Collimation and shielding should be done when radiographs are taken in pregnancy to reduce radiation exposure to the fetus (7). Obstetric review is a necessary part of management for pregnancy related complications (8). In our series, all patients had a pre-operative obstetric review and obstetric ultrasound done.

Many studies show that regional anaesthesia is safe and effective in pregnancy. Spinal anaesthesia specifically, is associated with less foetal drug exposure and reduced foetal heart rate variability compared to general anaesthesia (8, 9). The left lateral decubitus position is recommended during surgery to reduce aorto caval compression. A purely supine position must be avoided at all times (3). Cephalosporins are considered safe in pregnancy and can be used for antibiotic prophylaxis (3). For patients who are allergic to penicillin's, clindamycin is a safe alternative. Pain control using pethidine is safe in pregnancy and patients can be discharged home on oral codeine. NSAIDs are to be avoided due to the premature closure of the ductus arteriosus as well as the potential risk of birth defects (10).

There is currently no specific guideline on intra-operative foetal monitoring due to inadequate data on its benefits (11). In the setting of trauma in pregnancy with features of foetal distress, Morris *et al.* recommends emergency Caesarian section if the foetal heart rate is less than 100 beats per minute and /or prolonged decelerations if foetus is less than 26 weeks gestation (12).

There is a risk of deep venous thrombosis in pregnancy and therefore prophylaxis is recommended (13). Low molecular weight heparin is recommended for anti-coagulation. In our series junior aspirin was used due to the prohibitive cost of low molecular weight heparin. In addition early mobilisation and regular knee and foot exercises on the injured side

have been shown to reduce the risk of deep venous thrombosis (14).

In conclusion, our series suggests successful operative ankle fracture management is possible in displaced ankle fractures where time to delivery is more than six weeks. A multidisciplinary team approach is essential for optimal pregnancy outcomes. Analytical studies to determine the efficacy and safety of this approach are needed.

## REFERENCES

1. Mattox KL, Goetzl L. Trauma in pregnancy. *Crit Care Med.* 2005; **33**(10 Suppl):S385-389.
2. Sorbi F, Sisti G, Di Tommaso M and Fambrini M. "Traumatic Tibia and Fibula Fracture in a 36 Weeks' Pregnant Patient: A Case Report." *The Ochsner Journal* 13.4 (2013): 547-549.
3. Schwarzkopf R, Gross SC, Coopersmith A, Gidumal R. Ankle Fracture Surgery on a Pregnant Patient Complicated by Intraoperative Emergency Caesarian Section. *Case Reports in Orthopedics*, vol. 2013:1-4 .
4. Murphy NJ and Quinlan JD. Trauma in pregnancy: assessment, management, and prevention. *Am Fam Physician.* 2014;**90**:717-722.
5. El-Kady D and Gilbert WM *et.al.* Trauma during pregnancy: an analysis of maternal and foetal outcomes in a large population. *Am J Obstet Gynecol.* 2004;**190**:1661-1668.
6. Tsuei BJ: Assessment of the pregnant trauma patient. *Injury.* 2006;**37**:367-373.
7. ACOG committee on Obstetric Practice. ACOG Committee Opinion Number 299. September 2004. Guidelines for diagnostic imaging during pregnancy. *Obstet Gynecol.* 2004; **104**: 647-651.
8. ACOG Committee on Obstetric Practice, "ACOG committee opinion: nonobstetric surgery in pregnancy," *Obstetrics & Gynecology*, vol. 102, no. 2, article 431, 2003.
9. Steinberg ES, Santos AC: Surgical anaesthesia during pregnancy. *Int Anesthesiol Clin* 1990; **28**: 58-66.
10. Nahum GG, Uhl K, Kennedy DL: Antibiotic use in pregnancy and lactation what is and is not known about teratogenic and toxic risks. *Obstet Gynecol.* 2006; **107**: 1120-1138.
11. Cheek TG, Baird E. Anaesthesia for nonobstetric surgery: maternal and foetal considerations. *Clin Obstet Gynecol.* 2009;**52**:535-545.
12. J. A. Morris Jr., T. J. Rosenbower, G. J. Jurkovich *et al.*, "Infant survival after cesarean section for trauma," *Annals of Surgery*, 1996; **223**: 481-491.
13. Robertson L, Greer I. Thromboembolism in pregnancy. *Curr Opin Obstet Gynecol.* 2005; **17**: 113-116.
14. Royal College of Obstetricians and Gynaecologists. Reducing the Risk of Venous Thromboembolism during Pregnancy and the Puerperium. Green-top Guideline No. 37a April 2015. [www.rcog.org.uk/en/guidelines-research-services/guidelines/gtg37a/](http://www.rcog.org.uk/en/guidelines-research-services/guidelines/gtg37a/). Accessed 20<sup>th</sup> April 2015.