

East African Medical Journal Vol. 90 No. 7 July 2013

MOLECULAR CHARACTERISATION OF *ECHINOCOCCUS GRANULOSUS* SPECIES/STRAINS IN HUMAN INFECTIONS FROM TURKANA, KENYA

T. Mutwiri, BSc, Kenya Methodist University, School of Medicine and Health Sciences, Department of Medical Laboratory Sciences, P.O. Box 45240-00100, Nairobi, Kenya, J. Magambo, PhD, Meru University of Science and Technology, P.O. Box 972-60200, Meru, Kenya, E. Zeyhle, MSc, Africa Medical Research Foundation, P. O. Box 27691-00506, Nairobi, Kenya, G.M. Mkoji, PhD, Kenya Medical Research Institute, Centre for Biotechnology Research and Development, P.O. Box 19464-00202, Nairobi, Kenya, C. N. Wamae, PhD, E. Mulinge, MSc, C. Mbae, MSc, Kenya Medical Research Institute, Centre for Microbiology Research, P.O. Box 19464-00202, Nairobi, Kenya, H. Wassermann, PhD, Parasitology Unit, University of Hohenheim, 70599 Stuttgart, Germany, P. Kern, PhD, Centre for Internal Medicine, University Hospital, 89081 Ulm, Germany, T. Romig, PhD, Parasitology Unit, University of Hohenheim, 70599 Stuttgart, Germany.

MOLECULAR CHARACTERISATION OF ECHINOCOCCUS GRANULOSUS SPECIES/STRAINS IN HUMAN INFECTIONS FROM TURKANA, KENYA

T. MUTWIRI, J. MAGAMBO, E. ZEYHLE, G.M. MKOJI, C. N. WAMAE, E. MULINGE, C. MBAE, H. WASSERMANN, P. KERN and T. ROMIG

ABSTRACT

Background: Cystic echinococcosis (CE) or hydatid disease is a neglected, economically important zoonotic disease endemic in pastoralist communities, in particular the Turkana community of Kenya. It is caused by the larval stage of the highly diverse species complex of *Echinococcus granulosus sensu lato* (s.l.). The situation on the genetic diversity in humans in Kenya is not well established.

Objective: To characterise *Echinococcus granulosus* (s.l.) species/strains isolated from humans undergoing surgery in Turkana, Kenya.

Design: A Cross sectional study.

Setting: The Kakuma Mission Hospital and Centre for Microbiology Research, Kenya Medical Research Institute

Subjects: Eighty (80) parasite samples from 26 subjects were analysed by Polymerase chain reaction – Restriction fragment length polymorphism (PCR-RFLP) targeting the *nad 1* gene for molecular characterization

Results: Two different genotypes of *E. granulosus* were identified from the samples analysed: *E. granulosus sensu stricto* (G1-G3) 85% of the samples analysed and *E. canadensis* G6/7 (15%). Most of the hydatid cysts (35%) were isolated from the liver. Other sites where cysts were isolated from include: kidney, abdomen, omentum, retroperitoneum and the submandibular. Majority of cysts presented as CE1 (50%) and CE3B (42%) images according to WHO ultrasound classification. Both males and females were infected with *E. granulosus* s.s but only the females showed infection with *E. canadensis* G6/7. Chi-square test revealed significant difference between age of individuals and cysts classification by ultrasound. In addition, there was an association between cyst presentation (single or multiple) and genotype whereby all the *E. canadensis* G6/7 cases presented as single cysts in the infected persons.

Conclusion: This study corroborates previous reports that *E. canadensis* G6/7 strain is present in Turkana, a place where initially only *E. granulosus* s.s (G1-G3) was known to be present and that *E. granulosus* (G1-G3) remains the most widespread genotype infecting humans in the Turkana community.

INTRODUCTION

Echinococcosis is a zoonotic parasitic infection caused by the larval stage (metacestodes) of Echinococcus spp (1). The four main species of medical importance are: *E. granulosus*, *E. multilocularis*, *E. vogeli* and *E. oligarthrus* and each species cause a different disease condition. For instance, infection with the dog tapeworm *E. granulosus*, presents unilocular cysts known as cystic echinococcosis (CE). Infection

with the fox tapeworm, *E. multilocularis*, presents multivesicular cysts known as alveolar echinococcosis (AE), while *E. vogeli* and *E. oligarthrus* both present polycystic forms of echinococcosis (PE) in hosts (2,3,4). CE, caused by *E. granulosus* (s.l.) is the most serious helminthic zoonoses, and is considered an emerging neglected disease throughout the world (5). Human CE is not only a substantial human health problem but also has a considerable economic effect on the livestock industries of some of the most socioeconomically fragile countries (5). At least ten genotypes of *E.*

granulosus are recognised. *E. granulosus* is endemic in Northern Kenya in the Turkana area but very little is known about its epidemiology in the area, in particular the genotypes present. The present study examined molecular characteristics of *E. granulosus s.l* specimens isolated from humans in Turkana.

MATERIALS AND METHODS

Description of the Study area and population: Turkana County is a semi-arid region located approximately 1000 km north-west of Nairobi, Kenya. The Turkana community comprise of Nilotic nomadic pastoralists keeping sheep, goats, cattle, camels and donkeys for their livelihood. Turkana County has one of the highest prevalence rates of cystic echinococcosis in the world (6). According to the office for coordination of humanitarian affairs, Kenya (November, 2012) Turkana is approximately 77,000 km² with the greater Turkana district having a population of 787,659, and the main livelihood of the people in the area is nomadic pastoralism, which accounts for 60% of the population. Rates of 5–10% infection with CE have been recorded, the highest being in the more arid northwest and northeast parts of Turkana (7). CE in this region can be attributed to the domestic cycle due to low frequency of wild animals (8). The high incidence of CE in this area is favored by customs such as keeping dogs, intense contact between man and dog, low hygienic conditions, and home slaughter with no meat inspection (9).

Parasite Specimen: Collection of hydatid cysts was done from patients operated after ultrasound scanning, at The Kakuma Mission Hospital, Turkana West district. These procedures involved use of PAIR (Puncture, aspiration, injection and re-aspiration) and general surgery. *E. granulosus s.l* cyst material/protoscolices were washed and preserved in 70% ethanol and transported to the Kenya Medical Research Institute (KEMRI)'s Centre for Microbiology Research in sterile Falcon tubes, and stored at room temperature waiting further processing and analysis. Single protoscolices, were visualised from a petri-dish using the lower power magnification (X10), and then picked with a 1 µl pipette and transferred to 10 µl 0.02 N NaOH.

DNA extraction and PCR Amplification: DNA was extracted from protoscolices or tissue pieces by lysing in 0.02 M NaOH at 95°C for ten min as previously described by Nakao *et al.*, 2003 (10). The lysate was used directly as templates in a nested PCR targeting the NADH dehydrogenase subunit 1 (*nad-1*) gene as described by Hüttner *et al.*, 2009 (11). The PCR was performed in a 25 µl reaction mixture containing; PCR-Buffer (conc. 10 mM Tris-HCl, pH 8.3; 50 mM KCl), 2 mM MgCl₂, 200 µM of each dNTP, 0.25 µM of each primer, 0.625 U Taq polymerase (Thermo Scientific),

and 1 µl of protoscolex/ tissue lysate (or 1 µl of PCR product). The cycling conditions included 35 cycles of denaturation (94°C for 30 s), annealing (55°C for 30 s), and extension (72°C for one min). These amplification steps were sandwiched by an initial denaturation at 94°C for 5 min and a final elongation at 72°C for five min. The PCR products were visualised on 1.5% agarose gel stained with ethidium bromide.

Restriction fragment length polymorphism (RFLP) of *Nad 1* PCR products: The PCR product was then digested using the restriction enzyme Hph1 (Thermo Scientific) at 37°C overnight as described by Hüttner *et al.*, 2009 (11) with slight modifications. Briefly 20 µl of the total master mix consisted of 10 µl of the PCR product, 2 µl of Buffer B (supplied with enzyme), nuclease free water (7.5 µl) and 0.5 µl of enzyme HphI. The banding pattern was visualised under UV light on a 3% ethidium bromide stained agarose gel. Species/strains were determined by comparing the banding patterns with those of known genotypes (11).

RESULTS

All samples yielded a PCR product with the *Nad 1* gene. The *NAD 1* mtDNA –PCR yielded one amplification product of 1069-1075 bp. The PCR-RFLP patterns, produced after digestion of *NAD 1* fragment with one restriction endonuclease Hph1, are usually different for G1 and G6 sequences. The RFLP patterns after digestion of the mtDNA-PCR amplicons by Hph1 demonstrated three bands for G1 strain.

DISCUSSION

E. granulosus s.s (G1-G3) and *E. canadensis* (G6/7) are currently the only *E. granulosus* strains infecting human in Turkana, Kenya (Table 3). The results of this study suggest that *E. canadensis* G6/7 might have low infectivity to humans as compared to strain G1-G3 (Figure 1). This has also been demonstrated in other studies (12, 13). A different study realised a 9% infection of G6 (camel strain) in human isolates in Iran (14) and later studies have shown that the incidence has been rising since the first G6 infection was reported more than a decade ago. This is the third time the G6/7 strain is being reported in Kenya suggesting that this strain is now established as a human pathogen in the Turkana community. A previous study has recorded 17% of *E. canadensis* G6 infection in Turkana (15) few years after the reporting of the first single case (1/117 -prevalence <1%) of G6 strain was reported in human in the same region (16). Other regions that have reported infections of G6 genotype in human include South America, China, Asia and Africa (16,17,18,19,20,21,15). There has been a high prevalence of the *E. canadensis* G6 in camels in Turkana in the years back, (22) however at this

time there was no known human infection by G6 in that region, since the first infection of human by G6 genotype in Turkana was reported in the year 2004 (16). This finding initiated a shift from earlier

perceptions that there is no evidence of human infections with the camel strain in the Turkana area. This study did not report any mixed infections with *E. granulosus* (G1-G3) and *E. canadensis* (G6/7) in the same individual.

Table 1
Cysts distribution by anatomic location/organ in the study participants

Cyst location	No. of Subjects (%)	Male (%)	Female (%)
Liver	9 (35)	3(11.5)	6 (23.1)
Omentum	6 (23)	2 (7.7)	4 (15.4)
Abdomen	4 (15)	1 (3.8)	3 (11.5)
Kidney	3 (11)	1 (3.8)	2 (7.7)
Abdomen+Liver	2 (8)	1 (3.8)	1(3.8)
Submandibular	1 (4)	0 (0.0)	1 (3.8)
Retroperitonium	1 (4)	0 (0.0)	1 (3.8)
Total	26 (100)	8 (31%)	18 (69%)

Females were infected two times more than males (2:1); two people had the CE cysts infect more than one organ. The Liver was the most infected organ followed by the omentum. There were cases of cysts crossing to infect other organs as realised in the abdomen/liver infections

Table 2
WHO US classification of CE Vs Age of individuals

Class	9-22 yrs (%)	23-36 yrs (%)	37-50 yrs (%)	Total (%)
CE1	7 (26.9)	5 (19.2)	1 (3.8)	13(50)
CE2A	1 (3.8)	0 (0)	1 (3.8)	2 (7.7)
CE3B	0 (0)	1 (3.8)	10 (38.5)	11(42.3)
Total	8	6	12	26 (100)

The CE classifications indicated that the half of the cysts were in active form. Majority of the younger patients presented with cysts within the CE1 classification whereas majority of the older patients presented cysts classified as CE3B. The presentation of cysts by US as CE1, CE2A and CE3B indicates that the cysts were either in the active form or in transition and none was in the inactive form

Table 3
*Genotypes of *E. granulosus* s.l presenting in the Turkana community of Kenya*

Genotype	Male (%)	Female (%)
<i>E. granulosus</i> s.s (G1-G3)	8 (30.7)	14 (53.8)
<i>E. canadensis</i> (G6/7)	0 (0.0)	4 (15.4)
Total	8 (30.7%)	18 (69.2%)

The female patients had a higher rate of infection at 69%; moreover all the *E. canadensis* (G6/7) strains were found infecting the female patients.

Table 4
Chi-square tests of association between age group and US classification among the Turkana

Age	CE1	CE2A	CE3B	Total
9-22	7 (4)	1 (0.6)	0 (3.4)	8
23-36	5 (3)	0 (0.46)	1 (2.54)	6
37-50	1 (0)	1 (0.9)	10 (5.1)	12
Total	13	2	11	26

$\chi^2_{4, 0.05} = 9.488$ $\chi^2 = 17.53$ p-value 0.001

Chi square test between age and Ultrasound classification at 95% CI showed significant difference between age groups and cysts Ultrasound classification.

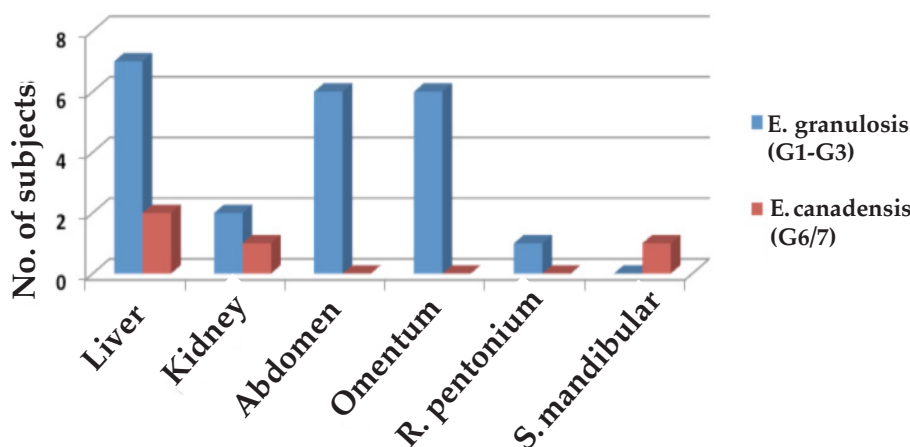
Table 5
Chi square tests of association between cyst type and genotype among the Turkana

Cyst	<i>E. granulosus</i> G1-G3	<i>E. canadensis</i> G6/7	Total
Single	13 (16.15)	4 (0.85)	17
Multiple	63 (59.85)	0 (3.15)	63
Total	76	4	80

$\chi^2_{1, 0.05} = 3.841$ $\chi^2 = 15.38$ p-value 0.0001

Chi-square test for association between cyst type and genotype at 95% CI showed association between genotype of infecting strain and mode of cyst presentation either as a single cyst or multiple cysts in the organs infected.

Figure 1
Echinococcus granulosus strains by infected organ among the Turkana community



E. granulosus s.l. is a complex taxa, and the G1 genotype is generally considered to be the most widespread genotype worldwide, and is the one most commonly involved in CE in humans. However, recent molecular epidemiological studies have revealed that humans can be infected with other genotypes, and that the prevalence of infection with these genotypes is higher than previously thought. *E. ortleppi* (G5 cattle strain), *E. granulosus* (G2 Tasmanian sheep strain), and *E. canadensis* (G6 Camel strain) have been found to infect humans in Argentina (17) and Sudan (23). Recent study in South Africa has indicated human infection with *E. ortleppi* (G5 strain) and the G7 strain of *E. canadensis* (24). Epidemiological evidence from Great Britain suggests that *E. equinus* (G4) may not be infective to humans (25)

Due to lack of well-documented data from many countries, the global picture of the current situation is incomplete. *E. canadensis* G6 (Camel strain) mainly infects camels and in some areas, infects human, as in the present study, however, in Iran it remains restricted in camels (26). There is probability that some genetic

mutations may have arisen in the G6 genotype to make it infectious to human in some regions. It may not yet be clear whether the G6 genotype infection in Kenya is as a result of mutation or not. The G1 genotype infecting human in the People's Republic of China has been reported as diverse (27) and separated into 13 sub-genotypes (G1m1 to G1m13) when identified using *cox1*, *Nad 1* and *atp6* (28). In determining the range of genetic variability within and between genotypes, amplification and partial cloning of *cox1* and *nad1* genes from 16 isolates of *E. granulosus* from four continents was done (29) then followed by sequencing of different clones from a PCR product to analyse the intra-individual genetic variance. The findings showed a moderate degree of variance within single isolates and a significant degree of variance between the cluster of genotypes. In a study of genetic typing of *Echinococcus* spp (30), it is proposed that the sympatric circulation of three *E. granulosus* strains (G1-G3) needs to be investigated to assess the possibility of crossbreeding. Moreover, the remarkably low value of pair-wise divergence

between G6 and G7 suggests that these two genotypes belong to a single species (31). The PCR-RFLP used solely in this study does not show distinction between G1-G3 or G6 and G7 strains, which would require sequencing for specification.

According to WHO Ultrasound classification; (32), the cyst in this study classified as CE1, CE2A and CE3B, (Table 2). Half of the cysts were considered to be in active state (CE1 and CE2A) whereas the cysts that classified as CE3B show that they were in the transitional state. This study did not show any cysts that could be classified as inactive (CE4 and 5)

In conclusion, we note that *E. granulosus* (G1-G3) remains the most wide spread genotype infecting human in the Turkana community. There is enough evidence that *E. canadensis* G6/7 is present in the same community however at a low rate. The female are infected more than the male. There is need to engage available control measures to reduce or eliminate infection rate of human CE and also help curb the emergence of *E. canadensis* G6/7 strain which is continuing to get established.

ACKNOWLEDGEMENTS

Many thanks go to the Deutsche Forschungsgemeinschaft (DFG), German-African Cooperation Projects in infectiology for funding the project and also thanks to The Africa Medical Research Foundation (AMREF) whose staff in the Hydatid Control Programme conducted the PAIR (Puncture, aspiration, injection and re-aspiration) and general surgical procedures at The Kakuma Mission Hospital. This work has been published with permission from the Director, KEMRI

REFERENCES

- Eckert, J., & Deplazes, P. (2004). Biological, Epidemiological, and Clinical Aspects of Echinococcosis, a Zoonosis of Increasing Concern. *Clinical Microbiology Reviews*, **17**(1), 107–135.
- Menezes da Silva (2011) Special article, Hydatid cyst/cystic echinococcosis: anatomical and surgical nomenclature and method to quantify the cyst content solidification. *Chin Med J* 2011;**124**(18):2806-2812
- D'Alessandro, A., & Rausch, R. L. New Aspects of Neotropical Polycystic (*Echinococcus vogeli*) and Unicystic (*Echinococcus oligarthrus*) *Echinococcosis*. *Clinical Microbiology Reviews*, 2008; **21**(2), 380–401.
- Nakao, M., Li, T., Han, X., Ma, X., Xiao, N., Qiu, J., Ito, A. Genetic polymorphisms of *Echinococcus* tapeworms in China as determined by mitochondrial and nuclear DNA sequences. *International Journal for Parasitology*, 2010; **40**(3), 379–385.
- Budke, C. M., Deplazes, P., & Torgerson, P. R. Global Socioeconomic Impact of Cystic Echinococcosis. *Emerging Infectious Diseases*, 2006; **12**(2), 296–303.
- Macpherson CN, Romig T, Zeyhle E, Rees PH, Were JB. Portable ultrasound scanner versus serology in screening for hydatid cysts in a nomadic population. *Lancet*. 1987; **8553**:259–261.
- Macpherson CN, *et al.*, Pastoralists and hydatid disease: ultrasound scanning prevalence survey in East Africa. *Trans R Soc Trop Med Hyg* 1989; **83**:243–247
- Nelson G, Raush R. Echinococcus infection in men and animals in Kenya. *Ann Trop Med Parasitol* 1963; **57**:136–149
- French C, Nelson G, Wood M. Hydatid disease in the Turkana district of Kenya. The background to the problem with the hypotheses to account for the remarkably high prevalence of disease in man. *Ann Trop Med Parasitol* 1982; **76**:425–437.
- Nakao, M., Sako, Y., Ito, A., Isolation of polymorphic microsatellite loci from the tapeworm *Echinococcus multilocularis*. *Infect. Genet. Evol.* 2003;**3**, 159–163.
- Hüttner, M., Siefert, L., Mackenstedt, U., Romig, T., A survey of *Echinococcus* species in wild carnivores and livestock in East Africa. *Int. J. Parasitol.* 2009; **39**, 1269–1276.
- Zhang, L., Chai, J., Jiao, W., Osman, Y., & McManus, D. P. Mitochondrial genomic markers confirm the presence of the camel strain (G6 genotype) of *Echinococcus granulosus* in north-western China. *Parasitology*, 1998; **116**, 29.
- Eckert, J., Prevalence and geographical distribution of *Echinococcus multilocularis* infection in human beings and animals in Europe. WHO informal Consultation on alveolar echinococcosis, 1989; 14–16 August 1989, Hohenheim (WHO/VPH/ECHIN. RES./WP/89.4).
- Harandi, M. F., Hobbs, R. P., Adams, P., Mobedi, I., Morgan-Ryan, U. M., & Thompson, R. C. A. Molecular and morphological characterization of *Echinococcus granulosus* of human and animal origin in Iran. *Parasitology*, 2002; **125**, 367.
- Casulli, A., Zeyhle, E., Brunetti, E., Pozio, E., Meroni, V., Genco, F., & Filice, C. Molecular evidence of the camel strain (G6 genotype) of *Echinococcus granulosus* in humans from Turkana, Kenya. *Transactions of the Royal Society of Tropical Medicine and Hygiene*, 2010; **104**(1), 29–32.
- Dinkel, A., Njoroge, E. M., Zimmermann, A., Wälz, M., Zeyhle, E., Elmahdi, I. E., ... Romig, T. A PCR system for detection of species and genotypes of the *Echinococcus granulosus*-complex, with reference to the epidemiological situation in eastern Africa. *International Journal for Parasitology*, 2004;**34**(5), 645–653.
- Kamenetzky, L., Gutierrez, A. M., Canova, S. G., Haag, K. L., Guarnera, E. A., Parra, A., Rosenzvit, M. C. Several strains of *Echinococcus granulosus* infect livestock and humans in Argentina. *Infection, Genetics and Evolution*, 2002; **2**(2), 129–136.
- Guarnera EA, Parra A, Kamenetzky L, García G, Gutiérrez A. Cystic echinococcosis in Argentina: evolution of metacestode and clinical expression in various *Echinococcus granulosus* strains. *Acta Trop* 2004; **92**:153–9.
- Zhang, W., Joshi DD., & McManus, D. P. Three genotypes of *Echinococcus granulosus* identified in Nepal using mitochondrial DNA markers. *Trans R Soc Trop Med Hyg*. 2000; **94**(3):258-60.

20. Bardonnnet, K., Piarroux, R., Dia, L., Schneegans, F., Beurdeley, A., Godot, V., & Vuitton, D. A. Combined eco-epidemiological and molecular biology approaches to assess *Echinococcus granulosus* transmission to humans in Mauritania: occurrence of the "camel" strain and human cystic echinococcosis. *Trans R Soc Trop Med Hyg* 2002; **96**(4), 383–6.
21. Omer, R.A. Dinkel, A., Romig, T., Mackenstedt, U., Elnahas, A.A., Aradaib, Ahmed I.E., Elmalik, K.H., Adam, A. (2004) Strain characterization of human hydatidosis in Sudan. The proceedings of the 21st International Congress of Hydatidology, Nairobi, Kenya. Grand Regency Hotel, Nairobi, Kenya
22. Wachira. Molecular examination of the sympatry and distribution of sheep and camel strains of *Echinococcus granulosus* in Kenya. *The American Journal of Tropical Medicine and Hygiene*, 48, 473.
23. Omer, R. A., Dinkel, A., Romig, T., Mackenstedt, U., Elnahas, A. A., Aradaib, I. E., ... Adam, A. (2010). A molecular survey of cystic echinococcosis in Sudan. *Veterinary Parasitology*, 1993; **169**(3–4), 340–346.
24. Mogoye, B. K., Menezes, C. N., Wong, M. L., Stacey, S., von Delft, D., Wahlers, K., Freaan, J. First insights into species and genotypes of *Echinococcus* in South Africa. *Veterinary Parasitology*, 2013; **196**(3–4), 427–432. doi:10.1016/j.vetpar.2013.03.033
25. Thompson. The taxonomy, phylogeny and transmission of *Echinococcus*. *Experimental Parasitology*, 2008; **119**, 439.
26. Kia, E., Rahimi, H., Sharbatkhori, M., Talebi, A., Fasihi Harandi, M., & Mirhendi, H. Genotype identification of human cystic echinococcosis in Isfahan, central Iran. *Parasitology Research*, 2010; **107**(3), 757–760.
27. Ma, S., Maillard, S., Zhao, H., Huang, X., Wang, H., Geng, P., Piarroux, R. Assessment of *Echinococcus granulosus* polymorphism in Qinghai Province, People's Republic of China. *Parasitology Research*, 2008; **102**(6), 1201–1206.
28. Tamura, K., Peterson, D., Peterson, N., Stecher, G., Nei, M., & Kumar, S. MEGA5: Molecular Evolutionary Genetics Analysis Using Maximum Likelihood, Evolutionary Distance, and Maximum Parsimony Methods. *Molecular Biology and Evolution*, 2011; **28**(10), 2731–2739.
29. Obwaller, A., Schneider, R., Walochnik, J., Gollackner, B., Deutz, A., Janitschke, K., Auer, H. *Echinococcus granulosus* strain differentiation based on sequence heterogeneity in mitochondrial genes of cytochrome c oxidase-1 and NADH dehydrogenase-1. *Parasitology*, 2004; **128**(05), 569–575.
30. Bart, J., Morariu, S., Knapp, J., Ilie, M., Pitulescu, M., Anghel, A., Piarroux, R. Genetic typing of *Echinococcus granulosus* in Romania. *Parasitology Research*, 2006; **98**(2), 130–137.
31. Varcasia, A., Canu, S., Lightowlers, M., Scala, A., & Garippa, G. Molecular characterization of *Echinococcus granulosus* strains in Sardinia. *Parasitology Research*, 2006; **98**(3), 273–277.
32. WHO Informal Working Group. International classification of ultrasound images in cystic echinococcosis for application in clinical and field epidemiological settings. *Acta Tropica* 2003; **85**: 253–261.