

East African Medical Journal Vol. 90 No. 4 April 2013

#### CALCINOSIS CUTIS – A SERIES OF 59 CONSECUTIVE CASES CONFINED AMONG WOMEN

I. A. Mohammed, MD, Reconstructive Surgeon, J. Schneider, MD, Professor, Department of Pathology, Faculty of Medicine, Addis Ababa University, P. O. Box 9086, Addis Ababa, Ethiopia, R. Schiffer, MD (Obs & Gynae), Medical Director, Attat Hospital, P. O. Box 11, Welkite Gurage Zone, J. Hussein, MD, Pathologist, ALERT-AHRI, T. Hailu, MD, Reconstructive Surgeon, Department of Surgery, Yekatit 12 hospital, M. Eshete, MD, Reconstructive Surgeon, F. Abate, MD, Yekatit 12 Hospital, Reconstructive Surgeon, A. Sabir, General Surgeon, Head of Department of Surgery, Attat Hospital, P. O. Box 11, Wekite and D. Habte, MD, MPH, Assistant Professor, School of Public Health, Addis Ababa University, P. O. Box 9086, Addis Ababa, Ethiopia.

Request for reprints to: Ibrahim Mohammed Ali: ibremom@yahoo.com

### CALCINOSIS CUTIS – A SERIES OF 59 CONSECUTIVE CASES CONFINED AMONG WOMEN

I. A. MOHAMMED, J. SCHNEIDER, R. SCHIFFER, J. HUSSEIN, T. HAILU, M. ESHETE, F. ABATE, A. SABIR and D. HABTE

#### ABSTRACT

**Background:** Calcinosis cutis is the cutaneous deposition of calcium salts. Tumoral Calcinosis is a condition consisting of massive subcutaneous deposits of calcium salts often overlying large joints in otherwise healthy patients.

**Objective:** To describe the characteristics of a series of patients with Tumoral Calcinosis in the Gurage Zone of Central Ethiopia.

**Methodology:** Data was collected from 59 patients who presented with clinical diagnosis of calcinosis cutis around hip region between January 2005 and January 2009.

**Results:** All cases were females, with a mean (standard deviation) age at diagnosis of 50.7(10.8). The duration of illness ranged from one to eighteen years. The cases were distributed in the different villages of Gurage Zone without any sign of clustering of cases. The lesions were localized around hip region on both sides. The patients did not have any related co-morbidity or any history of similar illness among close family members. None of the patients gave history of evident trauma to the site of the lesions. Significant proportion of the patients (53.4%) confirmed to carry water container and/or other goods on their side. Serum Phosphate and Calcium levels in selected patients were within normal limit. Histo-pathological examinations of five cases revealed Calcium deposits in collagenous connective tissue.

**Conclusion:** The lesion was found to be relatively common in the study area and specifically confined to females. The probable factor associated with the cases is carrying objects on their side (hip area). Further research with in-depth clinical and laboratory evaluation is of paramount importance.

#### INTRODUCTION

Calcinosis cutis, a cutaneous deposition of calcium salts, has different forms. The dystrophic variety is characterized by calcium deposition in damaged or degenerated tissue, and the less common metastatic form is associated with elevated serum levels of calcium and/or phosphate. Iatrogenic calcinosis is commonly used for cases that follow the intravenous administration of calcium chloride and calcium gluconate with extravasation. The Idiopathic group is ascribed to presentations with unknown pathogenesis.(1-7)

Tumoral calcinosis is a condition consisting of massive subcutaneous deposits of calcium salts often

overlying large joints in otherwise healthy patients. There is a predilection for black races.(2)

Although calcinosis cutis is reported to be a rare condition, we had the opportunity to diagnose and treat some patients with tumoral calcinosis in the Gurage zone of central Ethiopia (Attat Hospital, Welkite).

We describe the clinical information of 59 cases and histo-pathological findings of selected cases of Tumoral Calcinosis.

#### MATERIALS AND METHODS

The study was conducted in Attat Hospital that is located in Central Ethiopia-Gurage Zone, 187

kms south-west of Addis Ababa. The major health problems encountered in the zone are infectious diseases.

Data was collected from 59 consecutive patients who presented with swelling, pain, and clinical diagnosis of Calcinosis cutis around hip region between January 2005 and January 2009. The clinical diagnosis was confirmed by the treating surgeon in charge of surgical department. A structured questionnaire was utilized to collect the demographic, life style and clinical characteristics of the cases. Clinical chemistry investigations were made among the first three cases. Biopsy was performed to confirm the diagnosis in the first five cases. Laboratory and Pathology investigations were limited to the first few cases due to the unavailability of resources. The investigations made in the first few cases helped to confirm the diagnosis and the subsequent cases were diagnosed clinically.

All patients were treated surgically and the procedure was performed by a General Surgeon. All operated patients were followed up after one week and then informed to report back if there is any complaint including recurrence of swelling.

*Surgical treatment:* under aseptic technique and local anaesthesia, the lesion was excised in toto. In the majority of the cases, the skin was sutured back but in few cases portion of the skin was trimmed and bleeding well secured. Drainage was introduced and removed after 72 hours. All patients had smooth

postoperative course with suture removal on the 10th to the 14th days. None of the operated cases in the current series returned with recurrence during the six month follow up period.

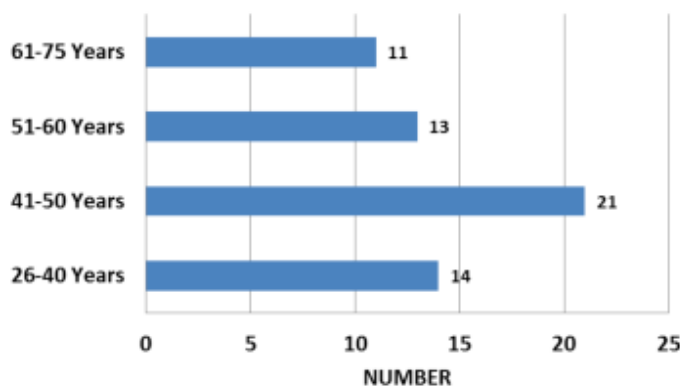
Ethical clearance was obtained from the Health Office and the hospital management approved the conduct of the study. Explanation was given to study participants about the study objectives and procedures, and that their blood and tissue samples will be used for the research purpose only, i.e. to analyse electrolytes and for pathological examination respectively. All study participants read and signed the informed consent before involvement in the study. Study participants were re-assured that their decision not to participate in the study will not affect their right to medical care. For potential participants who were illiterate, the information sheet and the consent form was read to them and the participant's signature and that of an impartial witness was taken.

## RESULTS

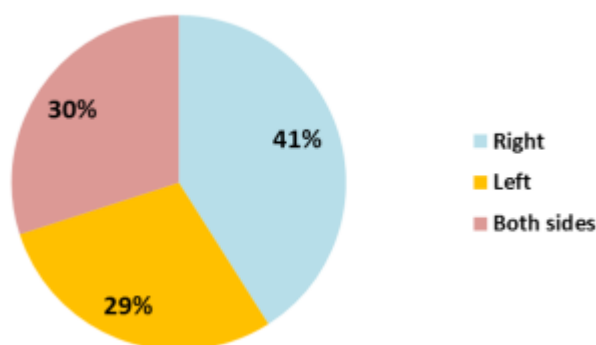
All cases were females, with a mean (standard deviation/ SD) age at the diagnosis of 50.7 (10.8) and range between 26 and 75 years of age. The duration of illness ranged from one to eighteen years, the larger proportion being with symptom duration less than or equal to five years (63.2%). The cases were distributed in the different villages of Gurage Zone without any sign of clustering of cases. The lesions were localized around hip region on both sides. (Figure 1 and 2)

**Figure 1**

*Age distribution of patients with Cutis Calcinosis, Attat Hospital, January 2005-January 2009 (n=59)*



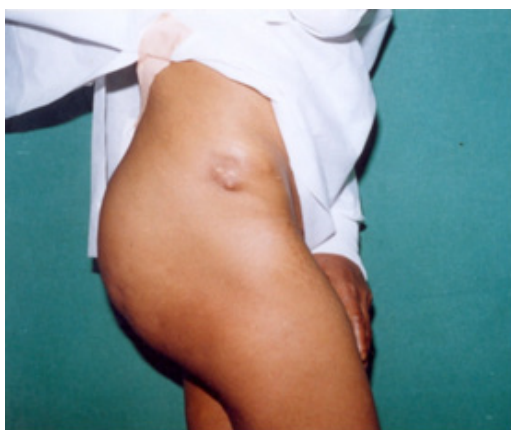**Figure 2**  
*Location of Cutis Calcinosis, Attat Hospital, January 2005-January 2009 (n=59)*



The presenting complaint by the large majority (91.2%) of the patients was pain while 10.3% had ulcerating lesion. Three patients reported to have had herbal treatment before seeking modern health service. All patients except one presented with the problem for the first time. The lesion size measured between 5cm and 12 cm in diameter (Figure 3).

patients (53.4%) confirmed to carry water container and/or other goods on their side, the traditional way in the area (Fig 4). Serum phosphate level in two patients was found to be within the normal range and in one patient was a little above the upper border. In three of these cases, calcium level was within normal range.

**Figure 3**  
*Clinical appearance of the lesion*



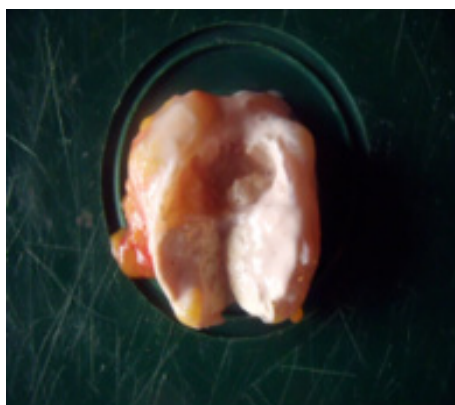
Clinical and laboratory examination revealed no sign of parasitic or systemic diseases which could be considered as related co-morbidity. Neither was any history of similar illness among close family members. None of the patients gave history of evident trauma to the site of the lesions. Significant proportion of the

**Figure 4**  
*The typical way of carrying a pot in the area*

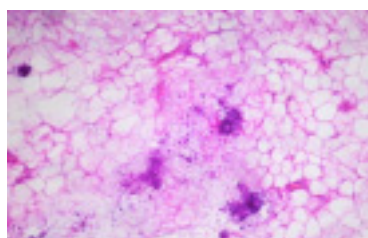


Gross appearance of the lesion showed well delineated sub-cutaneous grey white solid tissue with chalky white solid on the cut surface. Histo-pathological examinations of five cases revealed Calcium deposits in collagenous connective tissue (Figure 5-8).

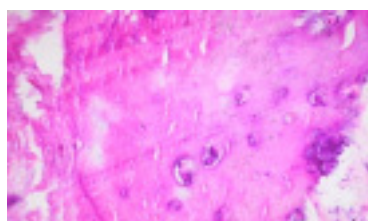
**Figure 5**  
Gross appearance of the lesion



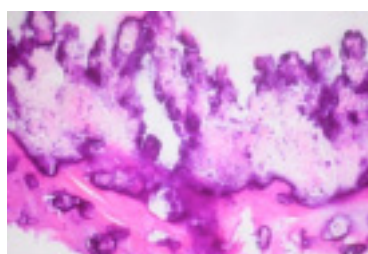
**Figure 6**  
Subcutaneous adipose tissue with minor calcium incrustation (Hematoxylin-Eosin stain HE, original magnification 200x)



**Figure 7**  
Calcium deposits in collagenous connective tissue (HE, 100x)



**Figure 8**  
Massive calcium deposits within connective tissue (HE, 100x)



## DISCUSSION

This is the largest series of cases reported in Ethiopia from one region. The fact that it is seen only in one gender and localised around hip region implies that there is a common risk factor in the affected population. It might be ascribed to the common activities the patients share in their daily lives. In contrast, a report of Tumoral Calcinosis in Eastern Ethiopia involved both males and females (8).

The diverse geographic distribution, absence of family history, and unavailability of signs of systemic or parasitic diseases might rule out the possibility of the following causes: metastatic and iatrogenic calcification.

Water and other materials are carried for domestic consumption by females from an early age. The traditional way of transporting water and other goods is by carrying it on the side. The fact that no single man presented with similar complaint, and that the peri-articular area of other major joints like the shoulder or elbow were not involved indicates that this lesion is dystrophic in nature of tumoral morphology. The reason why some women respondents did not confirm carrying materials on their side could be due to recall bias or communication barrier. The probable factor associated with the cases is carrying objects on their side (hip area) resulting in recurrent micro-trauma suggestive of a dystrophic type of calcification.

The presenting cases can be categorised under post-traumatic as the aetiology seems to be the micro-trauma inflicted which is related to carrying goods predominantly water pots on the side showing the possible contribution of pressure/trauma (1,7). The calcium and phosphate profile was done in three of the patients due to resource constraint. Lack of serum electrolyte investigation in all patients and absence of close monitoring of operated cases are among the limitations of the study.

In conclusion, the lesion was found to be relatively common in the study area and specifically confined to females. The probable factor associated with the cases is carrying objects on their side (hip area). Further researches with in-depth clinical and laboratory evaluation are of paramount importance to identify the causes and come up with evidence based intervention.

### ACKNOWLEDGMENT

We are highly indebted to Attat hospital management and health workers for facilitating the study. The patients deserve acknowledgment for their cooperation during the interview.

### REFERENCES

1. Fernandez-Flores A. Calcinosis Cutis: Critical Review. *Acta Dermatovenerol Croat* 2011; **19**(1):43-50.
2. Weedon D. Skin Pathology, 2nd edition, chapter 14. Churchill Livingstone, Sydney, 2002.
3. Moss J, Syrengelas A, Antaya R and Lazova R. Calcinosis cutis: a complication of intravenous administration of calcium gluconate. *J Cutan Pathol* 2006; **33** (Suppl. 2): 60-62.
4. Zouboulis CC, Blume-Peytavi U, Lennert T, et al. Fulminant metastatic calcinosis with cutaneous necrosis in a child with end-stage renal disease and tertiary hyperparathyroidism. *Br J Dermatol* 1996; **135**: 617-622.
5. Larralde M, Giachetti A, Cáceres MR, et al. Calcinosis cutis following trauma. *Paediatr Dermatol* 2005; **22**(3): 227-9.
6. Nico MMS, Bergonse FN: Subepidermal Calcified Nodule: Report of Two Cases and Review of the Literature. *Paediatric Dermatology* 2001; **18**(3): 227-229.
7. Murthy DP. Tumoral calcinosis: a study of cases from Papua New Guinea. *J Trop Med Hyg* 1990; **93**(6): 403-7.
8. Jain SP: Tumoral calcinosis in Somalia and Ethiopia: a report of twenty one cases and brief review of literature. *East Afr Med J* 1989; **66**(7): 476-80.