

East African Medical Journal Vol. 81 No. 12 December 2004

STROKE IN SICKLE CELL DISEASE IN AFRICA: CASE REPORT

J. Makani, MD, DIM, MRCP, Department of Internal Medicine, Muhimbili University College of Health Sciences, P. O. Box 65001, Dar es Salaam, Tanzania

## STROKE IN SICKLE CELL DISEASE IN AFRICA: CASE REPORT

J. MAKANI

### SUMMARY

**Stroke, including asymptomatic cerebrovascular events, is a significant cause of morbidity and mortality in sickle cell disease, occurring with an incidence of 10 to 25%. Extensive research has established that cerebral stenosis, involving the circle of Willis, is the most common mechanism in children. We report a child with sickle cell disease who presented with cortical blindness and right-sided hemiplegia. Computerised tomography of the brain revealed an infarct involving the left parietal region and extending to the occipital region. Stroke in SCD is multifactorial, but high-risk individuals can be identified by simple well-established strategies such as transcranial doppler ultrasonography. There are approaches for both primary and secondary interventions, which have been shown to be effective and need to be incorporated into management guidelines for SCD patients. Before schemes are recommended into health care policies, research in the appropriate setting is required.**

### INTRODUCTION

Stroke in children is a devastating event, occurring more commonly than previously suspected, with an incidence of 1.29 per 100,000 per year(1). Although there is limited understanding in the condition in children compared to adults, there is increasing knowledge regarding some of the factors that contribute to stroke in children. Infective conditions, prevalent in Africa, which may cause stroke, include: cerebral malaria, infective endocarditis and tuberculosis. Other non-infectious risk factors for stroke include congenital abnormalities in the heart and blood vessels (cerebral aneurysms), haematological disorders such as haemophilia, sickle cell disease. Sickle cell disease (SCD) is a major risk factor for stroke in children, with stroke occurring 250 more times in SCD patients compared to normal children(2). Although stroke may be due to haemorrhage, embolism or infarction, it has been found that cerebral infarction is the most common mechanism in children and young adults below 20 years and is thought to be the result of an occlusive vasculopathy predominantly affecting the large intracranial vessels in the circle of Willis(3). We describe a case of stroke in a child with SCD in Tanzania, to illustrate that non-infectious causes can contribute to morbidity and mortality in this setting.

### CASE REPORT

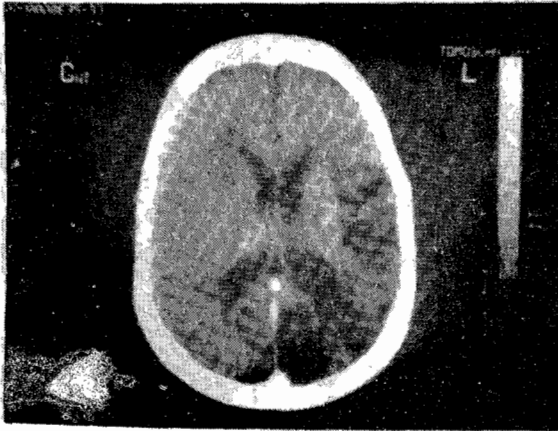
A nine year-old boy was referred to the ophthalmology department with painless loss of vision. Twenty four months previously he presented to a district hospital with acute intestinal obstruction, which

required emergency laparotomy. Twelve hours post-operatively he had sudden loss of consciousness. He was resuscitated and regained consciousness after four hours. He was subsequently well and was discharged after ten days. Two months later his mother noticed he was favouring his right arm and leg due to weakness. This was associated with loss of vision. There was no history of trauma, swelling, excessive tearing or discharge from the eyes. On direct questioning he recalled episodes of blurring of vision, which were brief and recovered spontaneously. He was diagnosed with SS SCD when he presented with painful swelling of hands and feet at six months of age. He had been relatively stable with one to two admissions a year for episodes of fever and anaemia. He had received four blood transfusions. He was on folic acid 5mg daily and Chloroquine 150mg weekly for malaria chemoprophylaxis.

On physical examination he was pale with mild jaundice. He had a pulse rate of 98 beats per minute, regular with a systolic murmur at the lower left sternal edge. The chest was clear. The abdomen was soft with hepatosplenomegaly. The ophthalmologist found visual acuity limited to hand movement but pupils were reacting to light and accommodation and fundoscopy did not reveal any abnormalities. Neurological examination revealed right lower motor neurone facial nerve palsy. Examination of the motor system showed gegenhalten rigidity of the right hand with hypertonicity. The power was grade four plus in both limbs. Deep tendon testing showed hyper reflexia with upgoing plantar reflexes.

**Figure 1**

*CT scan of the brain showing an extensive hypodense lesion in the left parietal region extending to the occipital area consistent with an infarct*



The full blood count showed haemoglobin of 6.3g/dl, sickled cells on blood film, and a normal white cell count and differential distribution. The cardiothoracic ratio was increased. In view of the clinical and chest X-ray findings, he had an echocardiogram which revealed an atrial septal defect with grade I mitral regurgitation. There was no evidence of intracardiac thrombi or valvular vegetations. CT scan of the brain revealed an extensive hypodense lesion in the left parietal region extending to the occipital area consistent with an infarct (Figure 1).

## DISCUSSION

In patients with SCD, stroke may occur as an acute clinical syndrome presenting with hemiplegia, convulsions, and visual or hearing loss. Stroke, presenting as cortical blindness, although unusual, has been reported in SCD patients(4) and in strokes due to other conditions(5). The outcome following cortical blindness with respect to regaining vision is variable(6), but in this patient, there was an improvement in his visual acuity, suggesting that prognosis is good. The event could have occurred during or immediately following surgery, or during the convalescent period. The stress of surgery is a recognised precipitating factor for vasoocclusive events in SCD(7).

Various therapeutic options have been found to be useful in reducing the risk of events occurring during surgery(8) and in a district hospital with limited resources preoperative blood transfusion, adequate postoperative analgesia, inhaled nitric oxide are therapies that would have improved the anaesthetic course of the patient and possibly prevented the stroke. However, a recognised difference between childhood and adult stroke is overlapping risk factors(9) and in this patient other factors that may have contributed to the event were anaesthesia and thromboembolism secondary to

the atrial septal defect with possible arrhythmias. In addition, there is a possibility that the cerebral infarction seen in this patient was a consequence of recurrent neurological events. This is because with increased understanding of the natural history of SCD particularly from studies in Jamaica and USA, it is apparent that there are numerous vascular events that occur in SCD patients, which are 'asymptomatic'(10). These subclinical events, silent infarcts, may manifest as neuropsychological deficits, impaired intellectual function, behavioural problems etc. and have been demonstrated in Tanzania(11) and more extensively elsewhere(12-14).

Recent reports have shown that there is an increase in prevalence of SCD surviving into adolescents and adulthood in Africa suggesting that there will be a rise in the incidence of chronic end-organ damage. Although, approximately 25% patients with SCD will have had a stroke by the age of 45 years, most vascular events occur between the ages of five and ten years(15). Fortunately, children with an increased risk of stroke can be identified by measuring cerebral blood flow velocity using transcranial doppler ultrasonography (TCD). Extensive studies showed that increased cerebral blood flow velocity (CBFv) of 200cm per second was associated with a 40% risk of stroke within three years(16).

Options for both primary and secondary intervention, include blood transfusion, hydroxyurea and comprehensive care have been effective enough to be incorporated into national policies(17). However, such strategies are costly to a resource-poor health system, and associated with a high risk. It is therefore important to define the high-risk groups based on evidence from studies in Africa before such interventions are proposed and integrated into appropriate management and preventative guidelines and policies at all levels of health care.

## ACKNOWLEDGEMENTS

To Dr. G. Saguti and Dr. A. Sanyiwa from the Department of Ophthalmology and Dr. K. Mwamtemi from Department of Paediatrics for their support. To the Centre for Geographic Medicine Coast, Wellcome-KEMRI Collaborative Research Programme, Kilifi, Kenya for additional support.

## REFERENCES

1. Earley, C.J., Kittner, S. J. Feeser, B.R. *et al.* Stroke in children and sickle-cell disease: Baltimore Washington Cooperative Young Stroke Study. *Neurology*. 1998; **51**:169-176.
2. Ohene-Frempong, K., Weiner, S.J. Sleeper, L.A. *et al.* Cerebrovascular accidents in sickle cell disease: rates and risk factors. *Blood*. 1998; **91**:288-294.
3. Adams, R. J., Nichols, F.T. Mckie, V. *et al.* Cerebral infarction in sickle cell anaemia: mechanism based on CT and MRI. *Neurology*. 1988; **38**:1012-1017.
4. Wierenga, K. J., Serjeant, B.E. and Serjeant, G.R. Cerebrovascular complications and parvovirus infection in homozygous sickle cell disease. *J. Pediatr*. 2001; **139**:438-442.

5. Belden, J. R. Caplan, L. R., Pessin, M.S. *et al.* Mechanisms and clinical features of posterior border-zone infarcts. *Neurology*. 1999; **53**:1312-1318.
6. Foley, J. and Gordon, N. Recovery from cortical blindness. *Dev. Med. Child. Neurol.* 1985; **27**:383-387.
7. Dix, H.M., New advances in the treatment of sickle cell disease: focus on perioperative significance. *Aana. J.* 2001; **69**:281-286.
8. Riddington, C. and Williamson, L. Preoperative blood transfusions for sickle cell disease (Cochrane Review). *Cochrane Database Syst Rev.* 2001; **3**.
9. deVeber, G., *et al.* Stroke in children: recognition treatment and future directions. *Semin Pediat. Neurol.* 2000; **7**:309-317.
10. Adams, R. J., Ohene-Frempong, K. and Wang, W. Sickle cell and the brain. *Hematology. Amer. Soc. Hematol. Educ. Program.* 2001; 31-46.
11. Fowler, M.G., Whitt, J.K. Lallinger, R.R. *et al.* Neuropsychologic and academic functioning of children with sickle cell anemia. *J. Dev. Behav. Pediatr.* 1988; **9**:213-220.
12. Ashley-Koch, A., Murphy, C. C., Khoury, M. J. *et al.* Contribution of sickle cell disease to the occurrence of developmental disabilities: a population-based study. *Genet Med.* 2001; **3**:181-186.
13. Schatz, J., Brown, R.T., Pascula, J. M. *et al.* Poor school and cognitive functioning with silent cerebral infarcts and sickle cell disease. *Neurology.* 2001; **56**:1109-1111.
14. Wang, W. Enos, D. L., Gallagher, D. *et al.* Neuropsychologic performance in school-aged children with sickle cell disease: a report from the Cooperative Study of Sickle Cell Disease. *J. Pediatr.* 2001; **139**:391-397.
15. Adams, R.J., Stroke prevention and treatment in sickle cell disease. *Arch Neurol.* 2001; **8**:565-568.
16. Adams, R., Mckie, V. Nichols, F. *et al.* The use of transcranial ultrasonography to predict stroke in sickle cell disease. *New Engl. J. Med.* 1992; **326**:605-610.
17. Adams, R.J., Mckie, V.C., Hsu, L. *et al.* Prevention of a first stroke by transfusions in children with sickle cell anemia and abnormal results on transcranial doppler ultrasonography. *New Engl. J. Med.* 1998; **339**:5-11.