

Congenital Diaphragmatic Hernia with Gastric Volvulus and Splenic Herniation: An Unusual Delayed Presentation in a Six-Month Child

Mathayo Shadrack^a, Jamil Suleiman^{a*}, David Msuya^{a,b}, Rune Philemon^{b,c}, Adnan Sadiq^{b,d}, Murad Tarmohamed^a, Jay Lodhia^{a,b}

^aDepartment of General Surgery, Kilimanjaro Christian Medical Center, Moshi, Tanzania, ^bKilimanjaro Christian Medical University College, Faculty of Medicine, Moshi, Tanzania, ^cDepartment of Pediatrics, Kilimanjaro Christian Medical Center, Moshi, Tanzania, ^dDepartment of Radiology, Kilimanjaro Christian Medical Center, Moshi, Tanzania

Correspondence to Jay Lodhia (jaylodhia06@gmail.com)

ABSTRACT

Background: Acute gastric volvulus associated with congenital diaphragmatic hernia is an uncommon disorder in infancy and a surgical emergency.

Methods: We present a six-month female baby who presented with clinical features of intestinal obstruction. Ultrasonography of the abdomen revealed gastric volvulus. The baby underwent emergency laparotomy. Gastric volvulus with splenic herniation was encountered through a diaphragmatic hernia.

Results: The defect was corrected, the stomach and spleen were mobilized into the normal anatomical position. The baby recovered well.

Conclusion: A high index of clinical suspicion and thorough radiological assessments are necessary for this life-threatening condition along with surgical correction of the abnormalities.

BACKGROUND

Congenital Diaphragmatic Hernia (CDH) is a developmental abnormality due to the incomplete fusion and closure of the pleuroperitoneal canal during fetal development with an incidence of 0.8/10,000 to 5/10,000 births^{1,2}. CDH can be diagnosed prenatally or, as is often the case, during the neonatal period. Occasionally, CDH can be missed, and children can present later in acute respiratory or gastrointestinal symptoms.^{1,3}

Infants often present with respiratory distress, and presentation after infancy occurs in 5% to 10% of the affected neonates and present with respiratory distress from pleural effusion or gastrointestinal distress from intestinal obstruction. However, 1% of the cases can be asymptomatic and discovered incidentally on imaging⁴. Despite the advances in medical and surgical management of CDH the morbidity and mortality remains high.² Gastric volvulus associated with CDH constitutes a surgical emergency. We present a six-month-female from Tanzania with acute gastric volvulus associated with CDH who presented with features of gastrointestinal obstruction.

CASE PRESENTATION

A six-month-old female baby was referred to our tertiary centre from a regional hospital due to vomiting

for four days, inability to pass stool and abdominal distention for three days. The vomiting was projectile and bilious but not stained with blood. There was no fever reported. Herbal medication was given at home with no improvement. The parents are Maasai who are the indigenous tribe, and the baby was born at term by SVD at a health centre with a birth weight of 2900 grams and received all immunisations according to local guidelines. On general examination, the patient was sick looking, not pale, acyanotic and not dyspneic. Her blood pressure was 110/60 mmHg, pulse rate 125 beats per minute, respiration rate 28 breaths per minute and saturating at 96% on room air. Body weight on admission was 8700 grams. On systemic examination, the abdomen was distended more on the left upper quadrant with traditional markings on the upper quadrants. The abdomen on palpation was tense and tender more at the epigastric region, and bowel sounds were reduced on auscultation. The rectum was empty on digital rectal examination. Heart sounds were heard normally on auscultation and lungs revealed reduced air entry more on the left lower zone.

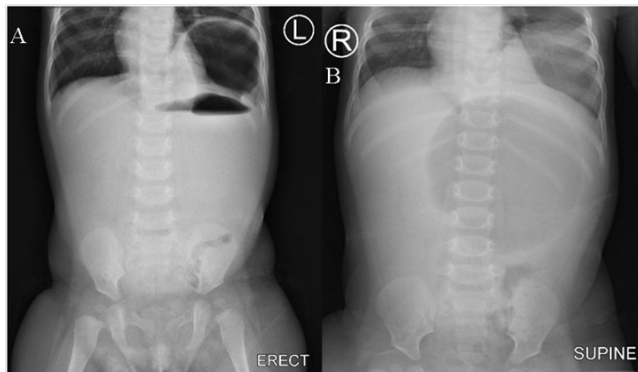
Abdominal ultrasound (Siemens Acuson NX3, Germany) was done revealing gastric volvulus and reduced gastric peristalsis. An abdominal x-ray showed gastric air-fluid levels (Figure 1).

Her complete blood count revealed microcytic hypochromic anemia of 8.8 g/dl, raised leukocyte count of $21 \times 10^9/L$ and a normal platelet count of $447 \times 10^9/L$. The serum creatinine was normal at $57 \mu\text{mol/l}$, serum sodium 180.02 mmol/L , serum potassium 3.51 mmol/L , aspartate aminotransferase 34.02 U/l and alanine aminotransferase 13.72 U/l . Blood group was O Rhesus-positive.

The patient was given Ceftriaxone 450 mg and Metronidazole 80 mg intravenously and transfused one unit (200 milliliters) of whole blood before being taken for an emergency laparotomy. The abdomen was opened through a transverse incision, the stomach was grossly distended, the gastric antrum was rotated clockwise about 90 degrees at the level of the fundus. There was a left diaphragmatic defect of about 3 x 4 centimeters (Figure 2). The fundus and spleen were both herniated through the defect into the chest. The stomach was mobilized and rotated anticlockwise to its anatomical position. The fundus was reduced back followed by the spleen. Suctioning of fluid content from the chest was done, and the diaphragmatic defect was repaired using nylon suture in a continuous technique. The abdomen was cleaned thoroughly with warm saline and closed in layers.

y was reviewed again whereby the mother reported the baby to continue to gain weight well and reported of no complaints hence was discharged.

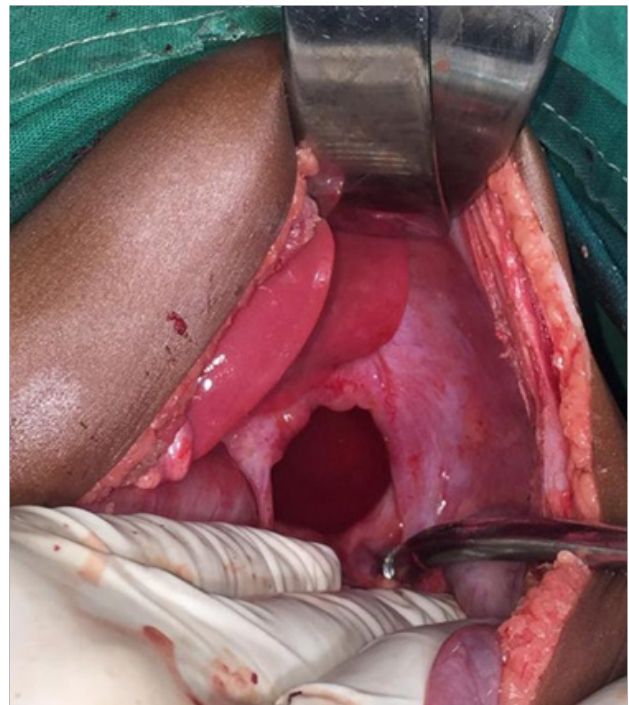
FIGURE 1. An Abdominal X-Ray showing Gastric Air-Fluid Levels



A: Erect abdomen x-ray. B: Supine abdomen x-ray. X-rays demonstrate a left congenital diaphragmatic hernia with protrusion of the stomach into the left hemithorax. Findings suggestive of bochdalek hernia.

Postoperatively, the baby was nursed in ICU for four days, transfused with 180 milliliters of whole blood and kept on intravenous Ceftriaxone 450 mg once daily and Metronidazole 80 mg eight-hourly for five days along with Paracetamol 140 mg for 24 hours. Control chest x-ray was done after 24-hours (Figure 3). Control full blood picture revealed leucocyte count of $9.71 \times 10^9/L$, hemoglobin of 16.9 g/dl and a platelet count of $200 \times 10^9/L$. The baby fared well and was discharged on day six postoperatively with Amoxicillin-Clavulanic acid syrup for five days and to return to the surgical outpatient clinic after two weeks for a review of which the baby fared well, was tolerating meals and incision had healed. After two months the bab-

FIGURE 2. Image Showing Left Sided Diaphragmatic Defect



DISCUSSION

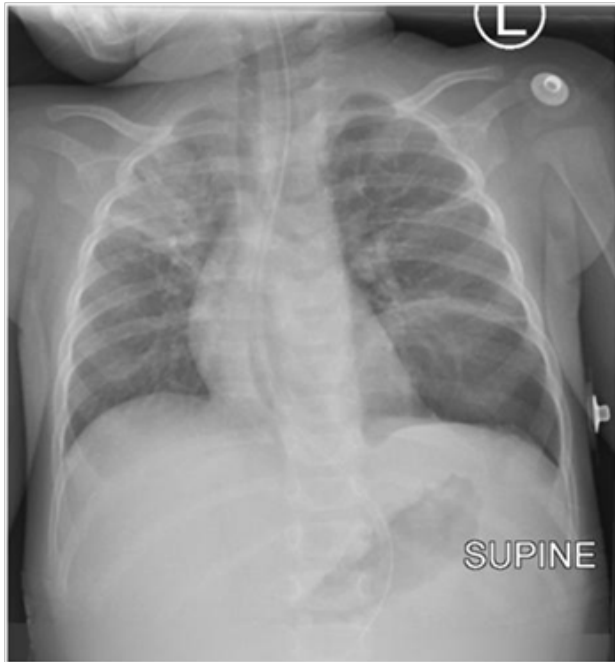A congenital diaphragmatic hernia is a developmental defect characterized by incomplete fusion of the pleuroperitoneal canal, usually evident at birth^{1,4}. This defect creates a pathway for intra-abdominal structures to herniate into the thoracic cavity. It is mainly classified anatomically into three main types; posterolateral (Bochdalek) hernia which is the most common type (80-90% of cases), anterior parasternal or retrosternal (Morgagni) hernia and Central hernia⁴. Our child presented with a posterolateral hernia.

A diaphragmatic defect increases the risk of gastric volvulus. However, this presentation is infrequent, with Javier et al stating that only 26 pediatric cases had been reported worldwide by 2008, and only 15 of the patients were infants³. The risk is increased due to anomalies in any of the four ligaments (gastrocolic, gastrohepatic, gastrophrenic and gastrosplenic) inserted in the diaphragm, that hold the stomach in position^{3,5,6}. In patients with a defect in the diaphragm, the gastric fixation can be elongated or absent⁷. Increased subdiaphragmatic space could also increase the risk of an abnormal stomach rotation⁸.

Gastric volvulus can be classified into three types, organoaxial, mesenteroaxial and combined.⁹⁻¹¹ Organoaxial volvulus, as seen in our case, is the most

common type seen in 60% of volvulus cases. In organoaxial volvulus, the rotation occurs along the cardio-pylorus axis due to abnormal mobility and deficient fixation at the hiatus of the stomach¹². A diaphragmatic hernia is frequently associated with this type¹³. In mesenteroaxial volvulus, the stomach rotates around an axis between the greater and lesser curvatures. Finally, in the combined type, the stomach rotates about both axes¹². Anomalies in the ligaments could also lead to splenic herniation as seen in the index case, although it is a rare finding in the postneonatal age¹⁴. Some authors report that a mobile spleen could potentially cause the volvulus by drawing the gastric fundus downwards in an erect position.¹⁵

FIGURE 3. Post-operative Supine Antero-Posterior Chest X-Ray



Chest x-ray, no longer shows protruding stomach in the left hemithorax. Consolidation of the anterior segment of the right upper lobe noted in keeping with pneumonia. Atelectatic bands seen in the left mid zone.

The classical triad of Borchardt which include epigastric distension, unproductive retching and inability to pass naso-gastric tube is usually described in adults, and rarely seen in neonates and infants^{12,16}. Neonates usually have a typical presentation of vomiting and respiratory distress while infants present with vomiting and epigastric distention as seen in our case.^{14,17}

The diagnosis is suspected when an erect chest radiograph shows a high air-fluid level, and abdominal radiographs show increased soft tissue density in the upper abdomen¹⁸.

Further complimentary tests are needed, such as a CT-scan or barium contrast studies, with the latter serving

to confirm the diagnosis. If the diagnosis is evident with a plain X-ray, as seen in our case, surgical management should not be delayed with further tests^{1,3}.

Since the diagnosis is based on a high index of suspicion, in some instances, the condition is misdiagnosed as pneumothorax, pleural effusions, hydrothorax, hydropneumothorax, bronchogenic cysts and hence subjected to inappropriate thoracentesis^{19,20}.

Surgical management involves performing a laparotomy, usually as an emergency. It involves detortion of the volvulus, reduction of the herniated structure with or without resection of the necrotic segments, and repairing of the diaphragmatic defect.^{3,21-23} It is recommended to fix the stomach either by gastrostomy or gastropexy, but some authors reported no fixation, with few cases or recurrences.^{22,24} In our case, fixation of the stomach was not required as it was not redundant, and after reduction, it returned to its normal anatomical position.

Acute gastric volvulus with congenital diaphragmatic hernia is a surgical emergency, with mortality rates estimated up to 80% without surgical intervention²⁵. Any delays in surgical intervention can lead to catastrophic complications such as acute pneumothorax, gastrothorax, splenic torsion, appendicitis, incarceration, strangulation, ischemia, perforation, peritonitis and death²⁶⁻²⁸.

CONCLUSION

CDH with Gastric volvulus is a surgical emergency, and early diagnosis with immediate surgical intervention is required for good outcome. However many patients have limited access to specialized tertiary referral care centres, therefore diagnosis cannot be established and prompt management cannot be offered. This case report highlights the importance of thorough prenatal screening to aid multidisciplinary management plan and helps creates awareness among clinicians to have CDH as their differential diagnosis.

Ethical Considerations

Ethical approval was obtained from the Department of General Surgery, Kilimanjaro Christian Medical Centre. Written informed consent was obtained from the patient's mother for publication for this case report; additionally, accompanying images have been censored to ensure that the patient cannot be identified. A copy of the consent is available on record.

REFERENCES

1. Pérez-Egido I, Parente A, Cerdá J. Acute gastric volvulus and congenital diaphragmatic hernia, case report and review. *African Journal of Paediatric Surgery*. 2015;12(3):200.
2. Chandrasekharan PK, Rawat M, Madappa R, Rothstein DH, Lakshminrusimha S. Congenital Diaphragmatic hernia—a review. *Maternal health, neonatology and perinatology*. 2017 Dec;3(1):1-6.
3. Ayala JA, Naik-Mathuria B, Olutoye OO. Delayed presentation of congenital diaphragmatic hernia manifesting as combined-type acute gastric volvulus: a case report and review of the literature. *Journal of pediatric surgery*. 2008 Mar 1;43(3):e35-9.

4. Longoni M, Pober BR, High FA. Congenital Diaphragmatic Hernia Overview. 2006 Feb 1 [Updated 2019 Mar 28]. In: Adam MP, Ardinger HH, Pagon RA, et al., editors. GeneReviews® [Internet]. Seattle (WA): University of Washington, Seattle; 1993-2020. Available from: <https://www.ncbi.nlm.nih.gov/books/NBK1359/>
5. Mayo A, Erez I, Lazar L, Rathaus V, Konen O, Freud E. Volvulus of the stomach in childhood: The spectrum of the disease. *Pediatric Emergency Care*. 2001;17(5):344-348.
6. Cribbs R, Gow K, Wulkan M. Gastric Volvulus in Infants and Children. *PEDIATRICS*. 2008;122(3):e752-e762.
7. Karabulut R, Türkyılmaz Z, Sönmez K, Karakus S, Basaklar A. Delayed presentation of congenital diaphragmatic hernia with intrathoracic gastric volvulus. *World Journal of Pediatrics*. 2009;5(3):226-228.
8. Ito T, Hasnie R, Crosby D, Milbrandt J, Ettema S, Duong M. Gastric Volvulus Complication in an Infant With Undiagnosed Congenital Diaphragmatic Hernia Presenting With Acute Respiratory Distress. *Pediatric Emergency Care*. 2012;28(10):1078-1080.
9. Kumar B, Kalra T, Namdeo R, Soni R, Sinha A. Acute gastric volvulus: A vicious twist of tummy-case report. *International Journal of Surgery Case Reports*. 2017;30:81-85.
10. Channer LT, Squires GT, Price PD. Laparoscopic repair of gastric volvulus. *JSLs*. 2000;4(3):225-230.
11. Chau B, Dufel S. Gastric volvulus. *Emergency Medicine Journal*. 2007;24(6):446-447.
12. David L. Lesions of the stomach In: Ashcraft KW. *Pediatric surgery*, 2 Ed. WB Saunders Company, Philadelphia. 1993. pp 295-296
13. McGrane O, McGrane K. A Case of Organoaxial Gastric Volvulus. *Emergency Medicine News*. 2011;33:1.
14. Sehgal A, Chandra J, Singh V, Dutta AK, Bagga D. Congenital diaphragmatic hernia: delayed presentation with asymptomatic splenic herniation. *Indian J Chest Dis Allied Sci*. 2002;44(1):57-60.
15. Heldrich F, Kumarasena D, Hakim J, Dunn J, Setya V. Acute gastric volvulus in children. *Pediatric Emergency Care*. 1993;9(4):221-222.
16. Tam PKH. Stomach and gastric outlet. In: Freeman NV, Burge DM, Griffiths DM, et al., eds. *Surgery of the Newborn*. Edinburgh: Churchill Livingstone; 1994: 85-106.
17. Brzezinski W, Laskin MM, Wong KS. Acute mesenteroaxial gastric volvulus in an infant: a case report. *Can J Surg*. 1993;36(3):233-235.
18. Rashid F, Thangarajah T, Mulvey D, Larvin M, Iftikhar S. A review article on gastric volvulus: A challenge to diagnosis and management. *International Journal of Surgery*. 2010;8(1):18-24.
19. Berman L, Stringer D, Ein S, Shandling B. The late-presenting pediatric bochdalek hernia: A 20-year review. *Journal of Pediatric Surgery*. 1988;23(8):735-739.
20. de Lorimier Alfred A. *Diaphragmatic hernia; pediatric surgery* Ed. Ashcraft Keith W, Holder Thomas M, 2nd edition, chapter 19; WB Saunders Company, Philadelphia; 1993 : 204-17.
21. Gerstle J, Chiu P, Emil S. Gastric volvulus in children: lessons learned from delayed diagnoses. *Seminars in Pediatric Surgery*. 2009;18(2):98-103.
22. McIntyre RC Jr, Bensard DD, Karrer FM, Hall RJ, Lilly JR. The pediatric diaphragm in acute gastric volvulus. *J Am Coll Surg*. 1994;178(3):234-238.
23. Marra GA, Casalboni M, Magni E, Zaccaroni A. Gastric volvulus. A clinical therapeutic contribution. *Minerva Chir*. 1993;48(17):925-929.
24. Park W, Choi S, Suh S. Pediatric gastric volvulus: experience with 7 cases. *Journal of Korean Medical Science*. 1992;7(3):258.
25. Al-Salem A. Intrathoracic gastric volvulus in infancy. *Pediatric Radiology*. 2000;30(12):842-845.
26. Oliver M, Wilson A, Kapila L. Acute pancreatitis and gastric volvulus occurring in a congenital diaphragmatic hernia. *Journal of Pediatric Surgery*. 1990;25(12):1240-1241.
27. Beckmann K, Nozicka C. Congenital diaphragmatic hernia with gastric volvulus presenting as an acute tension gastrothorax. *The American Journal of Emergency Medicine*. 1999;17(1):35-37.
28. Sharma S, Gopal SC. Gastric volvulus with perforation in association with congenital diaphragmatic hernia. *Indian J Pediatr*. 2004;71(10):948.

Peer Reviewed

Competing Interests: None declared.

Funding: The study did not receive any funding

Received: 29 January 2021; **Accepted:** 08 June 2022

Cite this article as Shadrack M, Suleiman J, Msuya D, Philemon R, Sadiq A, Tarmohamed M, Lodhia J. Congenital Diaphragmatic Hernia with Gastric Volvulus and Splenic Herniation: An Unusual Delayed Presentation in A Six-Month Child. *East Afr Health Res J*. 2022;6(1):18-21. <https://doi.org/10.24248/eahrj.v6i1.674>

© Shadrack et al. This is an open-access article distributed under the terms of the Creative Commons Attribution License, which permits unrestricted use, distribution, and reproduction in any medium, provided the original author and source are properly cited. To view a copy of the license, visit <http://creativecommons.org/licenses/by/4.0/>. When linking to this article, please use the following permanent link: <https://doi.org/10.24248/eahrj.v6i1.674>
