

Effect of Methanol Root Extract of *Pausinystalia yohimbe* on Epididymal Sperm Cells of Wistar Albino Rats

*¹Ojatula, Adekunle Orimisan and ²Aturu, Oluwadamilola Tubosun

^{1, 2}PhytoMedicine, PhytoPharmacology and Drug Discovery Research Group,
Department of Biological Sciences (Botany Programme),
Olusegun Agagu University of Science and Technology,
Okitipupa, Ondo State,
Nigeria

Email Address: kunletula@yahoo.com

ORCID ID: 0000000316333080

Abstract

The epididymis is essential for spermatozoa maturation, including the acquisition of progressive motility and fertilizing ability. Without a safe dose regimen treating several related reproductive disorders, the root of *P. yohimbe* remains one of the many herbs commonly used by traditional herbal medicine practitioners in achieving such roles. The purpose of this study was to examine the effect of herbal extract on sperm parameters and histoarchitecture of epididymal sperm cells in rats. Twenty-five Wistar rats were randomly assigned to one of four treatment groups and one control group. For 28 days, the control group received only 10 mL/kg distilled water, while the treatment groups received 25, 50, 100, and 200 mg/kg b.w of *P. yohimbe* methanol root extract via oral cannula. On day 29, all animals were anesthetized, and their caudal epididymis was isolated and histologically processed. *P. yohimbe* root extract increased sperm count and motility, with normal histological indices of the epididymises examined relaying immune-protected sperm cells in normal spermatogenetic sequential maturation and viability, without lesion or architectural degeneration, and was comparable to, but not different from, the control. The current study supports the safety profile of *P. yohimbe* herbal preparation in doses administered to male Wistar rats, and that it could be used to justify human circumstances, potentially improving human health. However, future research on this plant may attempt to look at higher doses under similar conditions, providing a foundation for further screening and research.

Keywords: *Pausinystalia yohimbe*; Epididymis; Sperm cells; Epididymal transit; Sperm maturation

INTRODUCTION

Spermatozoa that exit the testis and enter the epididymis, a long-convoluted tubule, are known functional gametes (Cornwall, 2009). Spermatozoa develop progressive motility, allowing them to fertilize ova only while passing through the epididymis (Amann, 1989). Because spermatozoa are mostly synthetically inactive, maturation requires spermatozoa to interact with proteins synthesized and secreted from the epididymal epithelium in a region-dependent manner. Despite considerable effort, the molecular and biochemical events necessary for epididymal sperm maturation remain unknown (Cornwall, 2009), but could be ascribed to hygienic food intake of proteinous functional compounds (Ojatula, 2019). At birth, the epididymis is derived from the Wolffian duct and is primarily composed of mesenchymal

*Author for Correspondence

tissue (Amann, 1989). The epididymis undergoes significant remodeling, including duct elongation and convolution, until it reaches puberty and has fully differentiated into a highly tortuous tubule lined by epithelial cells (Rodriguez *et al.*, 2002). The development of a fully differentiated epithelium requires the influence of luminal factors from the testis as well as androgens (Rodriguez *et al.*, 2002).

Pausinystalia yohimbe is a well-known aphrodisiac with both sex-enhancing and fertility-enhancing properties (Ojatula, 2020; Ojatula *et al.*, 2020; Ojatula, 2022). The ethno-medicinal plant is found in nearly every tropical country and region of the world, particularly Nigeria as contained in the ethno-medicinal report of Erhabor *et al.* (2015). It is a member of the Rubiaceae family. It is a tall tree with a 1.2-metre girth and an 18-metre height. It has a tap root system and roots that can be erect, bent, folded, and branching (Ojatula, 2019; Ojatula *et al.*, 2020).

Sequel to numerous phytopharmacological applications of *P. yohimbe* in reproductive medicine; as contained in the previous works of Amann (1989) and Ojatula (2022). Hence, the need to investigate the effect on the cyto-architecture of reproductive visceral organs, such as the epididymis, as applicable in this study, by giving credence to existing literature and offering future hope on yohimbe as a potent spermatogenic agent. Therefore, the purpose of this study was to investigate the effect of herbal extract from *P. yohimbe* roots on some sperm parameters and histoarchitecture of epididymal sperm cells in male Wistar rats.

MATERIALS AND METHODS

Ethics Statement

The study employed animal research model and natural plant sources to justify human circumstances. The procedures followed in this study were carried out in accordance with National Research Council accepted principles and guidelines for laboratory animal use and care (NRC, 1996); and more importantly, in accordance with the ethical standards of ethics committee on animal and plant experimentation of Okitipupa, Nigeria: Olusegun Agagu University of Science and Technology with protocol number OAUSTECH/PHYTOMED.101/23/E.

Plant Procurement and Authentication

P. yohimbe roots were collected near the boundary of Okomu National Park in Udo, Edo State, Nigeria. A voucher specimen was given and a sample plant was deposited at the Departmental Herbarium, PhytoMedicine Unit, Department of Plant Biology and Biotechnology, Faculty of Life Sciences, University of Benin, Nigeria (Accession No. UPBHx1066).

Preparation of Extract from the roots of *Pausinystalia yohimbe*

The roots collected, were washed with tap water, dried in the oven, and finely powdered. Roots powder were soaked in 90% methanol for three days to produce a crude extract. The root suspension was filtered and rotary evaporated to yield 21.6 g of crude extract (6.27% yield). This extract was then reconstituted with distilled water to procure the study's doses. For subsequent assays, doses were prepared in increments of 25, 50, 100, and 200 mg/kg.

Experimental Animals

Twenty-five inbred male Wistar rats weighing 202.25 g each were used in the study and housed in wire gauze cages. This study used rats that had already been acclimatized in the fly-proof Laboratory animal unit at room temperature (26-28 °C) and adequate ventilation at

the Department of Anatomy, University of Benin, Benin City, Edo State, Nigeria. They were fed with standard grower mash produced by Vita Feeds Nigeria Limited with free access to clean tap water. The assessment of the experimental rats as regards its response to the extract followed the protocol on the care and use of laboratory animals (NRC, 1996); and grouped into five.

Experimental Protocol

The experimental rats were chosen one at a time with a hand towel, and an oral cannula was used to administer appropriate concentrations of the extract to the rats in groups (B, C, D, and E) ranging from (25, 50, 100, and 200 mg/kg) orally for 28 days.

The control group (A) received 10 mL/kg distilled water, while the other four groups (B, C, D, and E) served as the test groups. The experimental rats were given the following treatments:

- Feed + potable water (Control) Group A.
- Group B received 25 mg/kg b.w. of *P. yohimbe* root extract, feed, and potable water.
- Group C received 50 mg/kg body weight of *P. yohimbe* root extract, feed, and potable water.
- Group D received 100 mg/kg body weight of *P. yohimbe* root extract, feed, and potable water.
- Group E received 200 mg/kg b.w. of *P. yohimbe* root extract, feed, and potable water.

The rats' body weights (g) were measured before and after extract administration from the first day of feeding to the 28th day. The rats were sacrificed after twenty-eight (28) days of treatment, and further evaluations and analyses were performed.

Evaluation of Sperm Motility and Sperm Count

Small cuts in the caudae epididymis were used to obtain samples in this study. These were subsequently placed in 1 mL of modified Krebs Ringer-bicarbonate buffer (pH 7.4). Sperm count and motility were assessed in the sperm suspension. The observed method described by Anderson *et al.* (1983) was used to determine motility under a compound microscope, while the Neubauer haemocytometer was used to count sperm with little modification from the procedures reported by Ojatula (2020).

Evaluation of *P. yohimbe* Histological Effect on Epididymal Sperm Cells of Wistar Rats

On day 29, all of the experimental rats (treated and untreated) were sacrificed by cervical dislocation at the end of the study. The epididymis was excised from test and control rats and immediately preserved in Bouin's fluid after being weighed and examined for gross and pathological alterations. Tissues were fixed in Bouin's fluid and dehydrated with increasing concentrations of absolute alcohol. After clearing the tissues in xylene baths, they were impregnated in paraffin wax. Sections were cut with an Erlich's Haematoxylin (H) and Eosin (E) stained microtome (Hestion ERM 4000 Germany). Haematoxylin typically stains cell nuclei bluish-black, whereas eosin stains cell cytoplasm and most connective tissue fibers pink. The slides were examined microscopically with a light microscope (Olympus, England) and a digital camera (Olympus, England), and a micrograph of each plate was taken and examined for any sperm cell malformations or lesions, as reported by Neel *et al.* (2007).

Data Evaluation

Data generated from this study were presented as means and standard deviations of three determinations. and were subjected to one-way analysis of variance (ANOVA) followed by Duncan multiple range test to determine whether there was a significant difference between groups at $P < 0.05$.

RESULTS

Effect of Extract of *P. yohimbe* Root on Body and Visceral Organ Weights of Rats

Table 1 shows the calculated body weights as well as the weights of the animals' vital organs. The study found that the treated groups had non-significantly higher mean body weight than the control groups ($P > 0.05$) (Table 1). And that, the epididymis equally showed a non-significant weight differences across treated and control groups of animals. All of the animals had normal visceral organ weights, with no significant difference between the control and treated groups. Results revealed that, visceral organ, the epididymis, was not adversely affected throughout the treatment.

Table 1: Mean body and visceral organ weights of the extract-treated and control groups of rats

Group	No. of Rats	Doses mg/kg	Body weight before administration	Body weight after administration	Weight of Visceral Organ (Epididymis)
A (Control)	25	10 mL/kg	152.0 ± 5.5	180.0 ± 5.0	0.44 ± 0.03a
B	25	25	133.0 ± 5.6	182.0 ± 10.3	0.41 ± 0.03a
C	25	50	137.4 ± 0.25	190.0 ± 6.4	0.47 ± 0.06a
D	25	100	145.6 ± 4.0	200.3 ± 7.75	0.46 ± 0.02a
E	25	200	157.1 ± 5.6	210.6 ± 4.5	0.45 ± 0.03a

*Values possessing same superscripts are not significantly ($P > 0.05$) different when compared to control and each other

Effect of Extract of *P. yohimbe* on Epididymal Sperm Cells in Wistar Rats

The effect of extract of *P. yohimbe* on epididymal sperm cells in experimental wistar albino rats was thoroughly examined and recorded. From the findings of the study, sperm count and percentage sperm motility were both increased significantly ($P < 0.05$) across treatment groups of rats, in comparison to the control values (Table 2).

Table 2: *Pausinystalia yohimbe*'s effect on sperm motility and count in Wistar albino rats

Group	Treatment	Dose (mg/kg)	% sperm motility	Sperm count (log N/mm ²)
A	Control	10 mL/kg	50.00 ± 34.75 ^b	4.51 ± 0.20 ^b
B	Yohimbe	25	66.25 ± 34.56 ^a	4.69 ± 0.16 ^a
C	Yohimbe	50	70.25 ± 28.93 ^a	4.79 ± 0.16 ^a
D	Yohimbe	100	90.00 ± 6.13 ^a	4.76 ± 0.13 ^a
E	Yohimbe	200	95.01 ± 6.13 ^a	4.88 ± 0.09 ^a

*Values possessing superscripts when compared to the control, a, b are significantly ($P < 0.05$) different from each other

Effect of Extract of *P. yohimbe* on Histoarchitecture of Epididymes of Experimental Rats

Histological examination of the control group's caudal epididymis (Plate 1) revealed regular epididymal ducts with pseudostratified columnar epithelia and stereocilia. The basement membrane, which contains basal cells, surrounds the epithelia. Spermatozoa were packed into the tubule lumens. Histological analysis of cross sections obtained from groups given 25, 50, 100, and 200 mg/kg of the extract uncovered relatively normal tubules sequentially packed with mature spermatozoa, increased sperm cell population, and moderately increased spermatozoa population, across all groups, with an intact epithelial lining (Plate 1, I-V).

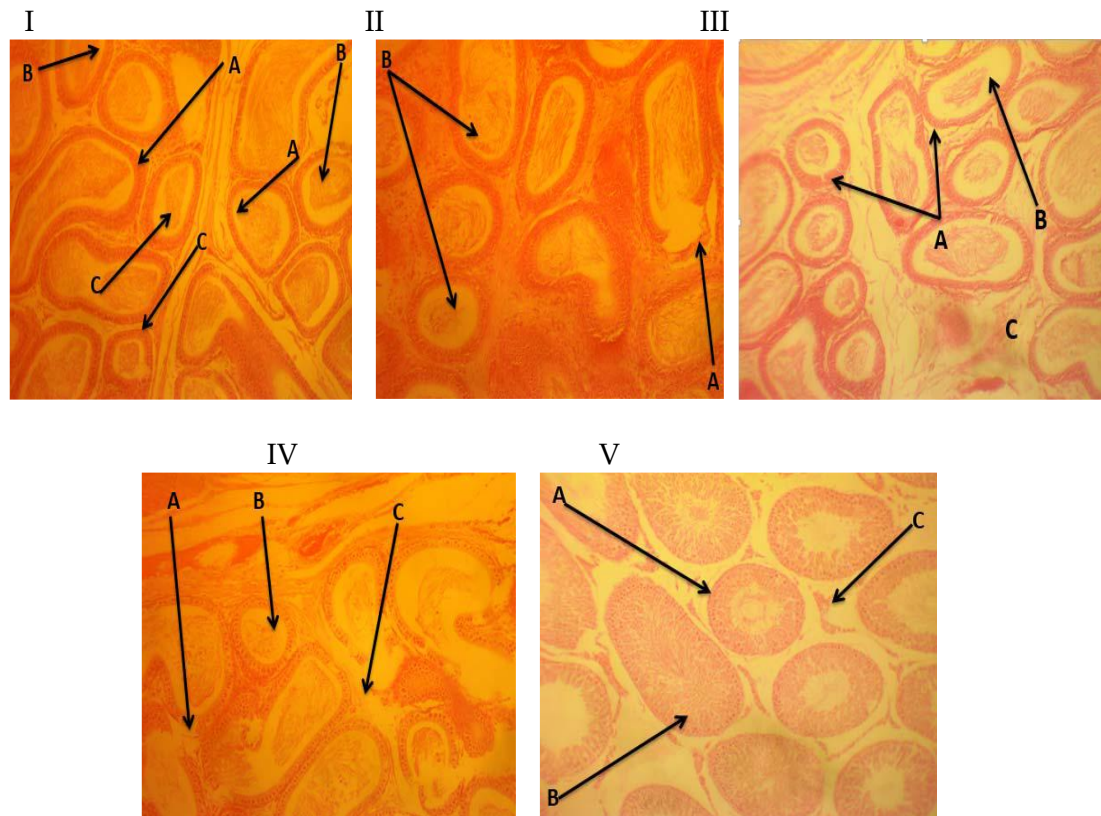


Plate 1: Rat epididymis sections stained with hematoxylin and eosin. Panel (I) A control rat's epididymis with epididymal tubules-A lined by ciliated columnar epithelium cells, a lumen packed with mature spermatozoa-B, and an interstitial space-C. Panel (II) Rat epididymis treated with 25 mg/kg *P. yohimbe* for 28 days demonstrated normal architecture with a focal area of epididymal tubule normalcy-A and a population of mature spermatozoa in the lumen-B. Panel (III) *P. yohimbe* 50 mg/kg rat epididymis showed normal epididymal tubules lined by columnar epithelium-A, lumen with increased spermatozoa population-B, and sparse interstitial tissue-C. Panel (IV) Rat epididymis exposed to 100 mg/kg *P. yohimbe* for 28 days demonstrates epididymal architecture with tubules-A, increased luminal spermatogenic population-B, and interstitial tissue spaces-C, as well as spleen white pulp hyperplasia due to non-specific immune-stimulation at all levels (arrow heads). Panel (V) Rat epididymis treated for 28 days with 200 mg/kg *P. yohimbe*. displaying tubules A, lined by spermatogenic series-B, with normal sequential maturation-C, and interstitial tissue spaces containing luminal spermatozoa. Each photomicrograph enlargement is 100 μ m.

Sections of the epididymis body from the experimental rats in the treatment groups (II, III, IV, and V) that were given increasing doses of a methanol extract of *P. yohimbe* root exhibits normal epididymal histological indices leading to enhancement of sequential maturation of epididymal sperm cells as shown in Plates 1: II-V resemblance of the control group (Plate 1, I).

DISCUSSION

Phytotherapeutic products derived from medicinal plants have gained widespread acceptance in primary healthcare, and were mistakenly thought to be safe simply because they are derived from nature (Vaghasiya *et al.*, 2011). Nonetheless, these bioactive plant products are presumed to be safe, with no adverse health effects, as a result, it is widely used for self-

medication (Ojatula, 2020). In general perspective, the relative organ weight is critical in determining whether the organ was injured or not; and changes in body weight gain and internal organ weights of experimental animals would reflect toxicity following toxic substance exposure (Carol, 1995). Changes in body weight are indicators of drug and chemical side effects, as well as an important indicator of physiological and pathological status in animals (Raza *et al.*, 2002). The relative and absolute organ weight in both the control and treated groups increased non-significantly ($P > 0.005$) in this study, indicating that the extract nurtured the organ. Meanwhile, when compared to control, administration of the extract had no negative effect on organ weight in all treated rats. As a result, it can be concluded that *P. yohimbe* methanol root extract was almost nontoxic, rather, it enhanced immune protection in experimental rats, resulting in sequential maturation of epididymal sperm cells. These findings agree with the work of Ojatula (2020) who undertook a study on spermatogenic efficacy of *Pausinystalia yohimbe* roots in male rats.

Plants, in particular, make significant contributions to the list of natural products used as drugs, and are an important source of many standard drugs used in the treatment and management of human and animal diseases and disorders (Ojatula, 2019b; Newman and Cragg, 2020). A plant-derived natural product plays critical immune-protective roles against oxidative stress in vertebrate gonadal tissue (Ojatula, 2020). Furthermore, the male reproductive and immune systems have a close functional relationship (Hedger, 2015). Immunological responses to sperm antigens or other reproductive tract elements can result in androgen deficiency, infertility, or chronic inflammation of the epididymal layers (Hedger, 2015). Medicinal plants, according to the findings of Ojatula (2020), have been used to alleviate such systemic responses by interfering with the development of spermatogenic cells and the formation of sperm antibodies, resulting in increased sperm motility and count. The epididymis, testis, and other sex organs comprise the male reproductive system. During reproductive processes, their primary function is to generate spermatozoa capable of fertilizing an ovum (Ojatula and Enoyoze, 2023), in addition to providing a habitat for spermatozoa growth and maturation (Obianime *et al.*, 2010). Compounds that change the shape and function of the epididymis may have a significant impact on the quality and quantity of spermatozoa (Obianime *et al.*, 2010). Some plants are known to contain components that can cause negative systemic effects in both animal and human epididymis, resulting in spermatozoa malformation (Oyeyemi *et al.*, 2007). The epididymis is a convoluted tubule connecting the testis to the vas deferens, is in charge of spermatozoa maturation, transport, and storage, as well as sperm concentration and transport, and immune protection for male gametes (Cornwall, 2009). Spermatozoa must be exposed to the epididymal environment, which is controlled by its epithelium and testicular androgens, in order to acquire fertilizing capacity (Johnson *et al.*, 2000). The protein secreted by the epididymal principal cell has been shown to regulate sperm maturation (Amann, 1989), as well as maturing and storing sperm, epididymal tubules transport sperm during ejaculation (Ojatula, 2020). The epididymal epithelium's functions, which include absorption, secretion, synthesis, and metabolism, contribute to the development of a suitable luminal environment for spermatozoa motility and fertilizing ability (Turner, 1991). Hinton (1990) and Hedger (2015) previously demonstrated that spermatozoa acquire their fertilizing ability and forward motility during epididymal transit; and that sperm maturation implies the changes that the transiting male gamete undergoes (Ojatula, 2022; Ojatula and Nwanja, 2023; Ojatula and Enoyoze, 2023). As a result, the structural and functional integrity of sperm is critical for fertilization and the quality of progeny (Cooper and Yeung, 2006).

The histological evaluation performed in this study revealed that the plant induced varying degrees of normalcy of epididymal sperm cells in sequential maturation without any lesion

or spermatogenic pathological degeneration, and as a result, the synthesis for spermatozoa maturation was unaffected. This agrees with the findings of Turner *et al.* (1995) while they were studying the *in-vivo* influence of protein synthesis and secretion by the rat caput epididymidis on the luminal microenvironment. Hence, the immune-protection exhibited by the extract on the experimental rats' epididymal tissue spaces of the spermatogenic cells. This study's findings are consistent with those of Ojatula (2020), while working on spermatogenic efficacy of *Pausinystalia yohimbe* at a given graded doses of concentrations. Furthermore, a higher luminal spermatogenic population was found in the interstitial tissue spaces of the epididymis of extract-treated rats (particularly the 200 mg/kg body weight) in comparison to control rats. The pattern observed in this study on sequential sperm cell maturation was consistent with the plant's effect. The quantifiable presence of bioactive compounds determined in medicinal plants that aided in immune response could lead to increased testosterone production, and as well, explain the histological normalcy observed in the epididymises of rats in the study, which may be responsible for normal reproductive visceral organ architecture. This may result in the regulation of spermatogenesis and Sertoli cell functions, as both testosterone and follicle stimulating hormone (FSH) bind to Sertoli cell receptors (Ojatula *et al.*, 2020). This study's epididymal histology findings, compare favorably to a previous study by Verma and Chinoy (2002) who discovered that oral administration of *Carica papaya* ethanol extract had no negative effect on the caudal epididymal histological profile of experimental rats.

CONCLUSION

Overall, this study found that *P. yohimbe* has a potential fertility and immune-protection enhancing effect based on the administered doses and duration without causing lesion or degeneration in the epididymal architecture of animals, resulting sequential maturation of epididymal sperm cells. In the search for a male fertility agent, more research light may be focused on *P. yohimbe* in order to discover its full potential. However, caution should be exercised in its use as a medicinal agent.

Acknowledgements

The authors would like to thank Dr. G. Benjamen and Prof. H. Eze of the Department of Anatomy, University of Benin, Nigeria, for their assistance, technical and analytical assistance.

Conflicting Interest

This manuscript contains no conflicts of interest.

Authors Declaration

The authors hereby declare that the work presented in this article is their own and that they will not be held liable for any claims based on the content of this article.

REFERENCES

- Anderson, R.A., Willis, B.R., and Oswald, C. (1983). Ethanol induced male infertility impairment of spermatozoa. *Journal of Pharmacology and Experimental Therapeutics*, 225: 479-485.
- Amann, R.P. (1989). Structure and function of the normal testis and epididymis. *Journal of the American College of Toxicology*, 8(3): 457-471.
- Carol, S.A. (1995). Acute, subchronic and chronic toxicology. In: Michael, J.D. and Mannfred, A.H. (Eds). *CRC Handbook of Toxicology*. CRC Press Inc.: Boca Raton, FL, USA. pp. 51-104.

- Cooper, T.G. and Yeung, C.H. (2006). Sperm maturation in the human epididymis. *In: De Jonge C and Barratt C. (Eds). The Sperm Cell Production, Maturation, Fertilization, Regeneration.* Cambridge University Press, Cambridge. pp. 72-107.
- Cornwall, G A. (2009). New insights into epididymal biology and function. *Human Reproduction Update*, 15(2): 213-227.
- Erhabor, J.O., Idu, M. and Ojatula, A.O. (2015). Ethnomedicinal survey of plants used in the treatment of male sexual dysfunction among the Ilaje people of Ondo state, Nigeria. *In: Kumar, S. (Ed.) Recent Advances in Ethnobotany.* Deep publications, Paschim Vihar, New Delhi, India. pp. 16-21.
- Hedger, M.P. (2015). The immune-physiology of male reproduction. *Knobil and Neill's Physiology of Reproduction*, 201: 805-892.
- Hinton, B.T. (1990). The testicular and epididymal luminal amino acid micro- environment in the rat. *Journal of Andrology*, 11: 498-505.
- Johnson, L., Varner, D.D., Roberts, M.E., Smith, T.L., Keillor, G.E. and Scrutchfield, W.L. (2000). Efficiency of spermatogenesis: a comparative approach. *Animal Reproductive Science*, 60(61): 471-480.
- National Research Council [NRC] (1996). Guide for the Care and Use of Laboratory Animals. National Academic Press, Washington DC. 99p.
- Neel, J.A., Grindem, C.B. and Bristol, D.G. (2007). Introduction and evaluation of virtual microscopy in teaching veterinary cytopathology. *Journal of Veterinary Medicine and Education*, 34(4): 437-444.
- Newman, D.J. and Cragg, G.M. (2020). Natural products as sources of new drugs over the nearly four decades from 01/1981 to 09/2019. *Journal of Natural Products*, 83(3): 770-803.
- Obianime, A.W., Aprioku, J.S. and Esomonu, C.T.O. (2010). Antifertility effects of aqueous crude extract of *Ocimum gratissimum* L. leaves in male mice. *Journal of Medicinal Plants Research*, 4(9): 809-816.
- Ojatula, A.O. (2019). Biomolecules and phytominerals profiling of *Pausinystalia yohimbe* (K. Schum.) Pierre ex Beille root extract. *Journal of Functional Materials and Biomolecules*, 3(2): 312-316.
- Ojatula, A. O. (2019b). Effects of *Pausinystalia yohimbe* methanol root extract on some cardiovascular and haematological variables in wistar rats *International Journal of Progressive Sciences and Technologies*, 18(1): 142-147.
- Ojatula, A.O. (2020). Spermatogenic efficacy of *Pausinystalia yohimbe* (K. Schum.) Pierre ex Beille roots in male rats. *Journal of Infertility and Reproductive Biology*, 8(2): 9-17.
- Ojatula, A.O., Idu, M. and Timothy, O. (2020). Aphrodisiac potentials of *Pausinystalia yohimbe* (K. Schum.) Pierre ex Beille methanol root extract in male wistar rats. *Journal of Integrative Nephrology and Andrology*, 7(2): 47-55.
- Ojatula, A.O. (2022). Methanol Root Extract of *Pausinystalia yohimbe*, an aphrodisiac influences morphology of sperm cells in male wistar rats. *Journal of Current Biomedical Research*, 2(3): 160-170.
- Ojatula, A.O. and Enoyoze, G.E. (2023). Aqueous root extract of *Psidium guajava* exhibits dependent effects on aphrodisiac indices, reproductive hormones and spermatogenesis of male Wistar rats. *Journal of Pharmacy and Allied Medicine*, 1(1): 07-19.
- Oyeyemi, M.O., Ajala, O.O., Leigh, O.O. and Adesiji, T.F. (2007). The spermogram of male wistar rats treated with aqueous leaf extract of *Vernonia amygdalina*. *Folia Veterinary*, 51(34): 126-129.
- Paramitha, D. and Hermawan, H. (2017). Histological analysis: monitoring and evaluation of biomaterials and their performance *in vivo*. *Journal of Toxicology*, 10: 251-289.

- Raza, M., Al-Shabanah, O.A., El-Hadiyah, T.M. and Al-Majed, A.A. (2002). Effect of prolonged vigabatrin treatment on haematological and biochemical parameters in plasma, liver and kidney of Swiss albino mice. *Science and Pharmacy*, 70: 135-145.
- Rodriguez, C.M., Kirby, J.L. and Hinton, B.T. (2002). The development of the epididymis. *In*: Robaire, B. and Hinton, B.T. (Eds.). *The Epididymis: From Molecules to Clinical Practice*. Kluwer Academic/Plenum Publishers, New York. pp. 251–267.
- Turner, T.T., Miller, D.W. and Avery, E.A. (1995). Protein synthesis and secretion by the rat caput epididymidis *in vivo* influence of the luminal microenvironment. *Biology and Reproduction*, 53: 1012-1019.
- Turner, T.T. (1991). Spermatozoa are exposed to a complex microenvironment as they traverse the epididymis. *Annals of New York Academic Science*, 637:364–383.
- Vaghasiya, Y.K., Shukla, V.J. and Chanda, S.V. (2011). Acute oral toxicity study of *Pluchea arguta* boiss extract in mice. *Journal of Pharmacology and Toxicology*, 6, 113-123.