

Common conjunctival lesions

Conjunctival lesions present commonly in primary care.

J F Olivier, MB ChB, MRCOphth (UK), MMed (Ophth)

Department of Ophthalmology, University of Limpopo, MEDUNSA Campus, Dr George Mukhari Hospital, Pretoria, South Africa

Correspondence to: J F Olivier (olivierjf@yahoo.co.uk)

Conjunctival lesions are frequently seen in the eye clinic, because the conjunctiva is readily seen and patients notice any change in their ocular appearance. This discussion does not attempt to classify lesions, but only highlights some of the more common lesions that are seen.

The conjunctiva is a translucent mucous membrane that covers the anterior part of the globe and has three portions:

- the bulbar conjunctiva that covers the sclera and includes the corneo-conjunctival limbus
- the conjunctival fornix
- the tarsal part covering the posterior surface of the upper and lower lid.

The epithelium contains goblets cells and scattered melanocytes. The stroma is a fibrovascular connective tissue that contains collagenous and elastic tissue as well as arteries, veins, lymphatics, nerves and lymphoid tissue. The caruncle on the nasal canthus contains both conjunctival and cutaneous structures and tumours can be of skin or mucosal origin.

Always test the visual acuity, look at the cornea and feel for pre-auricular and submandibular lymph nodes.

History

Obtain a full medical and ocular history. In the consulting room the conjunctiva can be examined with a bright light and magnifying glass. Examine what you can see and evert the upper lid to look at the tarsal conjunctiva. Always test the visual acuity, look at the cornea and feel for pre-auricular and submandibular lymph nodes.

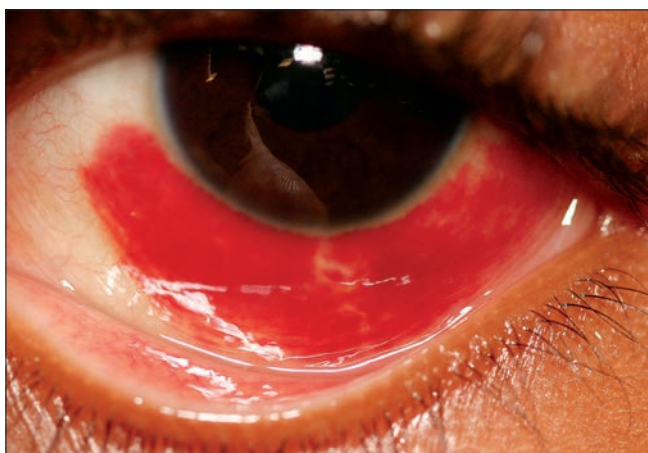

Fig. 1. Subconjunctival haemorrhage.

Subconjunctival haemorrhage (Fig. 1)

This usually occurs as an isolated finding without any obvious cause. It may result from even minor trauma, conjunctivitis, coughing or in patients who are on anticoagulants. The eye is red and visual acuity is usually normal. The haemorrhage resolves slowly and symptomatic treatment, such as lubrication, is used. Treat any underlying medical condition, and where severe blunt force trauma has occurred the patient needs to be referred.

Vernal keratoconjunctivitis (VKC) (Fig. 2)

This condition occurs mainly in warmer climates among younger people and is more common in boys. It frequently occurs in our local black population and can be mild to severe. There is a hypersensitivity reaction to exogenous antigens and an increase in serum levels of IgE. The symptoms are itching, photophobia, a gritty feeling under the eyelid, blurred vision and mucus discharge. There is a gelatinous thickening of the cornea at the limbus with pigment changes. In more severe cases there are limbal nodules and Horner-Trantas dots. In mild cases topical anti-histamine drops and mast cell stabilisers can be used. The more severe cases have to be referred to an ophthalmologist and intermittent topical steroids and immunomodulators, such as cyclosporine, are used.

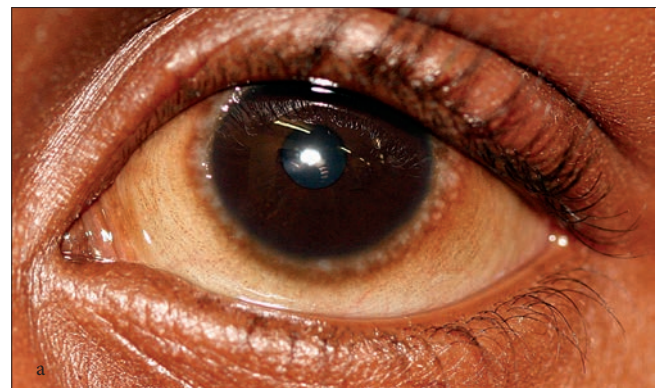


Fig. 2a. Vernal keratoconjunctivitis.

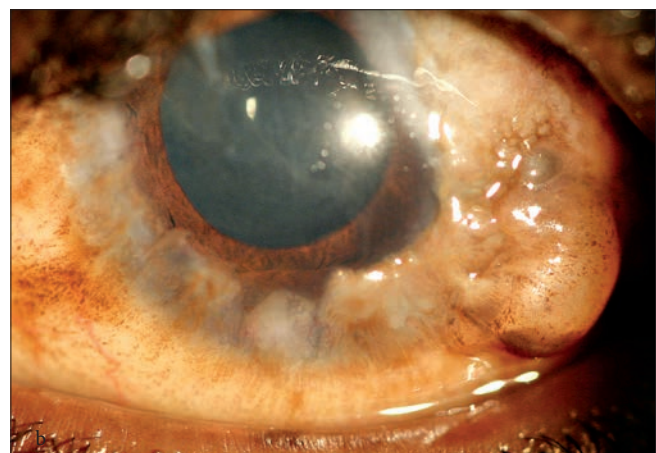

Fig. 2b. Severe vernal keratoconjunctivitis.

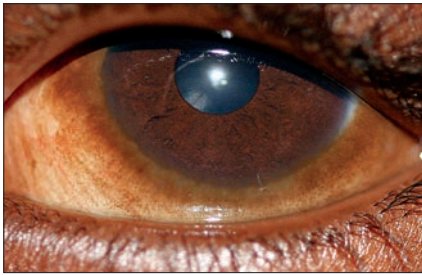


Fig. 3. Ocular melanosis.

Ocular melanosis/benign melanosis (Fig. 3)

This is a common bilateral condition of conjunctival pigmentation and is found mainly in the black population and in darkly pigmented individuals. It is present at the limbus for up to 360 degrees and at the exposed interpalpebral bulbar conjunctiva. Malignant transformation is extremely rare and occasional observation is recommended.

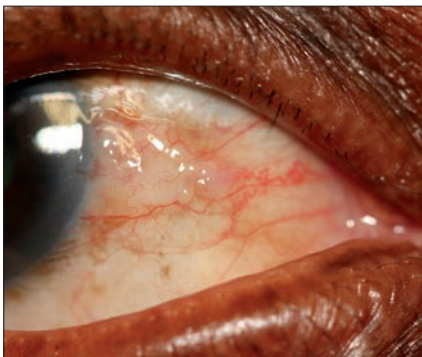


Fig. 4. Pingueculum.

Pingueculum (Fig. 4)

This is a common condition that is usually bilateral. There is a localised, elevated yellow-white area on the bulbar conjunctiva near the nasal limbus. No treatment is usually necessary but, in the case of inflammation, a weak steroid such as fluorometholone may be used. Do not confuse a pingueculum with conjunctival neoplasia. The patient should be referred if in doubt.

Pterygium (Fig. 5)

A pterygium is a triangular-shaped growth of conjunctival and fibrovascular tissue over the limbus and the superficial cornea. It occurs most often in hot climates and is usually present on the nasal limbus. The pterygium may cause irritation or a decrease in visual acuity owing to astigmatism or encroachment over the pupillary area. Initial treatment is with lubricant eye drops or mild topical steroids. Surgery is indicated

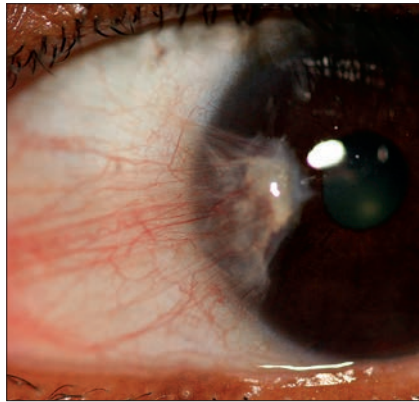


Fig. 5. Pterygium.

where vision is affected, if the pterygium looks suspicious or if it is cosmetically unacceptable.

Do not confuse a pingueculum with conjunctival neoplasia.

Limbal dermoid (Fig. 6)

A limbal dermoid is a congenital tumour that usually occurs at the inferotemporal limbus or globe. It is a smooth, circumscribed, yellow-white to brown lesion, that can have the appearance of skin. It may occur as part of the Goldenhar syndrome, when the child will need to have a paediatric consultation. Small lesions may be observed. Larger lesions that threaten visual acuity or are cosmetically unacceptable can be surgically removed.

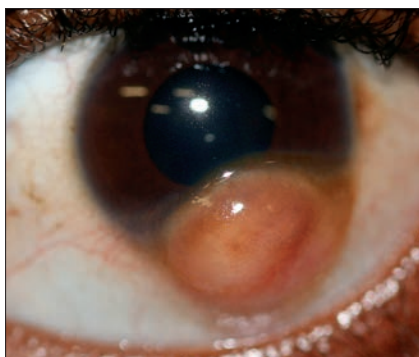


Fig. 6. Limbal dermoid.

Inclusion cyst (Fig. 7)

These cysts commonly occur in the lower fornix. They are lined with epithelial cells and usually filled with clear fluid. Simple puncture is not recommended and the cysts may re-form. Cauterisation of the surface, combined with larger incision and drainage,

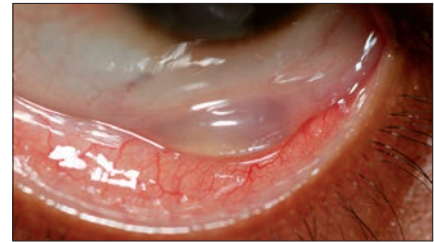


Fig. 7. Inclusion cyst.

will sometimes be sufficient. If it re-forms, excision of the cyst should be performed.

Conjunctival bleb (Fig. 8)

A conjunctival bleb is formed when there is a direct connection of the aqueous in the anterior chamber to the subconjunctival space. This bleb can be formed deliberately, e.g. in glaucoma surgery or after corneoscleral laceration repair. Ask the patient about any ocular trauma or surgery. It is extremely important never to try to puncture or deflate these cysts as it may lead to hypotonia of the eye or even endophthalmitis.

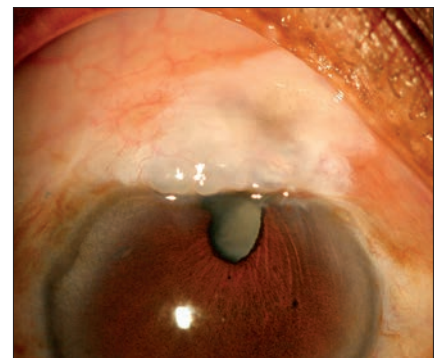


Fig. 8. Conjunctival bleb after trauma.

Pyogenic granuloma (Fig. 9)

The granuloma is an inflammatory lesion of the conjunctiva that usually appears after surgery or even minor trauma to the conjunctiva. It usually presents as a fleshy, fast growing, red, pedunculated and vascular mass, that bleeds easily. Steroid eye

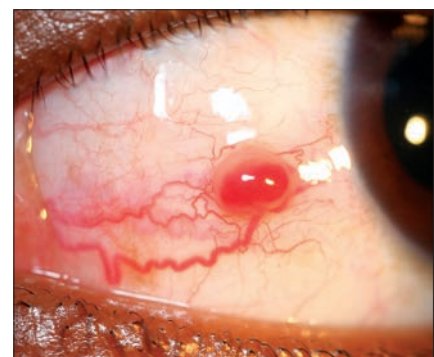

Fig. 9. Pyogenic granuloma.

drops usually clear the granuloma, but excision and cauterisation may be needed.

Conjunctival papilloma (Fig. 10)

There are two forms of conjunctival papillomas. They differ in their aetiology, histology and clinical appearance. An infection with the human papilloma virus causes a pedunculated, wart-like lesion. Such lesions may be multiple and appear in the caruncle or fornix. The sessile papilloma is more frequently on the bulbar or juxtalimbal conjunctiva. The smaller pedunculated papilloma may disappear spontaneously. Because of the possibility of malignant transformation it is best to refer all these patients to an ophthalmologist for possible excision and adjuvant treatment.

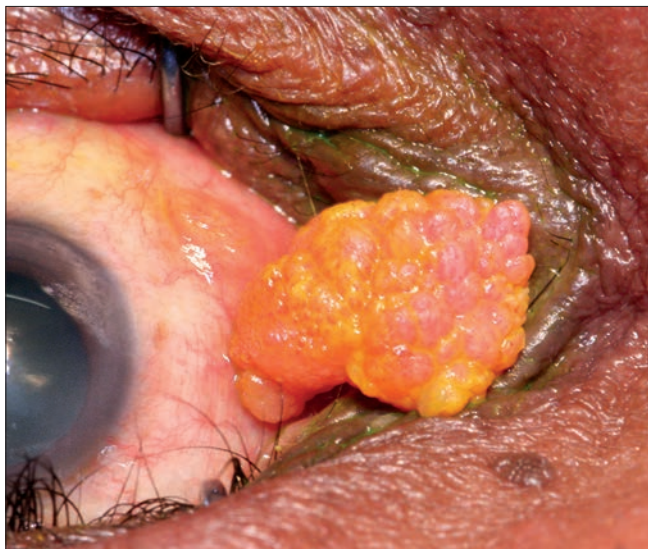

Fig. 10. Pedunculated papilloma of the caruncle (stained with fluorescein).

Conjunctival naevus (Fig. 11)

Conjunctival naevi are common and are located in the interpalpebral bulbar conjunctiva close to the limbus or at the caruncle. The naevus is a discrete, flat or slightly elevated sessile lesion. The colour can be from pale to brown to a dark black. If present from birth to 6 months it is considered a congenital naevus. Acquired naevi usually develop in the first 2 decades and may change colour during adolescence. The potential for malignant transformation is low and serial observation with photographic documentation is indicated. Any change in size or colour after adolescence or unusual location, as in the palpebral

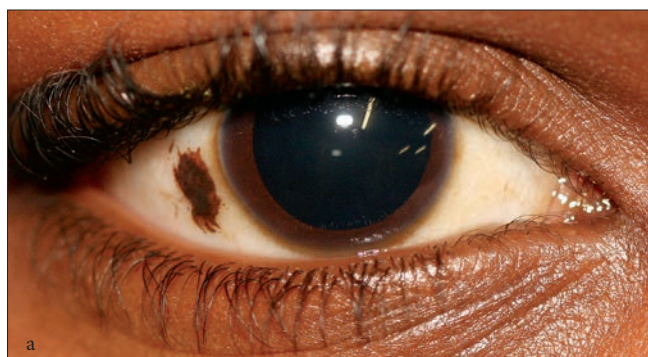

Fig. 11a. Conjunctival naevus.

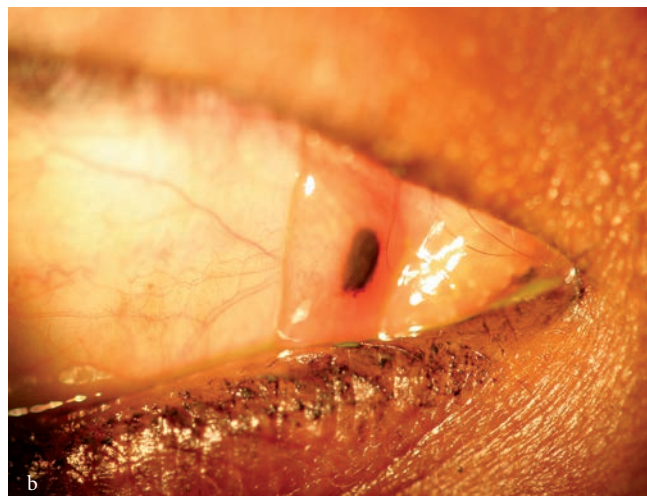


Fig. 11b. Caruncle naevus.

conjunctiva, should be regarded with suspicion and be properly evaluated.

Kaposi sarcoma (Fig. 12)

Kaposi sarcoma is better known as a cutaneous malignancy, but in areas of high HIV prevalence it occurs in mucous membranes, including the conjunctiva. It is a highly vascularised, red, gelatinous lesion, that may look like a subconjunctival haemorrhage. The patient needs a full medical examination to look for sarcomas in other areas of the body, and HIV testing if status is not known. Kaposi sarcoma reacts well to low-dose irradiation.

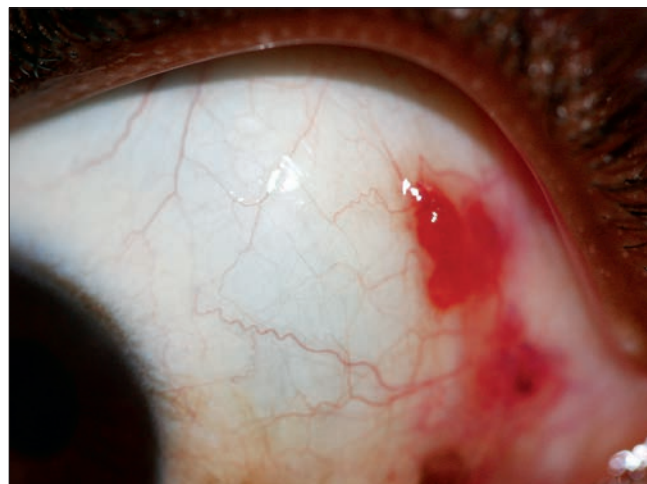


Fig. 12. Kaposi sarcoma.

Squamous cell carcinoma (Fig. 13)

Squamous cell carcinoma is very common in areas of high HIV prevalence. The tumour occurs at a significantly younger age in HIV-positive patients. In older individuals the tumour is related to UV light exposure. It commonly occurs on the interpalpebral bulbar conjunctiva close to the limbus. The appearance of the tumour ranges from flat to nodular to papillomatous. There can be various levels of pigmentation and the surface can be necrotic. The tumour can infiltrate the cornea and underlying sclera and usually has prominent feeder vessels. It is very aggressive in immuno-

Common conjunctival lesions

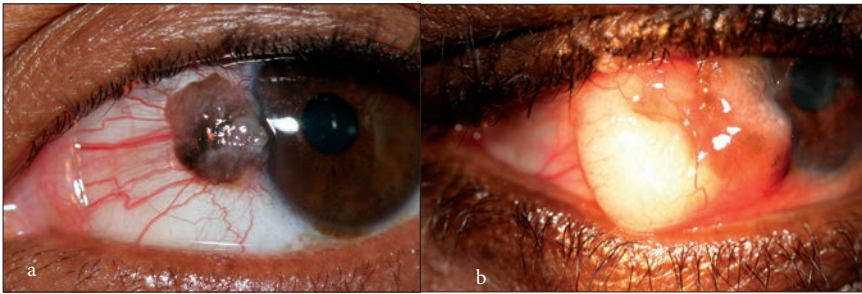


Fig.13a. Squamous cell carcinoma.

Fig. 13b. Extensive squamous cell carcinoma.

compromised patients and needs prompt treatment. All suspected cases should be referred immediately to an ophthalmologist for treatment, which includes excision and cryotherapy. Recurrence is possible. The tumour is locally invasive and may need

enucleation of the eye or even exenteration of the orbital contents.

Conclusion

Conjunctival lesions are frequently seen. They are generally easily visible and can be

examined without difficulty. A definitive diagnosis should be made in all cases. It is always better to refer patients with conjunctival lesions for the appropriate treatment plan to be initiated.

Further reading

Basic and Clinical Science Course, American Academy of Ophthalmology, Section 8. External Disease and Cornea, 2009-2010. San Francisco, CA: American Academy of Ophthalmology, 2010.
Ehlers J, Shah C. The Wills Eye Manual. Office and Emergency Room Diagnosis and Treatment of Eye Disease. 5th ed. Philadelphia: Lippincott, Williams and Wilkins, 2008.
Kanski JJ, Bowling B. Clinical Ophthalmology. A Systematic Approach. 7th ed. Philadelphia: Elsevier, 2007.
Singh AD. Clinical Ophthalmic Oncology. Philadelphia: Saunders, 2007.
Yanoff M, Duker JS. Ophthalmology. 3rd ed. Philadelphia: Mosby, 2009.

IN A NUTSHELL

- Conjunctival lesions are frequently seen in the eye clinic.
- In the consulting room the conjunctiva can be examined with a bright light and magnifying glass.
- Always test the visual acuity, look at the cornea and feel for pre-auricular and submandibular lymph nodes.
- Subconjunctival haemorrhage usually occurs as an isolated finding without any obvious cause.
- Vernal keratoconjunctivitis occurs mainly in warmer climates among younger people and is more common in boys.
- Ocular melanosis/benign melanosis is a common bilateral condition of conjunctival pigmentation.
- Pingueculum is a common condition that is usually bilateral.
- A pterygium is a triangular-shaped growth of conjunctival and fibrovascular tissue over the limbus and the superficial cornea. It occurs most often in hot climates and is usually present on the nasal limbus.
- A limbal dermoid is a congenital tumour that usually occurs at the inferotemporal limbus or globe.
- Inclusion cysts commonly occur in the lower fornix.
- A conjunctival bleb is formed when there is a direct connection of the aqueous in the anterior chamber to the subconjunctival space.
- Pyogenic granuloma is an inflammatory lesion of the conjunctiva, usually following surgery or even minor trauma to the conjunctiva.
- There are two forms of conjunctival papillomas. They differ in their aetiology, histology and clinical appearance.
- Conjunctival naevi are common and are located in the interpalpebral bulbar conjunctiva close to the limbus or at the caruncle.
- Kaposi sarcoma is better known as a cutaneous malignancy, but in areas of high HIV prevalence it occurs in mucous membranes, including the conjunctiva.
- Squamous cell carcinoma is very common in areas of high HIV prevalence. The tumour occurs at a significantly younger age in HIV-positive patients.