

# Raised intracranial pressure: What it is and how to recognise it

*This article presents an approach to raised intracranial pressure (ICP) constructed in a question-answer fashion. It is not intended to be a comprehensive review of a complex subject, but rather an 'easy-access quick overview' to provide practical information on the physiology, pathology and management of raised ICP for the busy practitioner.*

D Roytowski, MB ChB, MBA (INSEAD); A Figaji, MB ChB, MMed, PhD, FCNeurosurg (SA)

Division of Neurosurgery, University of Cape Town and Institute for Child Health, Red Cross War Memorial Children's Hospital, Cape Town, South Africa

Corresponding author: D Roytowski (docdave@gmail.com)

## What is raised intracranial pressure?

Intracranial pressure (ICP) is the tension within the cranial vault. Typically recorded in millimetres of mercury (mmHg), ICP in adults is normally 5 - 10 mmHg, in children 3 - 7 mmHg, and in infants 1.5 - 6 mmHg.<sup>[1]</sup> The mmHg value is multiplied by 1.36 to determine the equivalent value in cmH<sub>2</sub>O. This is usually

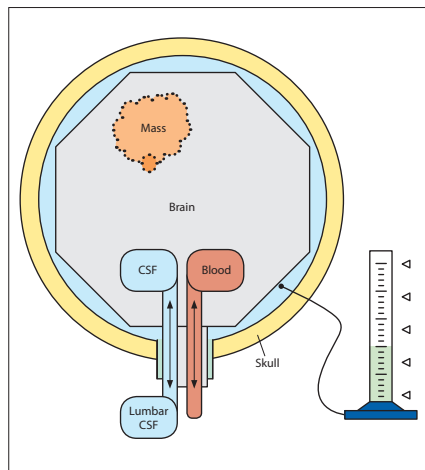


Fig. 1. Representation of the cranial constituents.

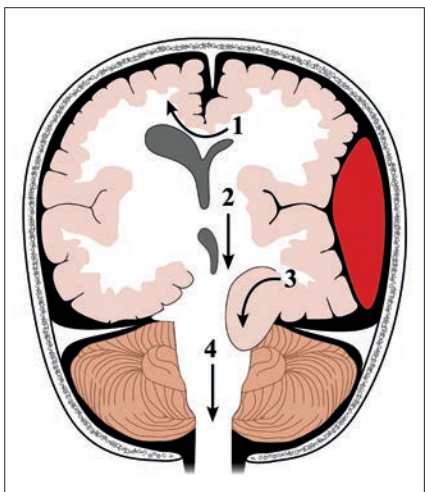


Fig. 2. Sites of brain herniation. 1: subfalcine; 2: tentorial; 3: uncus (transtentorial); 4: tonsillar.

obtained when using a manometer after lumbar puncture. ICP varies over the course of the day and is influenced by changes in posture, position and pressure fluctuations in other compartments (e.g. a Valsalva manoeuvre will markedly increase the resting ICP). Raised ICP can be defined in many ways, but in the acute setting it commonly refers to pressure greater than 20 - 25 mmHg for more than 5 minutes.

The skull is a rigid container with 3 key component constituents – brain tissue, cerebral blood and cerebrospinal fluid (CSF). The Monro-Kellie doctrine states that the sum of intracranial volumes is constant and therefore an increase in any one of these compartments must be offset by an equivalent decrease in the other two (Fig. 1).

Under normal conditions the pressure within the cranial space is in equilibrium. Should pressure from one constituent increase, compensation occurs (up to a point) by reduction in volume of another constituent and a subsequent rise in ICP. This generally involves shifts of CSF and venous blood out of the cranium to compensate for the added volume. Once this compensatory reserve is exhausted, pressure increases and brain shifts may occur and result in herniation (Fig. 2).

The compliance curve is expressed by plotting the ICP against an expanding volume. Once the compensatory reserve is exceeded the

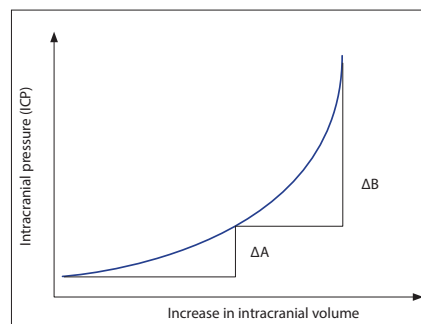


Fig. 3. Intracranial compliance curve.

increase in pressure for a given increase in volume will rise dramatically (Fig. 3).

## Why is ICP important?

Raised ICP is the final common pathway that leads to death or disability in most acute cerebral conditions. It is also potentially treatable. The two major consequences of increased ICP are:

- brain shifts
- brain ischaemia.

Cerebral perfusion pressure (CPP) is the calculated difference between the mean arterial pressure (MAP) and the ICP.  $CPP = MAP - ICP$ .

## Why is CPP important?

The CPP is the main determinant of cerebral blood flow (CBF). Normally CBF is coupled to metabolic demand of tissue, with normal flow greater than 50 ml/100 g/min. Less than 20 ml/100 g/min is considered the ischaemic threshold. The process of cerebral autoregulation maintains CBF between a CPP range of approximately 50 - 150 mmHg.<sup>[2,3]</sup> Outside these ranges CBF becomes pressure-dependent. As shown in Fig. 4, when CPP is less than the lower threshold for autoregulatory compensation, CBF progressively decreases with CPP, resulting in ischaemia.

## What are the causes of raised ICP?

Several conditions cause raised ICP, either by increasing one or more of the constituents of the intracranial cavity or by introducing a non-native mass to the cranial space (see Table 1).

Raised ICP is typically caused by one of the following four mechanisms:

- cerebral oedema (brain tissue)
- vascular (congestive) brain swelling
- hydrocephalus (CSF)
- mass lesion.

## How do I recognise raised ICP?

The presenting circumstances, coupled with a high degree of suspicion, should guide efforts to diagnose raised ICP. However, it can be very difficult to conclusively exclude raised ICP on clinical grounds, so delayed diagnoses and inappropriate management are unfortunately common. Early diagnosis is important for several reasons:

- delay in diagnosis increases morbidity
- inappropriate management (e.g. lumbar puncture) may worsen the condition.

## ICP varies over the course of the day and is influenced by changes in posture, position and pressure fluctuations in other compartments.

The history should guide the clinician in assessing the risk of raised ICP, even in the absence of key neurological signs.

Establish the patient's level of consciousness – the Glasgow Coma Scale (GCS) is widely used to reliably grade the level of consciousness (Table 2). Critically raised ICP causes a depressed level of consciousness and, depending on the cause, may require emergent neurosurgical intervention. Keep in mind, however, that causes of chronically increased ICP may first present insidiously. Intracranial volume may increase steadily over months with no change in the level of consciousness, and yet present dramatically with an acute deterioration of consciousness when intracranial compliance is finally exhausted. Acutely increased ICP may present with rapidly deteriorating consciousness without focal neurological signs or papilloedema. Therefore absence of the latter does not exclude increased ICP. Meningism,

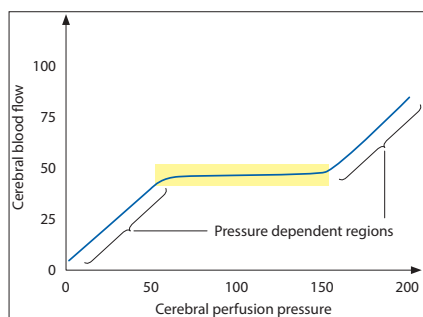


Fig. 4. Cerebral autoregulation.

commonly associated with the meningeal irritation of meningitis, may be mistaken for neck stiffness associated with impending tonsillar herniation. A lumbar puncture under these circumstances could prove fatal.

Headache, vomiting and visual disturbances are common symptoms of raised ICP. Diplopia may occur due to cranial nerve palsies – the 6th cranial nerve is particularly vulnerable to stretch while the 3rd cranial nerve is at risk because herniation of the medial temporal lobe through the tentorial notch stretches the nerve as it exits the midbrain. Palsy of the 3rd cranial nerve tends to be on the side of the lesion, whereas palsy of the 4th cranial nerve is non-localising.

The downward displacement of the brainstem and upper cervical cord through the foramen magnum causes compression on structures that control cardiac and respiratory function. Critical compression may result in Cushing's triad of increased systolic pressure (including widened pulse pressure), bradycardia and irregular breathing.

Several brain herniation syndromes have been described.<sup>10</sup> Should the patient present with any of these, urgent consultation with a neurosurgeon is mandatory.

### Tentorial herniation (lateral)

- Third nerve palsy (ptosis, poorly reactive pupil, reduced eye movements)

**Table 1. Common pathologies that result in raised intracranial pressure<sup>[4]</sup>**

Hydrocephalus	Congenital or acquired Non-communicating or communicating
Brain tumour (primary or secondary, benign or malignant)	Secondary hydrocephalus (mass causing blockage of CSF pathways) Mass effect Oedema
CNS infections	Meningitis Encephalitis Abscess Secondary hydrocephalus Mass effect
Trauma	Intracranial haematoma (extradural, subdural, intracerebral) Diffuse brain swelling
Cerebrovascular	Subarachnoid haemorrhage Intracerebral haematoma Intraventricular haemorrhage Secondary hydrocephalus Venous thrombosis Cerebral infarct Hypertensive encephalopathy (malignant hypertension, eclampsia)
Metabolic encephalopathy	Hypoxic-ischaemic Hepatic coma Renal failure Diabetic ketoacidosis Near drowning Hyponatraemia
Status epilepticus	
Cranio-cerebral disproportion	
Developmental lesions	Arachnoid cyst Epidermoid cyst
Idiopathic intracranial hypertension	

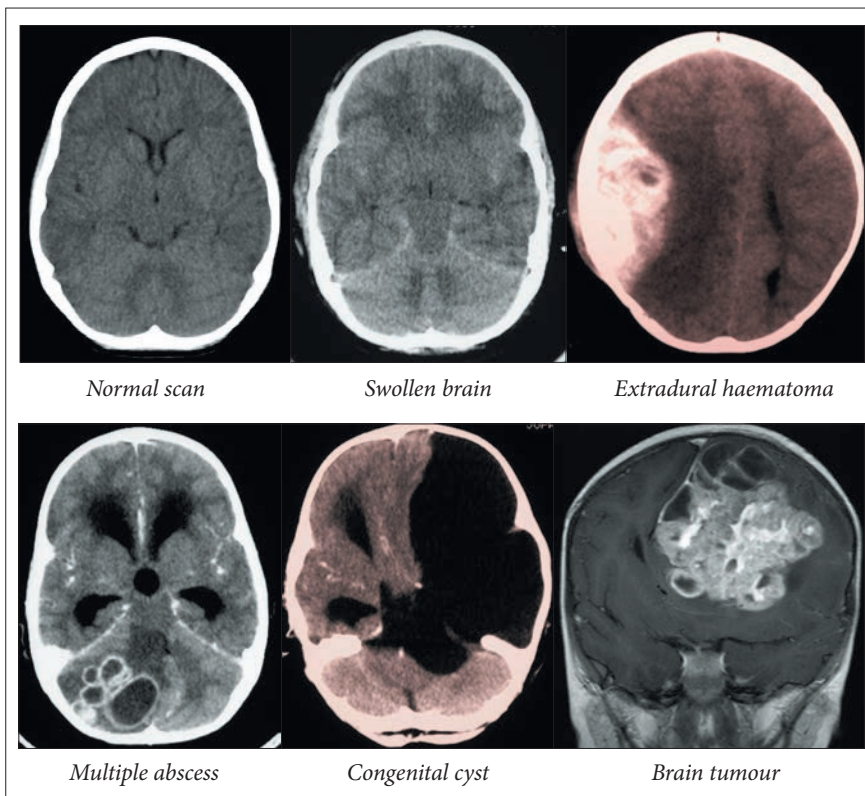


Fig. 5. Selected images of intracranial pathology resulting in raised ICP.

**Table 2. Glasgow Coma Scale**

Eye opening		Verbal response		Motor response	
Spontaneous	4	Orientated	5	Obeys commands	6
To verbal command	3	Inappropriate	4	Localises to pain	5
To painful stimulus	2	Incomprehensible	3	Flexion	4
None	1	Makes sounds	2	Abnormal flexion	3
		None	1	Extension	2
				None	1

- False localising (ipsilateral) hemiparesis (Kernohan's notch)
- Depressed level of consciousness from reticular formation compression
- Potentially posterior cerebral artery occlusion resulting in a homonymous hemianopia.

### Tentorial herniation (central)

- Upward gaze palsy results from compression on the preectum and superior colliculi
- Deteriorating level of consciousness as the blood supply of the diencephalon and midbrain perforating vessels is compromised
- Diabetes insipidus can follow traction placed on the pituitary stalk and hypothalamus.

### Tonsillar herniation

- Neck stiffness as cerebellar tonsils compress against the foramen magnum (as opposed to meningism from meningitis – beware of performing a lumbar puncture in the patient with tonsillar herniation)
- Elevated blood pressure and slowed pulse rate indicate progressive brainstem compression
- Depressed level of consciousness and respiratory arrest will follow persistent compression.

Interrogation about vision and examination of the pupils and fundi are extremely valuable in assessing the likelihood of raised ICP. Several symptoms and signs have been described:

- Visual obscurations are transient losses of vision lasting a few seconds, occurring with

raised ICP, particularly when associated with activities that increase ICP (coughing, sneezing, bending down, straining at stool) and relieved by their cessation. These symptoms are thought to reflect critical compromise of optic nerve head perfusion and are typically associated with the finding of papilloedema.

- Retinal venous pulsation is evident at the margin of the disc in the normal retina when observed with an ophthalmoscope. Venous pulsation is lost when ICP exceeds venous pressure. This is an initial marker of raised ICP, and may be an early sign of impending papilloedema.<sup>16]</sup>
- Papilloedema is swelling (oedema) of the optic nerve head due to raised ICP:
  - acute stage: oedema at the superior and inferior poles of the disc, absence of spontaneous venous pulsation, and enlargement of the blind spot
  - progressive: the whole disc is involved and splinter haemorrhages may be evident at the disc margin
  - chronic stage: gliosis of the optic nerve head and eventually optic atrophy with nerve fibre damage and permanent visual field defect.
- Hutchinson's pupil is unilateral pupillary dilatation ipsilateral to a supratentorial (usually extrinsic) space-occupying lesion. This may be the earliest sign of raised ICP and brain shift, but is a sign of imminent clinical deterioration. It reflects involvement of peripheral pupilloconstrictor fibres in the oculomotor (III) nerve, as a result of compression on the margin of the tentorium.
- Kernohan's notch syndrome raised ICP as a result of an expanding supratentorial lesion (e.g. tumour, haematoma) may cause herniation of brain tissue through the tentorium into the subtentorial space, putting pressure on the midbrain. If the midbrain is shifted against the contralateral margin (free edge) of the tentorium, the cerebral peduncle on that side may be compressed, resulting in a hemiparesis which is ipsilateral to the supratentorial lesion (and hence may be considered 'false-localising'). There may also be oculomotor nerve palsy ipsilateral to the lesion, which may be partial (unilateral pupil dilatation).

The presenting history and clinical situation should guide the choice of investigations. Invariably patients with a depressed level of consciousness will require imaging of

the brain. The clinical situation determines how soon imaging should take place and the choice of imaging. In most cases, but not all, the diagnosis of raised ICP and the aetiology thereof are clear from the imaging.

For trauma, an emergency CT of the head is performed as soon as the patient is resuscitated. If the presenting history includes a seizure, a contrast-enhanced CT or MRI will be more useful. If vascular pathology is suspected, angiography may also be indicated. When raised ICP is suspected for any reason, it is important not to perform a lumbar puncture prior to a CT scan that would indicate if it is probably safe to do so.

**The presenting circumstances, coupled with a high degree of suspicion, should guide efforts to diagnose raised ICP. However, it can be very difficult to conclusively exclude raised ICP on clinical grounds, so delayed diagnoses and inappropriate management are unfortunately common.**

Where meningitis is suspected, a blood culture and septic marker screen (full blood count, C-reactive protein, erythrocyte sedimentation rate) can be taken and antibiotics started immediately. Do not delay antibiotics until after CSF sampling has been performed. If a subarachnoid haemorrhage is suspected, the presentation of which is not easy to distinguish from spontaneous intracerebral haematomas, the first investigation is brain imaging, not a lumbar puncture. If the diagnosis is not clear from the imaging then a lumbar puncture can be considered. The diagnosis of infectious mass lesions (empyema, abscess) requires a search for the origin of the lesion. Table 3 lists the contraindications to lumbar puncture.

**Table 3. Contraindications to lumbar puncture<sup>[7-9]</sup>**

- Major contraindication is raised intracranial pressure
- Focal neurological deficit
- Papilloedema
- Significantly altered level of consciousness
- Computed tomography (CT) findings
  - lateral midline shift
  - loss of suprachiasmatic or basal cisterns
  - fourth ventricle effacement
  - obliteration of supracerebellar or quadrigeminal plate cisterns with patent ambient cisterns
- Presence of local infection at lumbar puncture site
- Coagulopathy
- Thrombocytopenia (platelet count <50 000)

### What management should I institute?

Identifying raised ICP and a possible aetiology, along with resuscitation of the patient where necessary, are the primary objectives of the initial treating physician. The goals in the acute setting are resuscitation, imaging and neurosurgical referral. In an unconscious patient, manage the patient according to Advanced Trauma Life Support (ATLS) protocols. Intubate and ventilate the patient to protect their airway if the GCS is 8 or less. An arterial blood gas will provide essential information regarding the patient's oxygenation, ventilatory and acid-base status. Avoid hyper- and hypoventilation – it is safest to aim for a PaCO<sub>2</sub> of 4 - 4.5kPa. Ensure adequate systemic oxygenation: target an oxygen saturation of at least 95% or a PaO<sub>2</sub> of at least 13 kPa. Maintain normal blood pressure – at all times avoid hypotension. Hypoxia and hypotension are potent secondary insults that worsen outcome. Be cautious about treating hypertension as this may be a Cushing's response – the brain may be dependent on an elevated BP. Grade the patient's consciousness after ensuring that the patient is haemodynamically stable. A detailed neurological exam should follow, with particular attention paid to pupil size and light reaction, fundoscopy, cranial nerve palsies, long tract signs, and potential spinal cord injury in the setting of trauma.

Place the patient with 15 - 30 degrees of head elevation in a neutral midline position to maximise cerebral venous return. Similarly,

avoid tight garments and tapings around the neck that cause jugular venous obstruction.

The goal of primary care management is to stabilise the patient and prevent secondary brain injury by ensuring rapid transfer to a neurosurgical centre. The use of osmotically active agents (e.g. mannitol) should only be prescribed in consultation with a neurosurgeon, and only as a temporising intervention until definitive treatment can be achieved. There is no place for repeated doses in the acute phase. Mannitol 0.5 g/kg can be given if there is evidence of coning (downward tonsillar herniation). Hypertonic saline may be a better option if this can be used safely. After the successful stabilisation and initial treatment, rapid transfer to a centre with neurosurgical and intensive care facilities is mandatory. When a patient has raised ICP, similar to stroke, one must recognise that 'time is brain'.

**Headache, vomiting and visual disturbances are common symptoms of raised ICP.**

When chronic raised ICP is suspected, early imaging is once again a priority. Further

management then depends on the probable definitive diagnosis.

### What is likely to happen next?

A CT/MRI scan aids in determining the cause of the raised ICP – most importantly surgically correctable causes such as haematomas, intrinsic masses and hydrocephalus that may warrant emergent surgical intervention. Raised ICP due to brain swelling may necessitate monitoring for several days in an ICU setting to guide therapy in trauma and medical causes of raised ICP. Hydrocephalus requires internal or external drainage. Mass lesions usually require surgical removal.

ICP can be measured by a number of modalities, commonly:

- an external ventricular drain inserted into the ventricular system and the pressure is transduced
- an ICP monitor is placed into the parenchyma, ventricular or subdural space and measured with a dedicated unit.

Pressure monitoring allows for the interpretation of an absolute value, a temporal response and waveforms. The waveforms result from systolic blood pressure pulsations transmitted in the intracranial cavity coupled with the effects of respiratory cycle on venous outflow. Lundberg A, B and C waveforms are identified as pathological.<sup>[10]</sup> Currently, there

are no forms of non-invasive ICP monitoring that are accurate enough for clinical use.

General principles of ICP treatment are to:

- maintain ICP less than 20 - 25 mmHg
- ensure a CPP greater than 60 mmHg (adults)
- avoid and treat factors that may elevate ICP.

Neurological critical care aims to avoid and treat factors aggravating and precipitating intracranial hypertension, and to reduce metabolic requirements. Basic measures include improving venous return (head positioning), sedation, optimising ventilation (avoiding hypoxia, hypo- and hypercapnia and airway obstruction), achieving a euvolaemic state, normotension and normothermia, while avoiding fever, pain, seizures (clinical and subclinical) and anaemia.

**When chronic raised ICP is suspected, early imaging is once again a priority. Further management then depends on the probable definitive diagnosis.**

### Medical interventions

#### Analgesia, sedation and paralysis

- Agitation and ventilator dysynchrony result in impaired venous return and aggravation of ICP.
- Adequate analgesia and sedation reduce agitation, Valsalva and metabolic demand.
- Agents that have the least effect on blood pressure are preferred to maintain acceptable CPP – short-acting benzodiazepines are frequently administered.
- Use anticonvulsants if there is a high risk of seizures.
- Thiopentone is sometimes used for refractory ICP: at adequate doses it causes burst suppression on EEG, reduced metabolic demand and therefore cerebral blood flow and cerebral blood volume, and hence ICP. However, thiopentone commonly reduces blood pressure.
- Propofol anaesthesia is being utilised in adults to reduce the metabolic demand for oxygen, with the added benefit of improving the seizure threshold.
- Rarely, ICP control necessitates the use of neuromuscular blockade (NMB)

(prolonged use of NMB is implicated in the development of myopathies and polyneuropathies).

#### Hyperosmolar therapy

- Hypertonic saline (HTS) is increasingly used rather than mannitol – it remains within the vascular compartment longer than mannitol and so is useful in treating the hypovolaemic patient. It also has a better reflection co-efficient across the blood-brain barrier (BBB), i.e. it tends to cross the BBB less. HTS can also be used to treat hyponatraemia, which untreated can worsen brain oedema. Ensure that serum sodium is not increased too rapidly.
- Mannitol lowers the ICP 1 - 5 minutes after intravenous administration, and its peak effect is at 40 minutes. Mannitol will cause an initial plasma expansion that should improve CBF. However, the BBB becomes permeable to mannitol and it may worsen vasogenic oedema.

#### Hyperventilation

- Hyperventilation reduces the partial pressure of carbon dioxide, which causes cerebral arteriolar constriction and, therefore, decreased cerebral blood volume, and so ICP.
- However, hyperventilation also often reduces cerebral blood flow and may worsen or induce ischaemia, and so is inadvisable as a general rule. Still, it may be useful to break a plateau wave of increased ICP. Paradoxically, this may increase oxygenation of the brain because of the reduction in ICP. This should be done only in a controlled neurocritical care setting. For resuscitation and stabilisation, it is best to aim for a PaCO<sub>2</sub> of 4 - 4.5 kPa. Remember to check the arterial blood gas; preferably also use end tidal CO<sub>2</sub> monitoring.

#### Hypothermia

- Hypothermia is not routinely used to treat raised ICP, although it may be considered where raised ICP is refractory to other forms of medical management. Current evidence from clinical trials does not support a clear benefit of hypothermia in head injury. However, for individual patients this may be worth trying. The evidence for benefit is stronger for patients who have had a cardiac arrest and for neonatal hypoxic ischaemia.

### Steroids

- Vasogenic oedema (common with primary and metastatic brain tumours) responds well to steroid use as a temporising intervention. Neurological deficit secondary to surrounding oedema often responds within 72 hours. However, the effect diminishes over time.
- Commonly IV dexamethasone or oral betamethasone is prescribed.
- Steroids have no clear role in treating raised ICP secondary to traumatic brain injury or spontaneous haemorrhage.

### Surgical interventions

#### Mass lesion removal

- In general, mass lesions causing raised ICP should be removed.
- Acute lesions must be operated on immediately (haematomas, abscesses, secondary hydrocephalus).
- Lesions presenting in a subacute or chronic fashion require planning for optimal management.

#### CSF drainage

- External ventricular drain and ventriculo-peritoneal shunt are quick and reliable means of reducing ICP – a small volume of fluid release can significantly lower the ICP.
- CSF drainage is of greatest benefit when there is hydrocephalus. Occasionally CSF drainage can be helpful even when the ventricles are small, as in trauma.

#### Decompressive craniectomy

- This is a procedure used occasionally to treat raised ICP refractory to medical treatment, usually in the context of trauma, but also described for cerebral infarction, trauma, subarachnoid and intracerebral haemorrhage.
- A large section of the calvarial bone is removed, often with a dural graft to expand the dura. It increases cranial volume and so reduces ICP.

- ICP is consistently reduced with the procedure. However, whether this benefits clinical outcome remains controversial.

### What follow-up should be instituted?

Patients with raised ICP are likely to have their long-term care guided by a neurologist or a neurosurgeon, depending on the nature of the underlying pathology. As a general physician, one should be vigilant about recognising signs of raised pressure, in particular in patients with implanted devices such as CSF shunts that may be malfunctioning. A close working relationship with the specialist, allowing for concerns to be discussed timeously, is advantageous.

#### References

1. Dunn LT. Raised intracranial pressure. *J Neurol Neurosurg Psychiatry* 2002;73:i23.
2. Pickard JD. Management of raised intracranial pressure. *J Neurol Neurosurg Psychiatry* 1993;56:845. [<http://dx.doi.org/10.1136/jnnp.56.8.845>]
3. Rangel CL. Management of intracranial hypertension. *Neurol Clin* 2008;26:521. [<http://dx.doi.org/10.1016/j.ncl.2008.02.003>]
4. Sankyan N, Vykunta Raju K, Sharma S, Gulati S. Management of raised intracranial pressure. *Indian J Paediatr* 2010;77:1409-1416. [<http://dx.doi.org/10.1007/s12098-010-0190-2>]
5. Lindsay K. Bone I: Neurology and Neurosurgery Illustrated. UK: Churchill Livingstone, 2001. [<http://dx.doi.org/10.1136/jnnp.74.1.7>]
6. Jacks AS. Spontaneous retinal venous pulsation: Aetiology and significance. *J Neurol Neurosurg Psychiatry* 2003;74:7. [<http://dx.doi.org/10.1136/jnnp.74.1.7>]
7. Holdgate A. Perils and pitfalls of lumbar puncture in the emergency department. *Emergency Medicine (Fremantle, WA)* 2001;13:351. [<http://dx.doi.org/10.1046/j.1035-6851.2001.00239.x>]
8. Linden CH. Cranial computed tomography before lumbar puncture. *Arch Intern Med* 2000;160:2868. [<http://dx.doi.org/10.1001/archinte.160.18.2868>]
9. Oliver WJ. Fatal lumbar puncture: Fact versus fiction — an approach to a clinical dilemma. *Pediatrics* 2003;112:e174. [<http://dx.doi.org/10.1542/peds.112.3.e174>]
10. Citerio G. Intracranial pressure. *Intensive Care Med* 2004;30:1882. [<http://dx.doi.org/10.1007/s00134-004-2377-3>]

## SUMMARY

- Raised ICP is a common management problem in neurosurgical and neurological services.
- Its symptoms, signs and management should be front-of-mind for these treating physicians.
- The clinical manifestations of raised ICP can range from subtle to profound, so the challenge remains for the generalist to consider the diagnosis, test for proof and refer appropriately.
- Given that raised ICP is a serious and potentially life-threatening emergency, fast and reliable referral and transfer mechanisms should be established to ensure patients with this condition are effectively treated.