

The paediatric ophthalmic examination

Examination of a child's eye can be challenging and traumatic but could save the child's sight or even his life.

A du Bruyn,¹ MB ChB, Dip (Ophth), FC (Ophth); D Parbhoo,² MB ChB, FC (Ophth)

¹Consultant Ophthalmologist, St Aidan's Hospital, University of KwaZulu-Natal, Durban, South Africa

²Consultant Ophthalmologist, Parklands Hospital and Inkosi Albert Luthuli Central Hospital, University of KwaZulu-Natal, Durban, South Africa

Correspondence to: A du Bruyn (aritha2@gmail.com)

Twenty-five thousand children in South Africa are blind, mainly because of congenital cataracts, congenital glaucoma, malignant tumours (retinoblastoma), retinopathy of prematurity, inflammation and injuries. Strabismus, amblyopia and refractive errors cause many more children to have reduced vision. Unfortunately, half of these children who go blind will die within 2 years, mainly due to accidents.

Fifty per cent of childhood blindness can be prevented by early detection and treatment, which can easily be achieved without any special equipment by screening children and identifying the causes of blindness. However, the examination of a child's eye can be challenging and traumatic. This article hopes to provide some basics and helpful tricks to perform an accurate examination of a child's eye. This could be a sight- or a life-saving examination.

All squints should be referred as soon as possible for management.

There are many conditions to be aware of. However, it is important to note prematurity of less than 32 weeks and birth weight of less than 1 500 g. Family history, systemic history, drug exposure and perinatal history are vital and so is the schooling history and difficulties at school.

Observation could allow you to pick up on the conditions listed below:

- lack of fixation
- nystagmus
- strabismus
- any swelling or lumps on the lids or around the eyes

- proptosis
- ptosis
- epiphora
- buphthalmos or microphthalmos
- red eyes
- cloudy cornea
- pupil abnormalities
- leucocoria.

Visual assessment

Visual milestones

A child's vision is developing and to establish visual acuity in a child is challenging for most. However, the principles to follow are the visual milestones.

- Birth to 1 month: a baby would briefly fixate on bright light and faces.
- 1 - 3 months: babies start watching parents' faces when being talked to and start to follow objects horizontally.
- 3 months: babies should be able to fixate well on near objects and follow targets. The eyes should also be aligned in all directions of gaze by now.
- 3 - 5 months: a baby recognises a mother's face. They start focusing on objects, develop convergence, stereopsis and colour vision.
- 6 months: they are able to fixate on distance targets.
- 7 - 12 months: most visual skills would be fully developed by now.

Visual acuity testing

Visual acuity charts and basic tests

There are multiple different visual acuity charts available that are often used by the ophthalmologist and optometrist, but with a few basic tests abnormal visual acuity can easily be identified. Assessment of the visual acuity will depend on the age of the child.^[1]

- Under 1 year: Fix and follow. Objection to occlusion of either eye can alert you of possible poor vision in the non-occluded eye.

- 1 - 2 years: A child should be able to pick up hundreds and thousands with ease (different size sweets can be used). Teller's and Cardiff acuity cards can be used.
- 2 - 3 years: At this age they can name pictures and any of the picture charts can be used (Kay pictures, Allen's picture cards, Bailey-Hall). Hundreds and thousands may still be useful.
- 3 - 5 years: Matching optotypes (use the illiterate E chart, Landolt's C test, Sheridan-Gardener's test, Lea charts).
- 6 years and older: Use the normal adult charts for distance (Snellen's letter charts, ETDRS charts) and near (reduced Snellen letter charts and Jaeger's test types).

If none of this is available, watching a child reading a page with each eye and with both eyes can give valuable clues to a possible problem.

If the child cannot read to 6/6, then a pinhole occluder can be used if available. If vision improves with the pinhole, then it is most probably a refractive error and can be corrected with glasses. If the vision does not improve the child should be investigated for a cause.

Watching a child reading a page with each eye and with both eyes can give valuable clues to a possible problem.

Pupil examination in bright light and dim light, looking for anisocoria or a poorly reactive pupil is vital.

Eye movements and strabismus

Eye movements can be assessed with toys and objects that will get a child's attention – left gaze, right gaze, up and down and also right up and down and left up and down. By looking at the eye movements nystagmus, limited movements or overaction of movements may be revealed.

Nystagmus can be sensory (caused by defective vision) or motor imbalance (as a result of defective efferent mechanisms). Children with bilateral central vision loss (as caused by cataracts) will develop sensory nystagmus which is horizontal and pendular. Motor nystagmus have many different forms and is caused by cortical and brainstem problems.^[2]

Strabismus is a misalignment of the eyes due to a muscle imbalance and can be present constantly or may be intermittent. It may cause amblyopia, lack of stereopsis and cosmetic problems that may lead to a poor self-image in children. It could also be the initial manifestation of a life-threatening condition such as a retinoblastoma and must never just be observed. All squints should be referred as soon as possible for management.

The squint examination involves observation and a light torch test looking at the light reflexes of both corneas (Hirschberg test) which can give you clues to a deviated eye.

Hirschberg test

Use a penlight or ophthalmoscope to shine a light into both eyes. If normal, the points of light will fall in the same place in both eyes. If abnormal, the reflection of the light will appear in different places in the two eyes (Figs 1 and 2).

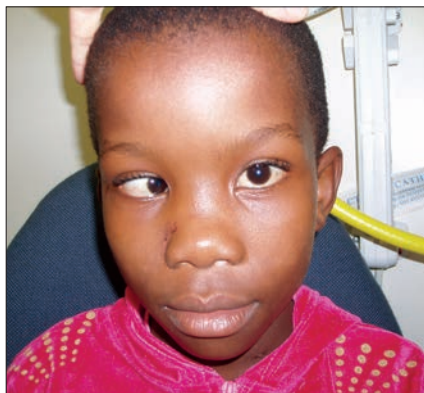

Fig. 1. Hirschberg test showing an esotropia in the right eye.

Cover test

The other more accurate way of assessing for a squint or a deviation of an eye is to perform a cover test, which is described as follows (Fig. 3):^[2]

- Ask the child to focus on an object straight ahead (it must be something that will hold his attention) with both eyes and cover 1 eye with your hand or an occluder.
- Watch the uncovered eye for any movement as it takes up fixation: inward

movement indicates exotropia and outward movement esotropia.

- Remove the cover so both eyes fixate, but you continue looking at the uncovered eye; if it moves back out, you can confirm exotropia (if it moves back in, you can confirm esotropia).
- If there is NO movement of the uncovered eye when you remove the cover and the uncovered eye remains fixated then an alternating exotropia or esotropia is present (the child is able to fixate with both eyes).

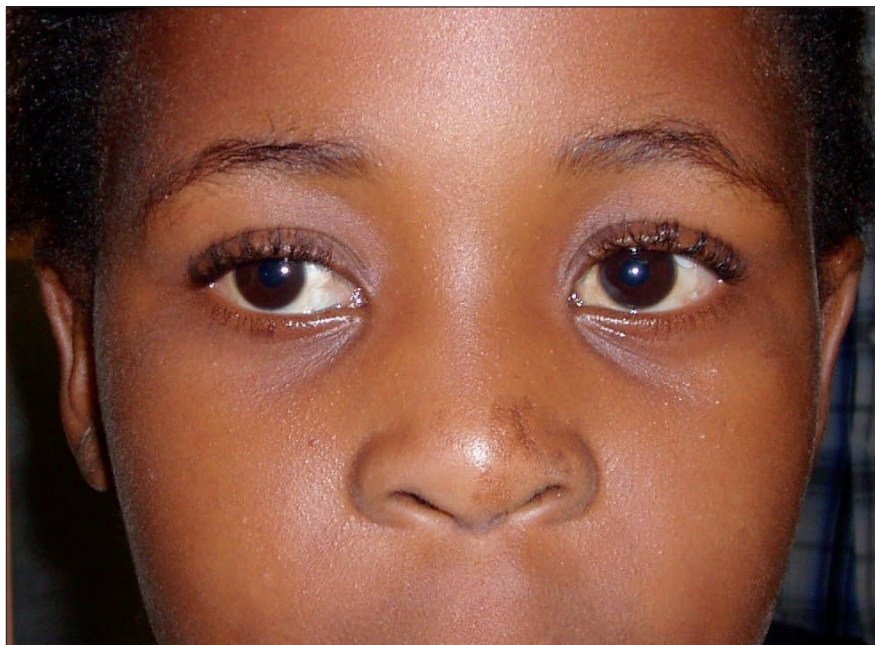


Fig. 2. Hirschberg test showing an exotropia in the right eye.

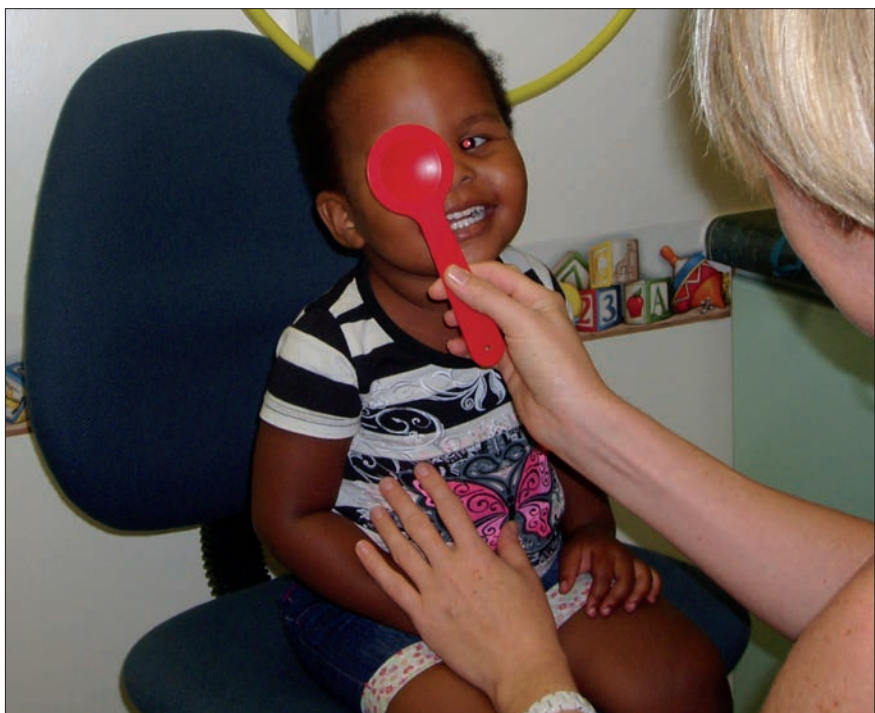

Fig. 3. Occlusion of the eye when performing the cover test.

Lid swelling and proptosis

Lid swelling is often caused by infective or inflammatory conditions or following trauma, but be careful not to miss orbital cellulitis or tumours (embryonal sarcoma, advanced retinoblastoma or metastases from other tumours). Look at the colour, size, consistency and tenderness of the lesion and watch out for any associated signs such as proptosis (Figs 4 and 5), decreased eye movements, decreased visual acuity and any involvement of the globe. Proptosis could suggest a tumour or a life-threatening orbital cellulitis and always needs urgent referral.

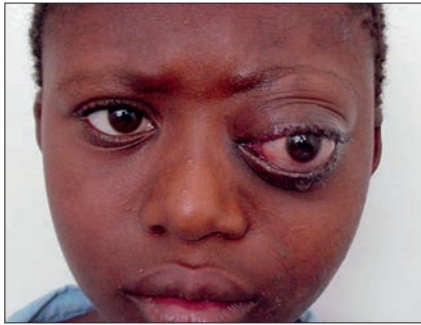

Fig. 4. Proptosis of the left eye due to traumatic retrobulbar haemorrhage.

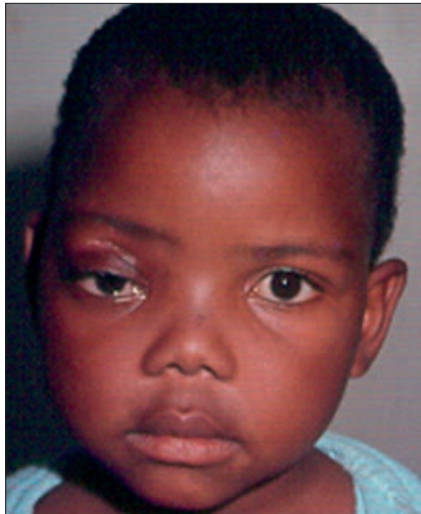

Fig. 5. Right proptosis and ptosis due to metastases from a neuroblastoma.

Ptosis

Ptosis can be congenital or acquired and unilateral or bilateral. It is important to examine the eye movements when a child presents with ptosis to exclude cranial nerve palsies. Specific signs in congenital ptosis are an absent lid crease, poor levator function, lid lag on downgaze and often associated superior rectus weakness.^[3] If the visual axis is obscured the visual development may be

retarded in the long term and surgery is indicated as soon as possible.

Epiphora

Epiphora is a sign of lacrimal drainage obstruction or congenital glaucoma (which is much more serious and can lead to blindness if not treated urgently). Additional signs such as buphthalmos and a cloudy cornea are present in congenital glaucoma.

Microphthalmos

Microphthalmos (small and abnormal eye) and microcornea (corneal diameter less than 10 mm) are often associated with other anterior segment abnormalities like glaucoma or cataracts.

Red eyes

There are multiple causes for red eyes in children and these can be acute or chronic. Watch out for associated signs like lid swelling, proptosis, conjunctival papillae, corneal ulcers and corneal oedema to assist in the diagnosis.

Cloudy cornea

The most important cause of a cloudy cornea in small children is congenital glaucoma and this always has to be excluded. Other causes include birth trauma, prenatal infections, congenital corneal dystrophies, sclerocornea, metabolic storage diseases, interstitial keratitis, infective keratitis, Peter's anomaly and corneal scarring.^[3]

Leucocoria

Always assess for leucocoria. Leucocoria can be identified with the direct ophthalmoscope and in advanced cases may be visible with the naked eye. Testing for a red reflex with the direct ophthalmoscope entails looking through the ophthalmoscope at a distance from the child and observing the red light reflex emitted from the pupil (Figs 6 - 9).

The most important causes for leucocoria are retinoblastoma and cataracts, but can also be caused by persistent fetal vasculature, Coat's disease, toxocara, retinopathy of prematurity, vascular diseases and developmental anomalies.^[3] All children with leucocoria need to be referred for investigation to an ophthalmologist.

Most children with eye problems will initially present to their family practitioner

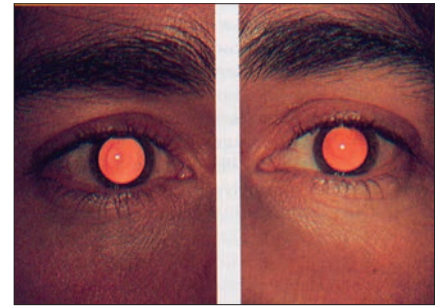


Fig. 6. Normal red reflex.

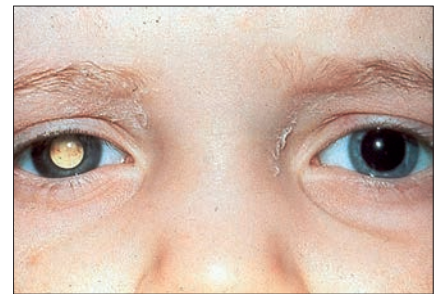

Fig. 7. Abnormal red reflex in the right eye.

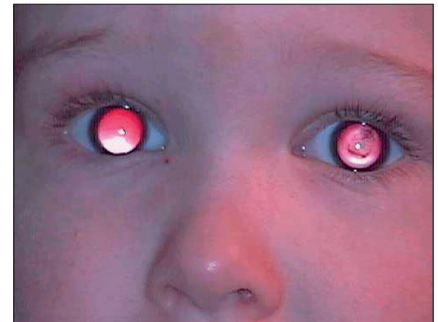

Fig. 8. Abnormal red reflex due to a congenital cataract in the left eye.

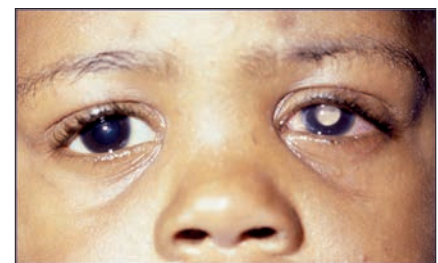

Fig. 9. Leucocoria due to a retinoblastoma in the left eye.

or primary healthcare clinic. In screening these children, identifying the warning signs and rapidly referring them when in doubt, the morbidity associated with blindness and mortality due to malignancies and injuries can be improved dramatically.

References

1. Patwardhan S, Sethi HS. Visual acuity assessment in children. In Lee SH, Prost EO, Crouch ER, Trivedi RH, eds. Instant Clinical Diagnosis in

Paediatric examination

Ophthalmology: Pediatric Ophthalmology, 1st ed. New Delhi: Jaypee Brothers Medical Publishers, 2009: 4-14.

2. Kanski JJ. Clinical Ophthalmology, 6th ed. Oxford: Butterworth Heinemann Elsevier, 2007: 757-758, 830-833.

3. Wong TY. The Ophthalmology Examinations Review, 1st ed. Singapore: World Scientific Publishing Co. 2001: 57-58, 400-401.

IN A NUTSHELL

General principles to remember when examining a child:

- A penlight torch or direct ophthalmoscope is necessary. The direct ophthalmoscope can be used to look at the red reflex as well as for examining the anterior segment of the eye.
- The child should ideally be alert, not hungry and relaxed, although a feeding child will allow access and so will a sleepy child.
- A child may often need to be examined on a parent's shoulder, which provides the comfort and allows you access.
- In a child who has the eyes shut, topical anaesthesia and sedation may help, but a small child may need the help of eyelid retractors. If not available, the blunt end of paper clips could be quite useful, but must be used only as a last resort.
- Avoid an intimidating light at the onset of the examination as this can easily scare the child, which could mean the end of a valuable examination.
- There is no set protocol in the routine of examining a child and the examiner must be adaptive and innovative in grasping the child's attention.
- Start by observing the child and his interaction with parents while you get a brief history. During this period a head tilt or a constant head turn can easily make one aware of an abnormality of the eye movements. A child who closes one eye could be experiencing double vision or could have some form of irritation. Assessing the child's light sensitivity may give you clues to a possible allergy or inflammation.
- Establish touch in a non-threatening way, like a handshake.
- Always sit at the same level or lower than the child.
- Do not be afraid of having fun when examining a child – games and parents' involvement often helps.
- Play games, use phones, stickers and pictures. Keys, toys and sweets can be very helpful to get the attention of the child.
- Smart phones and the many applications available are invaluable in the assessment of a child.
- Photographs are valuable – current or previous. They may allow additional information to the examination and can be forwarded for comment. Red reflexes from cameras allow for valuable deductions about media opacities and interocular differences in vision.
- Sedatives such as Vallergran Forte or an examination under general anaesthesia can be used to obtain a reasonable examination if all other attempts to examine the child fail.