

# Screening for diabetic retinopathy

*All patients with diabetes are at risk of developing diabetic retinopathy.*

**J Rice, FCOphth (SA)**

Ophthalmologist, Division of Ophthalmology, Faculty of Health Sciences, University of Cape Town, South Africa

Correspondence to: J Rice ([james.rice@uct.ac.za](mailto:james.rice@uct.ac.za))

Good glucose control<sup>[1,2]</sup> and the treatment of hypertension<sup>[3]</sup> and hyperlipidaemia remain the key strategies in preventing diabetic retinopathy and its progression. Unfortunately, some degree of retinopathy will eventually develop in almost all type 1 diabetics and over 60% of type 2 diabetics over a 20-year period.<sup>[4]</sup>

Diabetic retinopathy is usually asymptomatic in its early stages. Patients presenting with symptoms often have more advanced disease and are more difficult to manage. They are at higher risk of permanent visual loss. Screening is a cost-effective tool in the fight against diabetic blindness. It involves assessment of visual acuity (including the use of a pinhole to overcome refractive error) and a retinal examination (fundoscopy) through a dilated pupil.

With the rising prevalence of diabetes there is an increasing need for effective retinal screening. Fundus photography has established itself in many countries as the preferred tool for screening for diabetic

retinopathy. Unfortunately fundus cameras are expensive and not yet widely available. While such screening programmes are being developed in the private and public sectors in South Africa, screening with a direct ophthalmoscope still has an important place in the detection of diabetic retinopathy. This article aims to review important clinical features of diabetic retinopathy and provide some practical tools for improved screening with the direct ophthalmoscope.

## When to start screening

- Screening in children and adolescents: annual screening to start 3 - 5 years after diagnosis, and once the patient is 10 years old.<sup>[5]</sup>
- Type 1 diabetics generally do not develop retinopathy within 5 years of the diagnosis.
- Type 2 diabetics may have retinopathy before diabetes is diagnosed. They should be screened at the time of diagnosis.

## How often to screen

- Annual screening is recommended.
- Pregnant diabetics should preferably be screened before pregnancy, early in the first trimester, in each trimester as well as 6 weeks postpartum.<sup>[6]</sup>

## Screening steps

### Step 1: Visual acuity

Visual acuity should be performed with the patient's current spectacles. A pinhole test is used if vision is below normal (6/6). If the vision improves with the pinhole this suggests a residual refractive error. The importance

#### Advice to patients at the time of dilating:

- Complications are extremely unlikely.
- Symptoms of a possible complication: painful, red eye with worsening rather than improving vision.
- Supply a contact number and course of action in the event of a suspected complication.
- Patients should not drive or engage in hazardous activities until vision clears as the pupils return to normal.

of the visual acuity test is that maculopathy can be difficult to diagnose in some patients. Unexplained visual acuity of 6/12 or worse may indicate maculopathy even if not obvious on examination and should be referred.

### Step 2: Dilate the pupils

#### *Is it always safe to dilate the pupils?*

Short-acting dilating drops are extremely unlikely to cause ocular complications.<sup>[7]</sup> We would recommend Mydracyl® (tropicamide) which lasts up to 6 hours. One drop is instilled 3 or 4 times in each eye at 5-minute intervals. The risk of precipitating acute glaucoma is extremely low, even in patients in whom the anterior chamber may look shallow. Patients with chronic glaucoma are also unlikely to experience adverse events from dilation. We consider it better to advise the patient about seeking care in the unlikely event of a complication rather than omitting to screen. An informed patient in this setting is better off than a predisposed patient who spontaneously develops acute glaucoma one evening as the pupil dilates physiologically.

### Step 3: Examine the 'red reflex'

This is done by examining the red reflection of light emerging from the eye with the ophthalmoscope held about 50 cm from the patient. Both eyes should be examined and compared.

Interpretation of abnormal red reflex:

- Discrete small black areas: media opacities – most likely early cataract, sometimes corneal in origin.
- Diffusely dull or no reflex: severe media opacity or disrupted anatomy – possible vitreous haemorrhage or retinal detachment. These will be accompanied by severe visual loss. Visualisation of the fundus may not be possible.

### Step 4: Fundus examination

Pearls for the use of the direct ophthalmoscope:

- Examine the patient's right eye with your right eye, and left eye with your left eye. The index finger should be on the focus wheel at all times. If you are examining

the patient with your glasses on (distance correction) then start on zero with the ophthalmoscope. If you remove your glasses, start with your refractive error (for example -2.00 is usually a red 2 on the dial). Actively seek a good focus on the patient's retina by rotating the focus wheel during examination.

- Make sure that you are holding the ophthalmoscope close enough to your own eye and close enough to the patient's eye. Think of trying to look through a

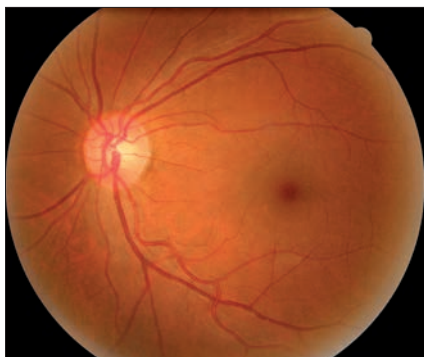


Fig. 1. Normal fundus.

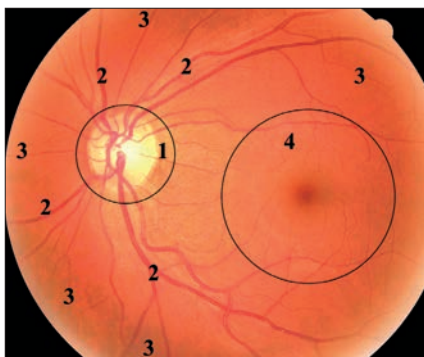


Fig. 2. Systematic examination.

keyhole into a room. You must get close enough. Your free hand can be placed on the patient's forehead to help you judge your distance from the eye and your thumb can gently lift the eyelid.

- If the pupil is widely dilated then use the largest light. If the pupil fails to dilate well then the largest light creates more scatter and a smaller one may improve visualisation. Dimming the ophthalmoscope light slightly may make

### How big is a 'blot' haemorrhage?

It is useful to compare the size of the haemorrhage with the diameter of the large veins that emerge from the optic disc. If a haemorrhage is at least as large as the vein diameter at the disc it is a 'blot' rather than a smaller 'dot' haemorrhage. 'Dot' haemorrhages and microaneurysms may be indistinguishable.

### Tips for examining the macula (Fig. 3):

- Dim the ophthalmoscope light slightly
- Start at the optic disc move temporally into the macula
- To assess the fovea, ask the patient to look directly at the ophthalmoscope light
- To identify small haemorrhages it can be helpful to use the 'red free' filter on the ophthalmoscope. This gives the light a green appearance and any haemorrhage will appear black. It will not improve visualising exudates which are best seen with the white light.

the patient more comfortable and co-operative.

- Ask the patient to look directly at the light to bring the macula (fovea) into view. Use the 'red-free' (green) filter on the ophthalmoscope to help identify small haemorrhages, particularly at the fovea.

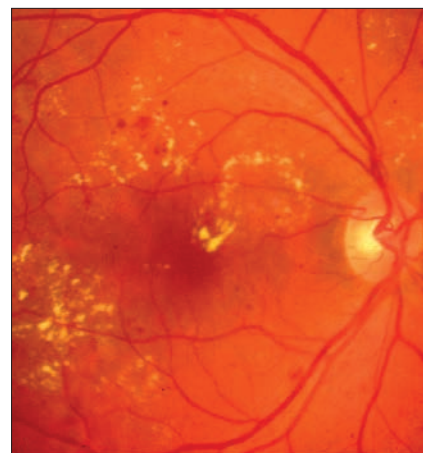


Fig. 3a. Maculopathy.

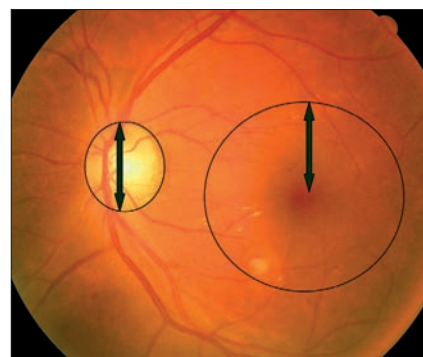
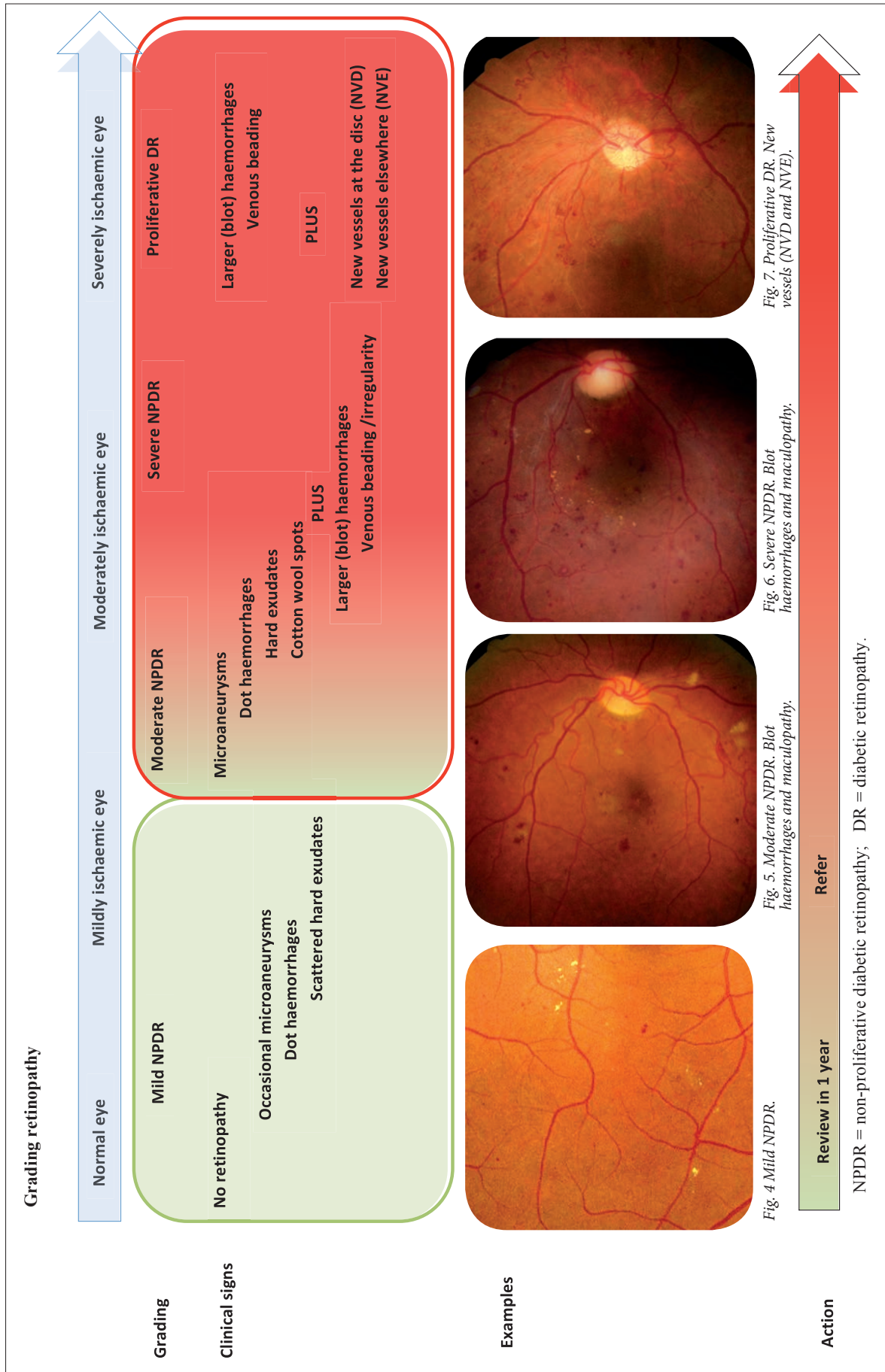


Fig. 3b. Maculopathy within 1 disc diameter of the fovea.

Table 1. Systematic examination and possible findings

Structure examined	Possible features of diabetic retinopathy
Optic disc	New vessels (new vessels at the disc – NVD) (Fig. 7) All new vessels (NVD and new vessels elsewhere – NVE) have an appearance very different from the typical branching, tapering vessels of the normal retina. They are 'out of place', often forming looped random networks
Major vessels in 4 quadrants	Venous tortuosity/irregularity New vessels (NVE)
Peripheral areas between vessels	Microaneurysms Haemorrhages: 'dot' and 'blot' (Fig. 6) Larger 'blot' haemorrhages are a feature of more severe retinopathy, particularly if they occur in all four quadrants of the retina Exudates (yellow, discrete deposits or large clumps) Cotton wool spots (pale with blurred edges – Fig. 5) New vessels (NVE)
Macula	Exudates Haemorrhages Cotton wool spots: Any pathology in the macula is significant and should be referred. Pathology within 1 disc diameter of the centre of the fovea is particularly significant (Fig. 3b)





- Be proactive about the retinal examination. Ask the patient to look in different directions. When the patient looks up, drop your head and look upwards to view the superior peripheral retina etc.

Fig. 1 shows a normal fundus. Assessment of the fundus should be systematic (Fig. 2). One should grade the level of retinopathy and look for maculopathy separately.

The optic disc is a good starting point and serves as a reference location. Look particularly for the features listed in Table 1 at each location.

The flow diagram will help to identify the degree of retinopathy present and indicates when referral is necessary.

## How urgently should patients be referred to an ophthalmologist?

Proliferative diabetic retinopathy should be seen within 1 - 2 weeks. Moderate to severe non-proliferative retinopathy or maculopathy should be seen within 1 - 2 months.

### Haemorrhages in front of the retina:

- Haemorrhages lying on the surface of the retina obscure the retinal blood vessels.
- Haemorrhage into the vitreous obscures the retina completely.

These haemorrhages arise from new vessels and should be graded as proliferative diabetic retinopathy (Fig. 8).

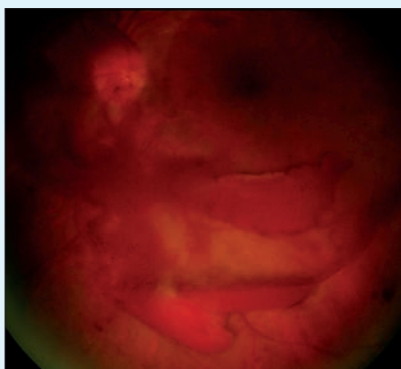


Fig. 8. Haemorrhages in proliferative diabetic retinopathy.

## Treatment by the ophthalmologist

Laser treatment has been the cornerstone of treatment for diabetic retinopathy. This remains the case for proliferative retinopathy. Anti-vascular endothelial growth factor (anti-VEGF) agents and some steroid preparations are new and effective treatments for some cases of macular oedema.

### White scar tissue

New vessels grow on a scaffold of tissue which eventually thickens to form tight scars. These contract and cause a tractional retinal detachment. These patients have proliferative diabetic retinopathy (Fig. 9).

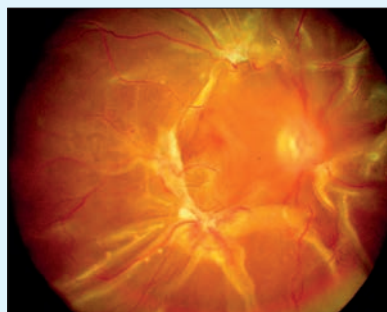


Fig. 9. Scar tissue in proliferative diabetic retinopathy.

### Signs of previous treatment

Some patients have had laser treatment of their retinopathy (Fig. 10). Predominantly black scarring occurs. If the patient has been referred to you by an ophthalmologist as stable following treatment, then annual fundoscopy is indicated. If there is uncertainty about the stability of the retinopathy the patient should be referred.

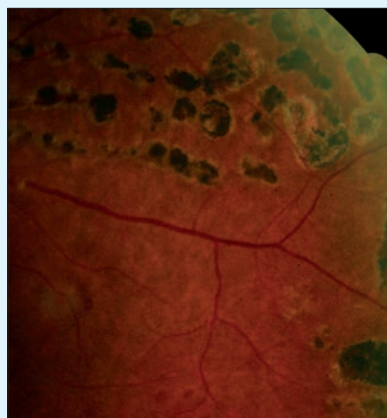


Fig. 10. Signs of previous treatment.

## References

1. The Diabetes Control and Complications Trial. The effect of intensive diabetes treatment on the progression of diabetic retinopathy in insulin-dependent diabetes mellitus. Arch Ophthalmol 1995;113:36-51. [http://dx.doi.org/10.1001/archoph.1995.01100010038019]
2. UK Prospective Diabetes Study (UKPDS) Group. Intensive blood-glucose control with sulphonylureas or insulin compared with conventional treatment and risk of complications in patients with type 2 diabetes (UKPDS 33). Lancet 1998;352:837-853. [http://dx.doi.org/10.1016/S0140-6736(98)07019-6]
3. UK Prospective Diabetes Study Group. Tight blood pressure control and risk of macrovascular and microvascular complications in type 2 diabetes: UKPDS 38. BMJ 1998;317:703-713. [http://dx.doi.org/10.1136/bmj.317.7160.703]
4. Albert DM, Jakobiec FA. Principles and Practice of Ophthalmology. Philadelphia: WB Saunders Co., 2000.
5. Walker ES. Diabetic retinopathy. Diabetes Care 2002; 5:s90-s93.
6. Evers IM. Risk of complications of pregnancy in women with type 1 diabetes: nationwide prospective study in the Netherlands. BMJ 2004;328:915. [http://dx.doi.org/10.1136/bmj.38043.583160.EE]
7. Pandit RJ, Taylor R. Mydriasis and glaucoma: Exposing the myth. A systematic review. Diabetic Medicine 2000;17:693-699. [http://dx.doi.org/10.1046/j.1464-5491.2000.00368.x]

## IN A NUTSHELL

- Appropriate screening and referral for diabetic retinopathy will prevent blindness.
- Screening involves visual acuity, pupil dilation and fundus examination.
- The degree of retinopathy and maculopathy should be assessed independently.
- Patients with mild non-proliferative retinopathy and no maculopathy should be screened annually.
- Refer diabetic patients with any of the following:
  - visual acuity 6/12 or worse of uncertain cause (suspected maculopathy)
  - diabetic maculopathy
  - moderate diabetic retinopathy or worse.