

## Case report

### A child with an unusual cause of difficult asthma

#### Background

Patient UA is a 12-year-old boy who attends a tertiary allergy clinic. He was diagnosed with asthma at 4 years and followed up at medical outpatients.

#### Medication

Budesonide 200 µg bd (bottle spacer) – his asthma was controlled on this medication. He was sensitised to South African grass pollen and house dust mite and had co-morbid persistent allergic rhinoconjunctivitis. He was on intranasal steroids, antihistamines and topical eyedrops.

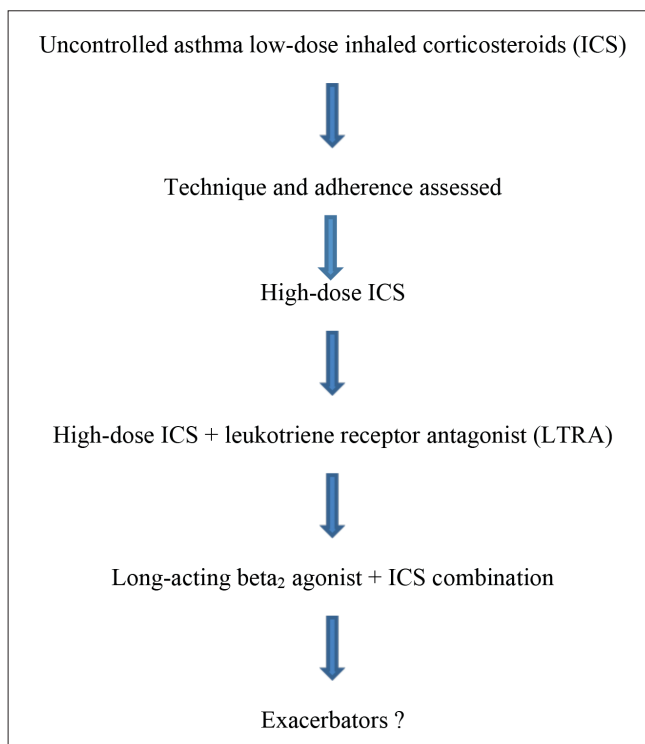


Fig. 1. Disease progression.

#### Disease progression

Disease progression is depicted in Fig. 1.

#### Special investigations

Pulmonary function tests (PFTs) are listed in Table 1. The PFTs showed mixed large and small airways obstruction, with residual reversibility despite therapy with a long-acting beta-agonist.

- FBC
  - white cell count:  $9.56 \times 10^9/l$  (3.90 - 10.20)
  - haemoglobin: 13.8 g/dl (11.8 - 14.6)
  - MCV: 76.1 fl (77.1 - 91.5)
  - platelets:  $390 \times 10^9/l$  (180 - 440)
- Differential
  - eosinophils: 11.0%;  $1.05 \times 10^9/l$  (0.00 - 0.70). Significant peripheral eosinophilia was present.
- Erythrocyte sedimentation rate: 52 mm in 1 hour (normal <10). The raised ESR meant TB, intercurrent infection and that Churg- Strauss syndrome should be excluded.
- Immunoglobulins
  - IgG: 9.92 g/l (6.00 - 20.00)
  - IgA: 1.50 g/l (0.80 - 3.00)
  - IgM: 0.85 g/l (0.40 - 1.80).

The HIV enzyme-linked immunosorbent assay (ELISA) was non-reactive.

The immunoglobulins were normal and so excluded IgA deficiency, which can present with recurrent infections and masquerade as uncontrolled asthma. HIV infection excludes a secondary immunodeficiency.

- Sweat test
  - chloride 25 mmol/l (normal <40, suspicious 40 - 60, cystic fibrosis >60).

The sweat electrolyte test is the gold standard for the diagnosis of cystic fibrosis. In young children it is an important differential for recurrent wheeze.

- ANCA negative: antinuclear cytoplasmic antibody-negative excludes Churg-Strauss syndrome.

Table 1. Pulmonary function tests

	Pred	Pre	%Pred	Post	%Pred	%Diff
FVC	2.41	1.61	67	1.82	75	13
FEV <sub>1</sub>	2.17	1.22	56	1.45	67	19
FEV%FVC	86	75	88	80	93	6
PEF	5.18	3.06	59	3.17	61	3
FEF25	4.07	2.2	54	2.48	61	13
FEF50	2.88	1.17	40	1.6	56	37
FEF75	1.48	0.4	27	0.51	35	29

Pred = predicted; Diff = difference; FVC = forced vital capacity; FEV<sub>1</sub> = forced expiratory volume in 1 second; FEF = forced expiratory flow; PEF = peak expiratory flow.

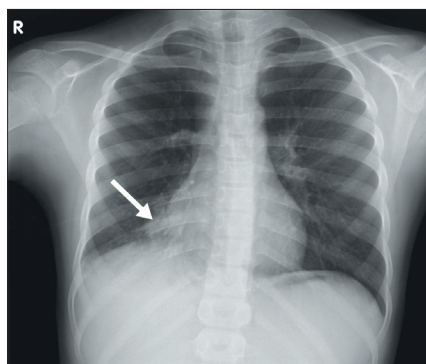


Fig. 2. Chest X-ray showing fine bilateral infiltrates.

- Sputum-negative microscopy, culture and sensitivities for bacteria and tuberculosis.
- Nuclear medicine
  - no reflux
- Total IgE 1 950 kU/l
- IgE *Aspergillus* 10.2 kU/l
- IgG *Aspergillus* 90.4 mg/ml
- Chest X-ray: the chest X-ray (Fig. 2) showed right middle lobe infiltrates.

### Diagnosis

Based on the extensive workup, a diagnosis of allergic bronchopulmonary aspergillosis (ABPA) was made. The patient fulfilled the criteria for ABPA (see below), and was successfully treated with oral corticosteroids. He has not relapsed to date.

### Diagnostic criteria for ABPA<sup>[1]</sup>

- Asthma
- Total serum IgE (>1 000 ng/ml or 417 kU/l)
- Raised *Aspergillus fumigatus* IgE levels or IgG *A. fumigatus*
- Skin prick positive *A. fumigatus*
- Chest X-ray infiltrates (not essential for diagnosis).

### Discussion

With all cases of 'difficult' asthma the diagnosis should be reviewed to ensure that the correct diagnosis has been made and then treatable exacerbators sought.

ABPA is a hypersensitivity disorder to the mould *A. fumigatus* and occurs mainly in patients with asthma or cystic fibrosis.

Sensitisation to mould has been found to be associated with the development, persistence and severity of asthma.<sup>[2]</sup>

*Aspergillus* sensitisation has been found to be as high as 40% in adult asthma clinics, with a prevalence of ABPA at 12.9%.<sup>[3]</sup>

Historically the treatment of ABPA has been oral corticosteroids. However, they are fraught with inherent side-effects which are particularly prominent in children, especially when protracted courses are

required. Azoles for ABPA have shown a synergistic role with prednisone for the treatment of the condition.

### Antifungals

Itraconazole was the first antifungal to be used, but unfortunately a 40% failure rate was reported.<sup>[3]</sup> This was either due to treatment failure, or unacceptable side-effects. More recently, voriconazole and then posaconazole have been shown to be efficacious in patients who had failed itraconazole. Voriconazole and posaconazole, as synergistic therapy with oral corticosteroids, have shown a clinical response in a significant number of patients.<sup>[4]</sup>

**T Kerbelker, MB ChB, FCPaed (SA), DCH (SA), Dip HIV Management (SA), Dip Allerg (SA)**

*Division of Allergy, Red Cross War Memorial Children's Hospital, University of Cape Town*

**D Hawarden, BSc, MB ChB**

*Division of Allergy, Department of Medicine, Groote Schuur Hospital, Cape Town*

Correspondence to: T Kerbelker (tamarakerbelker@yahoo.com)

References available at [www.cmej.org.za](http://www.cmej.org.za)

## SINGLE SUTURE

### World's oldest pill treated sore eyes

In ancient Rome, physicians treated sore eyes with the same active ingredients as today. So suggests an analysis of pills found on a cargo ship wrecked off the Italian coast in around 140 BC.

'To our knowledge, these are the oldest medical tablets ever analysed,' says Erika Ribechini of the University of Pisa in Italy, head of a team analysing the relics. She thinks the disc-shaped tablets, 4 cm across and 1 cm thick, were likely dipped in water and dabbed directly on the eyes (PNAS, <http://dx.doi.org/10.1073/pnas.1216776110>).

The tablets were mainly made of the zinc carbonates hydrozincite and smithsonite, echoing the widespread use of zinc-based minerals in today's eye and skin medications. Ribechini says there is evidence that Pliny the Elder, the Roman physician, prescribed zinc compounds for these uses almost 250 years after the shipwreck in his seminal medical encyclopaedia, *Naturalis Historia*.

The tablets were also rich in plant and animal oils. Pollen grains from an olive tree suggest that olive oil was a key ingredient, just like it is today in many medical and beauty creams, says Ribechini.

New Scientist, 9 January 2013

## References

1. Greenburger PA. Allergic bronchopulmonary aspergillosis. *J Allergy Clin Immunol* 2002;110:685-692.
2. Wark PA, Gibson PG, Wilson AJ. Azoles for allergic bronchopulmonary aspergillosis associated with asthma. *Cochrane Database Syst Rev* 2004;(3):CD001108.
3. Pasqualotto AC, Powell G, Niven R, Denning DW. The effects of antifungal therapy on severe asthma with fungal sensitization and allergic bronchopulmonary aspergillosis. *Respirology* 2009;14:1121-1127.
4. Chishimba L, Niven RM, Cooley J, Denning DW. Voriconazole and posaconazole improve asthma severity in allergic bronchopulmonary aspergillosis and severe asthma with fungal sensitization. *J Asthma* 2012;49:423-433.