

# Spider bite in southern Africa: diagnosis and management

*The diagnosis of spider bite, especially when the patient is unaware of having been bitten, can be difficult.*

## **G J Müller, BSc, MB ChB, Hons BSc (Pharm), MMed (Anaes), PhD (Tox)**

*Dr Müller is part-time consultant in the Division of Pharmacology, Department of Medicine, Faculty of Medicine and Health Sciences, Stellenbosch University. He is the founder of the Tygerberg Poison Information Centre.*

## **C A Wium, MSc Medical Sciences**

*Ms Wium is a principal medical scientist employed as a toxicologist in the Tygerberg Poison Information Centre, Division of Pharmacology, Department of Medicine, Faculty of Medicine and Health Sciences, Stellenbosch University.*

## **C J Marks, BSc Pharmacy, MSc Medical Sciences**

*Ms Marks is the director of the Tygerberg Poison Information Centre, Division of Pharmacology, Department of Medicine, Faculty of Medicine and Health Sciences, Stellenbosch University.*

## **C E du Plessis, BSc Microbiology and Genetics**

*Ms Du Plessis is a medical technologist. She is a staff member of the Tygerberg Poison Information Centre and the Therapeutic Drug Monitoring Laboratory, Division of Pharmacology, Department of Medicine, Faculty of Medicine and Health Sciences, Stellenbosch University.*

## **D J H Veale, PhD Pharmacology**

*Dr Veale is the former director of the Tygerberg Poison Information Centre and currently a consultant clinical pharmacist and lecturer in pharmacology and toxicology.*

*Correspondence to: G Müller (gmul@sun.ac.za)*

The medically important spiders of southern Africa can be divided into neurotoxic and cytotoxic groups. The neurotoxic spiders belong to the genus *Latrodectus* (button or widow spiders) and the cytotoxic spiders are represented chiefly by the genera *Cheiracanthium* (sac spiders) and *Loxosceles* (violin or recluse spiders).

The baboon spiders (family: Theraphosidae) and the wandering or rain spiders (genus *Palystes*) can inflict painful bites which may be susceptible to infection.

## **Neurotoxic spiders and the syndrome of latrodectism**

The term latrodectism is used to describe the systemic symptoms and signs of envenoming in humans by the bite of the *Latrodectus* spider species. The diagnosis is usually clinical but may be supported by identification of the spider if available.

Six species of the genus *Latrodectus* occur in southern Africa. They can be divided into the black widow (button) spider complex, comprising four species, namely *L. indistinctus*, *L. renivulvatus*, *L. cinctus* and *L. karoensis*; and the brown widow (button) spider complex, consisting of *L. geometricus* and *L. rhodensiensis*.

The black button spiders are dark brown to pitch black, with an average body length of 8 - 15 mm. There are no ventral markings of note on the spherical abdomen. Dorsal markings vary from red to yellow orange stripes to a red spot just above the spinnerets. In older specimens the red stripes and spots may have disappeared

completely. The legs are evenly black. The globular or pear-shaped egg sacs, which measure 10 - 15 mm in diameter, are white to greyish yellow with a smooth silky surface. Although *L. indistinctus* and other black widow spider species are occasionally found in suburban gardens and bites have occurred inside homes, they are predominantly *veld* species. The venom of *L. indistinctus* has been studied in detail. It is used in the synthesis of the local spider antivenom (SAIMR Spider Venom Antiserum SAVP).

Figs 1 and 2 show the morphology of *L. indistinctus*. Fig. 3 shows the black widow spider with its egg sacs. Fig. 4 is a sub-adult *L. indistinctus* (black widow). Fig. 5 shows the geographical distribution of the *Latrodectus* species in southern Africa.

**The term latrodectism is used to describe the systemic symptoms and signs of envenoming in humans by the bite of the *Latrodectus* spider species.**

The brown widow spiders are slightly smaller and look less robust than the black widow spiders. The colour varies from creamy yellow or grayish brown to dark brown to black. In paler specimens the dorsal surface of the abdomen displays an intricate geometrical

## Spider bite



Figs 1 and 2. Black widow spider (*L. indistinctus*) with a typical red spot on the dorsal surface just above the spinnerets (silk-producing organ).

pattern, ranging in colour from cream to brown and orange. They are further characterised by a consistent orange to red hourglass marking on the ventral surface of the abdomen. The joints of the



Fig. 3. The egg sacs of the black widow spider (*L. indistinctus*) are white to greyish yellow in colour with a smooth silky surface.



Fig. 4. Sub-adult black widow spider (*L. indistinctus*) with red markings on the dorsal surface of the abdomen.

legs are darker and impart a banded light to dark brown appearance. The egg sacs of *L. geometricus* can easily be distinguished from those of the black widow spiders by numerous spicule-like projections distributed over the surface. The webs of this cosmopolitan species are commonly found around homes throughout southern Africa. They have a predilection for window sills, drain pipes, garden furniture, garden sheds, post boxes, barns, stables and outdoor toilets. *L. rhodensis* cannot be distinguished macroscopically from *L. geometricus*; however, the egg sacs differ from those of *L. geometricus* in that they are about two-and-a-half times larger and have a woolly appearance, without the spicule-like projections.

Figs 6 and 7 show the morphology of the brown widow spider (*L. geometricus*). Fig. 8 shows the egg sacs of the brown widow spider.

The venom of the *Latrodectus* species contains a neurotoxin known as  $\alpha$ -latrotoxin, which binds with high affinity to a specific presynaptic receptor of peripheral nerves, creating ionic pores and setting a process in motion that results in a massive release of neurotransmitters. It displays no selectivity for specific types of



## Spider bite

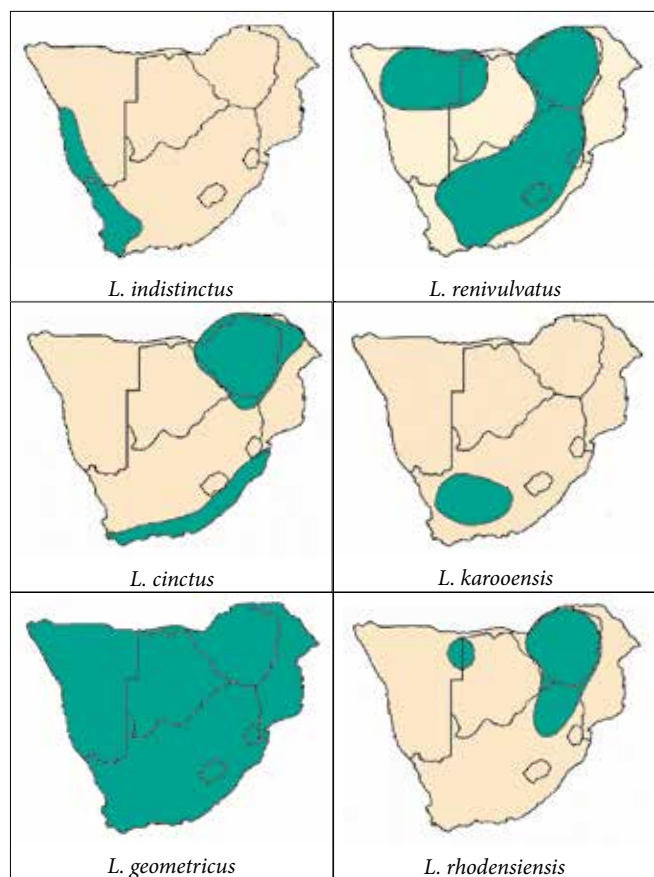


Fig. 5. Geographical distribution of the *Latrodectus* species in southern Africa. (Map: Ansie Dippenaar.)

synapses and has no effect on non-neuronal cell types, whether excitable or not, and is devoid of any detectable enzymatic activity. The massive release of the two main peripheral neurotransmitters, acetylcholine and noradrenaline, accounts for the clinical picture of latrodectism. A bite, especially by the more venomous *L. indistinctus*, induces a hyperactive state, initially characterised by a generalised stimulation of the somatic and autonomic nerve endings, followed by a phase of relative paralysis due to the depletion of neurotransmitters. The central nervous system is not affected owing to the apparent inability of the toxin to cross the blood-brain barrier. See Fig. 4 in the scorpion sting article with regard to the mechanisms of action of neurotoxic venoms on the peripheral nervous system.

LD<sub>50</sub> studies have shown that *L. indistinctus* (black widow) venom is four times more venomous than that of *L. geometricus* (brown widow). This finding has also been confirmed by clinical studies.

### Clinical features of latrodectism

Black widow spider bites usually cause burning pain at the bite site, although some victims are not aware of being bitten. The majority of bites occur on an extremity. The pain typically spreads to the inguinal or axillary lymph nodes within 5 - 15 minutes. The bite site can usually be located, but the local inflammatory reaction is



Fig. 6. Brown widow spider depicting consistent orange to red hourglass marking ventrally.



Fig. 7. Brown widow spider: dorsal surface of the abdomen displays an intricate pattern of well-demarcated geometrical markings. (Photo: John Visser.)

mild and often unimpressive. No bite mark is detectable in 30% of cases, even in the presence of severe systemic symptoms and signs of envenomation. Within an hour the patient develops generalised muscular pain and cramps, especially in the abdomen, chest, back and thighs. The pain in the bigger muscle groups (girdle muscles) rapidly increases in severity and is sometimes described as excruciating. There is a feeling of weakness in the legs and difficulty in walking. A feeling of tightness in the chest, which is interpreted by some victims as difficulty in breathing, is often described. An erection is occasionally experienced, especially in children. The patient appears anxious and sweats profusely, and clothes and bedding are often soaked with sweat. The regional lymph nodes are tender and occasionally palpable. A board-like rigidity of the abdomen is characteristic and the general position of flexion the patient may assume is a sign of increased muscle tone. Coarse involuntary movements and brisk tendon reflexes are often observed. An interesting (although not a regular) feature is a flushed

## Spider bite



Fig. 8. Brown widow spider egg sacs with numerous spicule-like projections.

and oedematous face, especially peri-orbitally, with accompanying conjunctival injection. The blood pressure is usually markedly raised and the pulse rate is rapid, although a patient occasionally may present with marked bradycardia. A slight fever is sometimes present. Laboratory and radiographic investigation are of little value as an aid in the diagnosis. In patients not treated with antivenom the condition may become protracted, without improvement for days to a week or more. This can lead to a general state of exhaustion and dehydration. Patients particularly at risk are small children, the elderly and those with cardiovascular and respiratory disease. Although no deaths as a result of widow spider bites have been documented in recent times, accounts by various authors before the mid-1960s report a mortality rate of 1 - 6%.

Fig. 9 shows a flushed and oedematous face of latrodectism. Figs 10 and 11 also show symptoms and signs of latrodectism. Fig. 12 shows the patient in Fig. 11 post-antivenom administration.

Although the black widow spider is primarily a *veld* species, a surprisingly high number of victims are bitten in the home environment. In spite of this, no black widow spider webs have as yet been found inside or outside the house in localities usually inhabited by the brown widow. It is assumed that the spiders end up in clothing during gardening activities and carried into the house. Black widow spider bites are often associated with farming activities. However, the mechanisation of crop harvesting has led to a decrease in the risk to the farm labourer.

The bite of the brown widow spider usually causes a milder form of envenomation compared with black widow spider bites and is characterised chiefly by local symptoms and signs. Most adult patients complain of a local burning sensation which often spreads to the regional lymph nodes. Paraesthesiae in the surrounding skin and stiffness of the local muscles are often described. In a small percentage of patients, abdominal and general muscular pain and weakness in

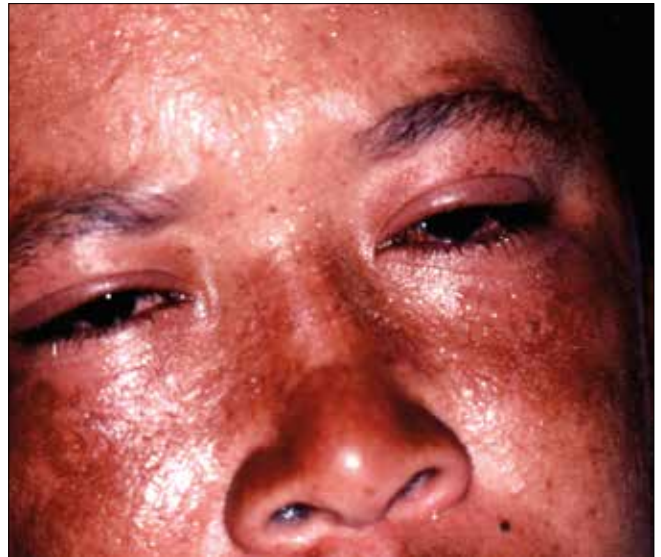

Fig. 9. Latrodectism: flushed and oedematous face, especially periorbitally, with accompanying conjunctival injection.

the legs are experienced. On examination, the bite site can usually be identified. It often manifests as a red macular spot or centrally blanched area surrounded by a 2 - 3 cm erythematous reaction. Occasionally there is a localised increase in sweat secretion in the form of small droplets. A low-grade fever is sometimes noted. The condition is self-limiting and usually clears up within 1 - 3 days, although some patients may experience a feeling of local discomfort for an extended period. Children may present with hyperactivity or restlessness and are more inclined to develop symptoms and signs of systemic envenomation.

### Differential diagnosis

The diagnosis of latrodectism, especially when the patient is unaware of having been bitten, or in cases where the culprit has not been identified, can be difficult. The syndrome of latrodectism is notoriously known to mimic other disease states. Suspected acute medical and surgical conditions which have led to the misdiagnosis of latrodectism include the following:

**Scorpionism.** Although different mechanisms of action are involved, both widow spider and scorpion venom cause an increase in the release of peripheral neurotransmitters, resulting in similarities between latrodectism and scorpionism. Classic symptoms and signs of scorpionism not found in latrodectism include dysphagia, loss of the gag reflex associated with a marked increase of oral secretions, difficulty in breathing, visual disturbances and pronounced general hyperaesthesia. Scorpionism does not give rise to abdominal rigidity and increased sweating is not a prominent feature. Owing to the immediate and often excruciating pain of the sting, the scorpion is usually seen by the victim.

See Table 1 in the scorpion sting article with regard to a comparison of major symptoms and signs of scorpionism, latrodectism and neurotoxic cobra bite.



## Spider bite

**Cytotoxic spider bites.** Bites caused by the cytotoxic spiders, for example *Cheiracanthium* (sac spider) and *Loxosceles* (violin spider) spp., should be considered. They give rise to local tissue destruction and ulcer formation. The extent of the local tissue reaction and the absence of neurotoxic symptoms and signs should assist in the differential diagnosis.

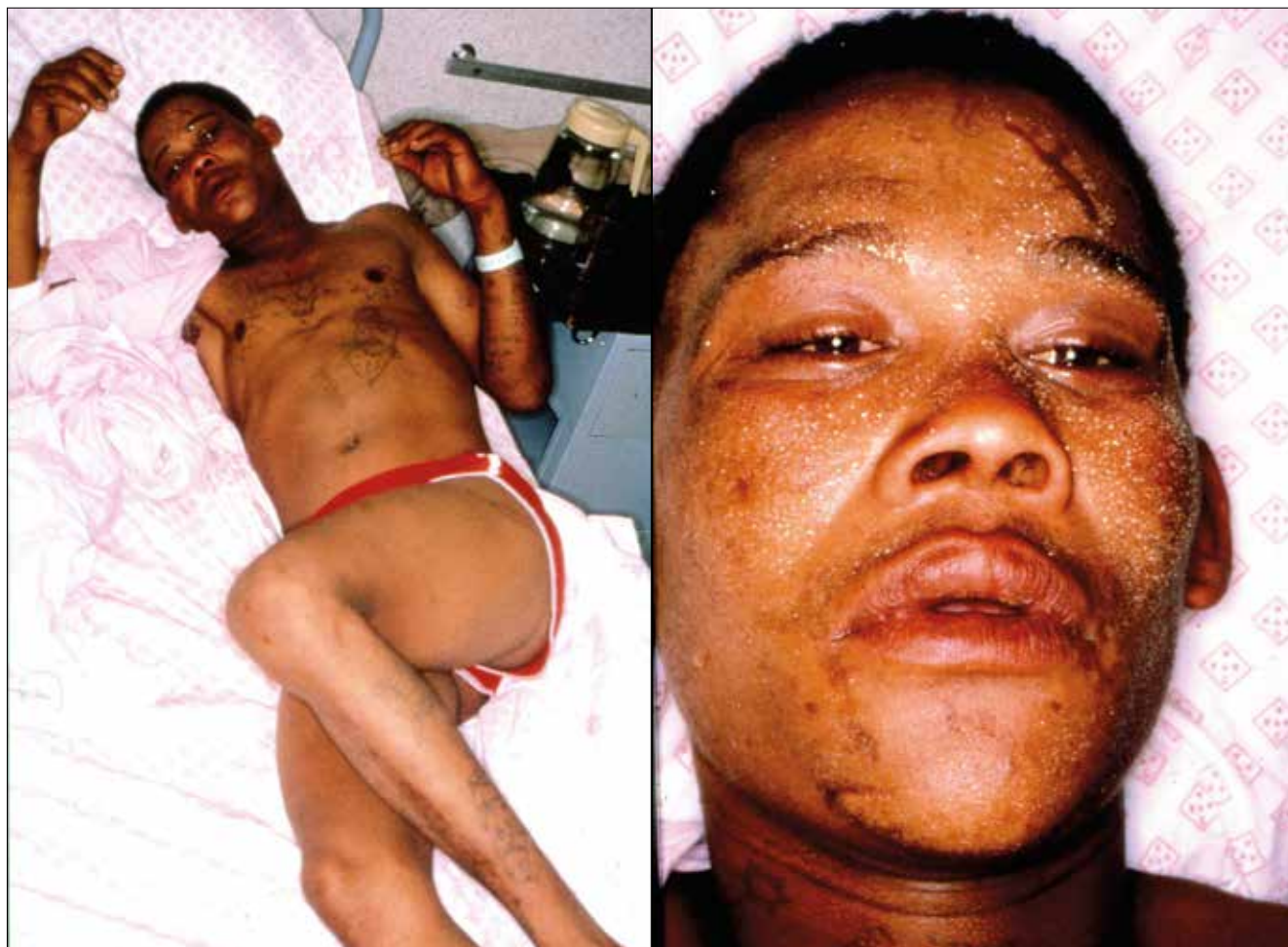**Snake bite.** In a substantial proportion of widow spider bites and scorpion stings, the bite site is either insignificant or cannot be located. The same problem applies to neurotoxic snake bites. However, the earliest systemic symptoms and signs of a neurotoxic snake bite are visual disturbances and ptosis, features which are not associated with widow spider bites. Also see Table 1 in the scorpion sting article. The local tissue damage and inflammatory response of cytotoxic snake bites are usually so pronounced that it does not feature in the differential diagnosis.

**Acute abdomen.** Misdiagnosing latrodectism as an acute abdomen, for example a perforated peptic ulcer or acute appendicitis with peritonitis, has often led to unnecessary laparotomies. Other acute abdominal conditions that have been considered in latrodectism

include renal colic, acute pancreatitis and a leaking abdominal aneurysm. Although the abdomen in latrodectism may be as hard as a board, there is no marked local tenderness and no rebound tenderness, and the bowel sounds are normal.

**Myocardial infarction.** The following is a typical example: A 60-year-old man working in an onion field suddenly became ill with a feeling of anxiety, increased perspiration, with a cold, clammy skin, nausea and vomiting and a feeling of tightness of the chest. He was admitted to hospital with the diagnosis of myocardial infarction. Three days after admission, a diagnosis of latrodectism was considered after all the special investigations performed had been found to be negative. He responded dramatically to the administration of antivenom and recovery was uneventful.

**Alcohol withdrawal.** The following is a typical example: A known alcoholic was admitted to a psychiatric ward with the diagnosis of delirium tremens. After complaints from friends that the history of black widow spider bite had been ignored, a diagnosis of latrodectism was considered. The patient responded dramatically within 1 hour after the administration of antivenom and recovery was uneventful.



Figs 10 and 11. Black widow spider bite, showing increased skeletal muscle tone on the left and copious sweating of the face on the right.

## Spider bite

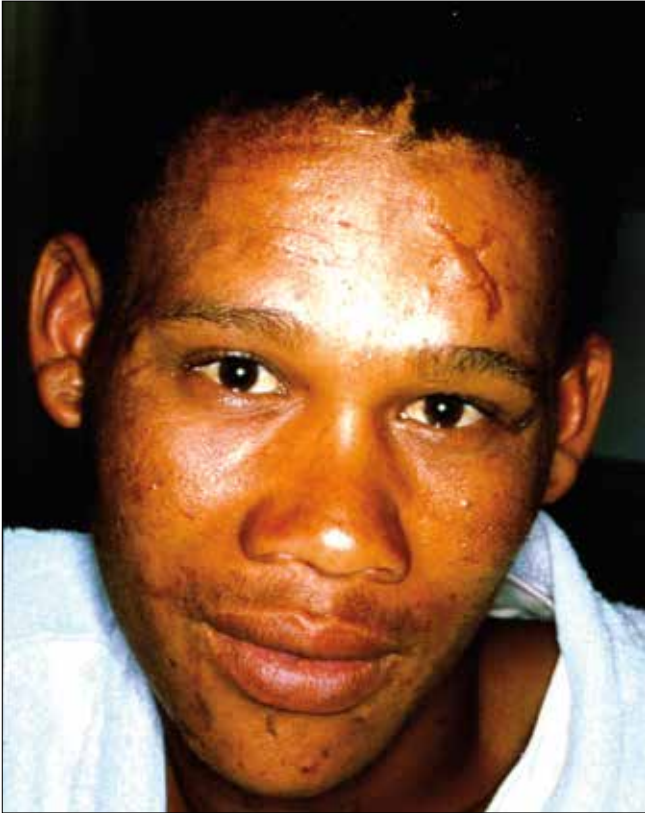

Fig. 12. Two hours after administration of antivenom in patient depicted in Fig. 11.

**Poisoning caused by cholinesterase inhibitors.** The possibility of organophosphate or carbamate poisoning is occasionally considered in the differential diagnosis in patients with suspected latrodectism. Both cholinesterase inhibitors and  $\alpha$ -latrotoxin give rise to an increase in acetylcholine concentration in the synaptic cleft and it is not surprising, therefore, that there are similarities between the clinical profiles. Both can cause a state of anxiety and restlessness, a feeling of tightness in the chest, abdominal tightness and cramps, nausea and vomiting, increased sweating, muscle twitching, raised blood pressure and bradycardia or tachycardia. Determination of the plasma cholinesterase levels may assist in resolving the diagnosis. Other conditions which have been considered in the differential diagnosis of latrodectism include tetanus, meningitis (a stiff neck), pneumonia and poliomyelitis.

### Management

Intravenous fluids should be administered to keep the patient well hydrated and urine flowing. Opioids and other central nervous system depressants, for example the benzodiazepines, are not only relatively ineffective but potentially dangerous because they can precipitate respiratory depression in an already compromised patient. The only effective agent (apart for the antivenom) for the relief of muscular pain and cramps is intravenous calcium gluconate 10% (10 ml over 5 - 10 minutes), but its effect lasts for only 20 - 30 minutes and there is a limit to the amount

which can be given. A spider bite, like any other wound, may become infected and cases of tetanus have been reported. The administration of tetanus toxoid is therefore recommended. The use of antihistamines, for example promethazine, is not recommended except when given prophylactically to reduce the effects of a possible allergic reaction to the antivenom.

The administration of specific black widow antivenom (SAIMR Spider Venom Antiserum SAVP) is the only effective treatment for severe latrodectism. The state of systemic intoxication can be drawn out for a week or even longer, causing the patient to become exhausted, dehydrated and prone to the development of complications. Therefore, it is recommended that antivenom be administered to patients presenting with systemic symptoms and signs. The spider antivenom is a refined equine anti-spider serum globulin, supplied in 5 ml ampoules. The standard dose is 5 - 10 ml intravenously for adults and children. Rarely an additional dose of 5 ml may be administered after 4 - 6 hours, should the response to the first dose be inadequate. The antivenom is very effective and the response dramatic within 30 - 60 minutes. Allergic/anaphylactoid reactions to the antivenom may develop, as is the case with all serum preparations of animal origin. The prophylactic administration of adrenaline intramuscularly to prevent serious allergic reactions is controversial because it may theoretically increase the effects of autonomic nervous system stimulation by *Latrodectus* venom. The victim should be kept under observation for at least 6 - 12 hours after treatment with antivenom.

See general instructions in the snake bite article with regard to antivenom therapy, management of allergic reactions as well as the prophylactic use of adrenaline in the prevention of allergic reactions.

### Cytotoxic spiders and the syndrome of necrotic arachnidism

Spiders of southern Africa suspected of causing most cases of necrotic arachnidism include the sac spiders (genus *Cheiracanthium*) and the violin spiders (genus *Loxosceles*). Although the crab spiders (genus *Sicarius*) are also considered cytotoxic, clinical evidence is inconclusive.

### The syndrome of latrodectism is notoriously known to mimic other disease states.

The sac spiders are widely distributed in southern Africa and comprise nine species, of which *C. furculatum*, *C. vansoni* and *C. africanum* are more commonly found. They are small to medium (4 - 16 mm), straw coloured, sometimes with a greenish tint, with a large, shiny, black eye region and mouth parts. The sac spiders are nocturnal in habit and fast moving. They frequently invade the



## Spider bite



Figs 13 and 14. Sac spider showing general colour features and black mouth parts. (Photo: Ansie Dippenaar.)

house and are often found in the folds of curtains, clothing and cupboards where they make sac-like retreats of thin silk in which they hide during the day. They are aggressive and will bite at the slightest provocation. Most victims are bitten while asleep.

Figs 13 and 14 show the morphological characteristics of the sac spider.

The violin spiders, although relatively rare, are widely distributed in southern Africa and comprise six species, namely *L. bergeri*, *L. parrami*, *L. simillima*, *L. pilosa*, *L. speluncarum* and *L. spinulosa*. They are medium to large spiders (body length 8 - 15 mm with a leg span up to 40 mm), usually brownish to tan in colour, with a characteristic dark, violin-shaped marking on the dorsal surface of the cephalothorax (larger part of the fiddle towards the front end). The abdomen is ovoid, and the legs are long and slender. Violin spiders are never web bound. They roam freely at night in search of prey. Several species are only found in caves. Only a few are found in human habitats in small areas of South Africa. They live in cracks and crevices of walls, behind picture frames and in dark corners of cupboards and drawers.

Figs 15 and 16 show the morphological characteristics of the violin spider.



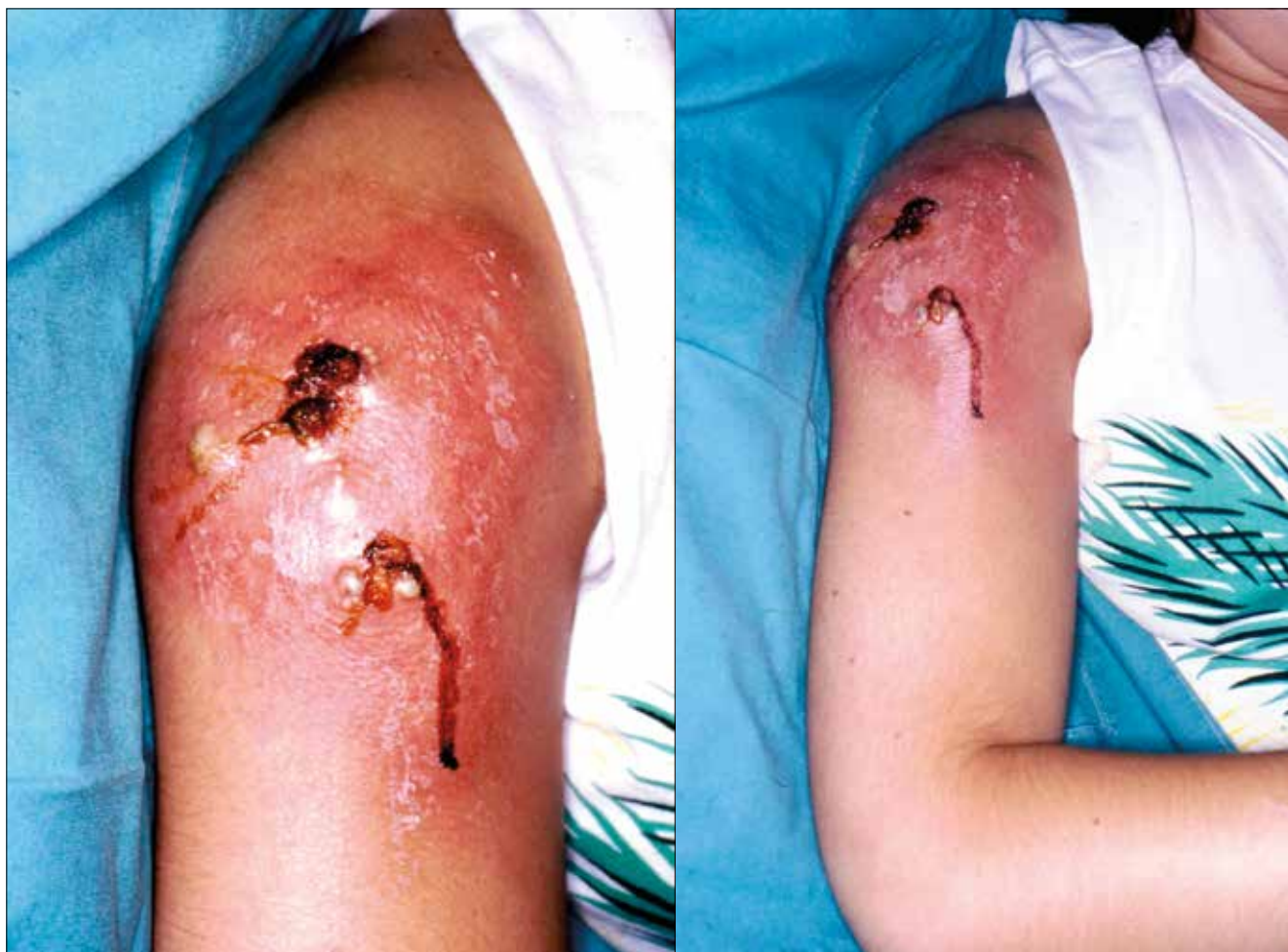Fig. 15. Violin spider (*Loxosceles simillima*) with characteristic mark of a violin on the dorsal surface of the carapace (larger part of the violin towards the front end). (Photo: Ansie Dippenaar.)



Fig. 16. Violin spider with long, slender legs. (Photo: Gerald Newlands.)

Most of the venom components of sac and violin spiders are enzymes with cytotoxic effects. An important component includes hyaluronidase, a spreading factor that increases the size of the tissue lesion.

## Spider bite



Figs 17 and 18. Sac spider bite on right shoulder with subcutaneous suppuration. Debridement and skin graft eventually needed.

### Clinical features of necrotic arachnidism

Necrotic arachnidism is the clinical syndrome caused by the bite of cytotoxic spiders. In >90% of cases, diagnosis is based solely on clinical findings. The diagnosis of necrotic arachnidism is usually presumptive and made through epidemiological information and evolution of the clinical picture, as few patients bring the spider with them for identification.

The symptoms and signs of sac and violin spider bites are basically similar and the effects of the one can usually not be distinguished from the other.

The bite may be painless, frequently occurring at night when the patient moves in bed, disturbing the spider. The patient is often not aware of being bitten, but fang marks and bleeding may be present. Redness or a red mark appears to be a consistent finding in most patients. Local swelling is not significant soon after the bite. Itchiness may be prominent. Within 12 - 24 hours the bite site becomes erythematous, oedematous, painful, and may develop mottled haemorrhagic areas or blisters. After a couple of days the lesion

may resemble a furuncle or carbuncle. In most cases the process is self-limiting. In the minority of cases the local lesion may be complicated by an aggressive, spreading cellulitis and a subcutaneous suppuration. The patient may present with a nonspecific systemic illness such as fever and malaise 3 - 5 days after the bite. Necrosis at the bite site may take 3 - 7 days to develop, often with an overlying necrotic eschar. The necrotic tissue detaches after about 2 - 3 weeks, leaving an ulcer. The resultant ulcer is slow to heal, with cycles of partial healing followed by breakdown, sometimes extending over months. In a small percentage of patients, violin spider bites may present with severe, sometimes life-threatening systemic illness with haemolysis, coagulopathy, shock, renal failure, and multiple organ damage (loxoscelism). This relatively rare systemic complication, however, has not been described/documentated in southern Africa.

Figs 17 and 18 show sac spider bite and local necrotic tissue.

### Differential diagnosis of necrotic arachnidism

Necrotic arachnidism is an over-diagnosed clinical entity and is often a convenient diagnosis for unexplained local tissue injury/



## Spider bite

dermal necrosis. Recent studies have shown that almost all cases of suspected necrotic arachnidism were caused by other disease states. It is not uncommon for patients to present to healthcare facilities with signs and symptoms that they attribute to a spider bite. In the vast majority of cases, there is no positive history of the person actually having been bitten by a spider, and if so the spider is rarely caught and identified. The violin spider is often specifically blamed in areas where such bites are epidemiologically improbable or impossible. If there is no history of an actual bite, diagnosis and investigations must focus on other important causes of dermal necrotic ulcers. These include infectious (bacteria, fungi, viruses or parasites), inflammatory, vascular, and neoplastic aetiologies.

The following causes of dermal necrosis should be excluded in cases of suspected cytotoxic spider bites/necrotic arachnidism:

- Community-acquired methicillin-resistant *Staphylococcus aureus* and *Streptococcus pyogenes* soft-tissue infection. Necrotising subcutaneous infections caused by mixtures of aerobic and anaerobic pathogens (including *Bacteroides*) that cause necrosis of the subcutaneous tissue, including fascia.
- Sporotrichosis. This is a skin infection caused by the saprophytic mold, *Sporothrix schenckii*, and is known to mimic necrotic arachnidism.
- Tick and other arthropod bites.
- Herpes zoster.
- Vascular occlusive disease.
- Diabetic ulcers (patients with diabetes mellitus seem predisposed to these dermal necroses).
- Erythema multiforme.
- Erythema nodosum.
- Vasculitis.
- Fixed drug eruption.
- Neoplastic disease states.
- Wound infections.

### Special investigations

Depending on the degree, extent and duration of the necrotic skin changes, special investigations should include a full blood count and blood chemistry (e.g. fasting blood sugar, liver and kidney function tests) and microbiological analyses (culture and sensitivity tests). The microbiology laboratory should be consulted prior to collecting specimens so that appropriate material and transport conditions are used for unusual bacteria such as *Mycobacterium* species and fungi. Chest radiography, autoimmune screening tests and a biopsy of the edge of the lesion may be indicated.

### Management

- The majority of lesions are self-limiting and will heal spontaneously.
- Treatment is primarily symptomatic and supportive and should be directed at preventing and treating secondary infections with antimicrobial agents.
- No antivenom is available locally.



Fig. 19. Baboon spider.

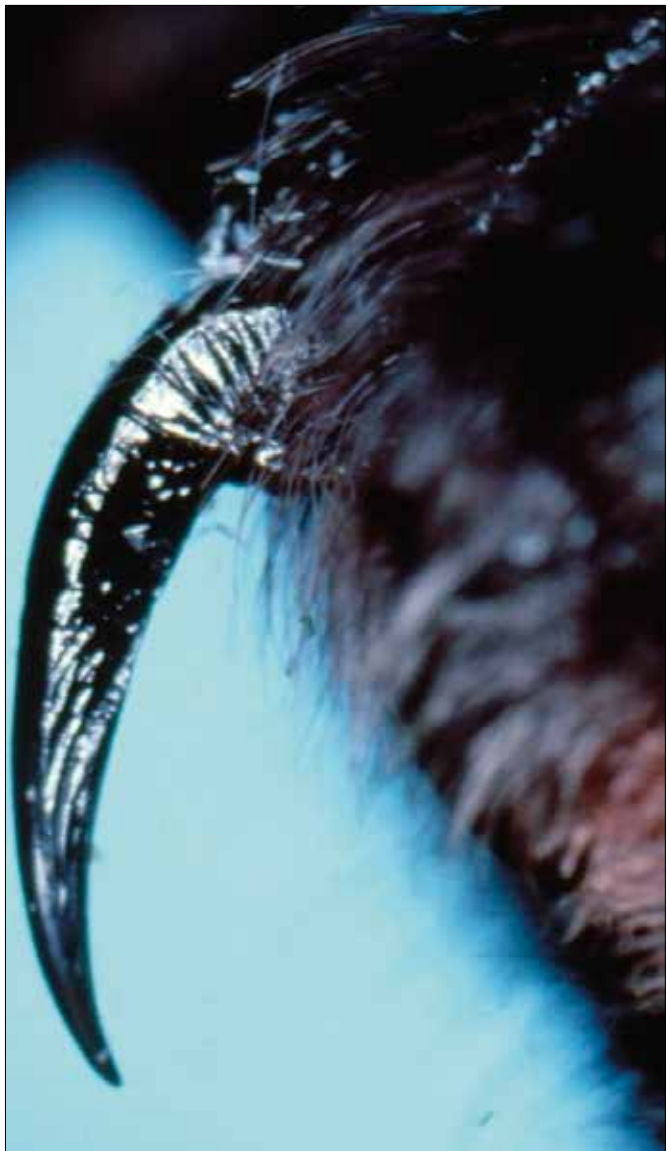

Fig. 20. Fang of baboon spider, often larger than that of the Cape cobra. (Photo: John Visser.)

## Spider bite

- A rapidly spreading cellulitis may occasionally develop which requires aggressive parenteral antibiotic therapy and hospitalisation. *Regular follow-up is therefore necessary in the early stages of suspected necrotic arachnidism.*
- Development of an abscess or suspected necrotising fasciitis is an indication for surgical intervention. A large necrotic area may require excision, with primary or secondary closure. Skin grafts may be required.
- Dapsone has been used with some success in cases of recurrent, chronic necrotic skin lesions, especially those non-responsive to surgical interventions. Dapsone is a potent leucocyte inhibitor (polymorphonuclear) which may interrupt the inflammatory cascade. Adverse effects include methaemoglobinaemia and haemolysis, especially in patients with G6PD deficiency. Weekly monitoring of the full blood count is mandatory. The recommended starting dose is 100 mg twice a day for a week, followed by 50 mg twice a day for 2 weeks or longer.
- Other reported therapies include hyperbaric oxygen, antihistamines (including cyproheptadine), glucocorticosteroids, vasodilators, heparin, nitroglycerine and electric shock. None of these treatment modalities has been found to be beneficial.

### Larger spiders of medical importance

These include the baboon spiders (family: Theraphosidae) and the wandering or rain spiders (genus: *Palystes*).

The baboon spiders are medium to very large spiders (30 - 90 mm) and hairy, with heavy legs. They live in open-ended silk-lined burrows in the ground. When disturbed (gardening, etc.) they are quite aggressive and will rear up with four legs in the air. They can inflict a painful, lacerated, bleeding wound. (The size of their fangs may be bigger than that of the Cape cobra.) No systemic toxic effects have been described in southern Africa. Management includes reassurance (as the patient may be terrified), general wound care, tetanus toxoid and prevention of infection.

Fig. 19 shows the baboon spider. Fig. 20 shows the fang of the baboon spider.



Fig. 21. Wandering or rain spider (Genus: *Palystes*). (Photo: Ansie Dippenaar.)

The wandering or rain spiders (genus *Palystes*) have a body size of up to 40 mm and a leg span of up to 100 mm. They frequently enter houses, usually one or two days before it begins to rain. They are often noticed at night on the walls of rooms where they prey on insects and geckos attracted to light. The egg sac, irregular in shape, about the size of a tennis ball, is often seen in the garden, suspended by silk threads. As in the case of the baboon spider, the rain spider can inflict quite a painful bite. Specific systemic effects have not been documented. Management includes reassurance, general wound care, tetanus toxoid and prevention of infection.

Fig. 21 shows the wandering spider.

Further reading available at [www.cmej.org.za](http://www.cmej.org.za)

## IN A NUTSHELL

- The medically important spiders of southern Africa can be divided into neurotoxic and cytotoxic groups.
- The neurotoxic spiders belong to the genus *Latrodectus* (button or widow spiders) and the cytotoxic spiders are represented chiefly by the genera *Cheiracanthium* (sac spiders) and *Loxosceles* (violin or recluse spiders).
- The venom of the neurotoxic spiders causes massive release of peripheral neurotransmitters leading to generalised stimulation of the somatic and autonomic nerve endings.
- The diagnosis of latrodectism, especially when the patient is unaware of being bitten, or in cases where the culprit has not been identified, can be difficult. The syndrome of latrodectism is notoriously known to mimic other disease states.
- The administration of specific black widow antivenom is the only effective treatment for severe latrodectism. Allergic/anaphylactoid reactions to the antivenom may occur.
- Necrotic arachnidism is the clinical syndrome caused by the bite of cytotoxic spiders (sac and violin spiders). In >90% of cases diagnosis is based solely on clinical findings, as few patients bring the spider with them for identification. The symptoms and signs of sac and violin spider bites are basically similar and the effects of the one can usually not be distinguished from the other.
- Necrotic arachnidism is an over-diagnosed clinical entity and is often a convenient diagnosis for unexplained local tissue injury/dermal necrosis.
- If there is no history of an actual bite, diagnosis and investigations must focus on other important causes of dermal necrotic ulcers. These include infectious (bacteria, fungi, viruses or parasites), inflammatory, vascular, and neoplastic aetiologies.
- Treatment is primarily symptomatic and supportive, which includes antimicrobial therapy.
- No antivenom is available locally.



## Spider bite

### Further reading

- Dippenaar-Schoeman AS, Jocque R. African Spiders. An Identification Manual. Plant Protection Research Institute Handbook No. 9. Biosystematics Division. Pretoria: ARC – Plant Protection Research Institute, 1997.
- Dippenaar-Schoeman AS, Newlands G. The button spiders of South Africa. *Farming in South Africa* 1980;146:1-4.
- Dippenaar-Schoeman AS, Müller GJ. A new species of Steatoda (Araneae: Theridiidae) from South Africa. *Phytophylactica* 1992;24:9-13.
- Finlayson MH. Specific antivenene in the treatment of 'knoppiespider' bite. *S Afr Med J* 1937;11:163-167.
- Finlayson MH. 'Knopie-spider' bite in southern Africa. *Med Proc* 1956;2:634-638.
- Forrester MB, Stanley SK. Epidemiology of spider bites in Texas, 1998 - 2002. *Public Health* 2004;118:506-507.
- Isbister GK, Fan HW. Spider bite. *Lancet* 2011;378(9808):2039-2047.
- Jacobs W. Possible peripheral neuritis following a black widow spider bite. *Toxicon* 1969;6:299-300.
- Martindale CB, Newlands G. The widow spiders: a complex of species. *S Afr J Sci* 1982;78:78-79.
- Moss HS, Binder LS. A retrospective review of black widow spider envenomation. *Ann Emerg Med* 1987;16:188-191.
- Muller GJ. Black and brown widow spider bites in South Africa. *S Afr Med J* 1993;83:399-405.
- Murphy CM, Long JJ, Beuhler MC. Anaphylaxis with *Latrodectus* antivenin resulting in cardiac arrest. *J Med Toxicol* 2011;7:317-321.
- Newlands G, Atkinson P. Review of southern African spiders of medical importance, with notes on the signs and symptoms of envenomation. *S Afr Med J* 1988;73:235-239.
- Newlands G. Arthropods that sting or bite man – their recognition and treatment of the patient. *CME* 1989;7:733-784.
- Offerman SR, Daubert GP, Clark RF. The treatment of black widow spider envenomation with antivenin *Latrodectus mactans*: A case study. *The Permanente Journal* 2011;15:76-81.
- Prins A, Leroux V. South African Spiders and Scorpions: Identification, First-Aid and Medical Treatment. Cape Town: Anubis Press, 1986:19-40.
- Rauber AP. The case of the red widow: a review of latrodectism. *Vet Hum Toxicol* 1980;2 (suppl 2):39-41.
- Rhoads J. Epidemiology of the brown recluse spider bite. *J Amer Acad Nurse Pract* 2007;9: 79-85.
- Rayner BL. The bite of *Latrodectus indistinctus* (button spider). *S Afr Med J* 1987;71:716.
- Russell FE, Marcus P, Streng JA. Black widow spider envenomation during pregnancy: report of a case. *Toxicon* 1979;17:188-189.
- Scheer H, Madeddu L, Dozio N, Gatti G, Vicentini LM, Meldolesi J.  $\alpha$ -Latrotoxin of black widow spider venom: An interesting neurotoxin and tool for investigating the process of neurotransmitter release. *J Physiol* 1984;79:216-221.
- Scheer H, Meldolesi J. Purification of the putative  $\alpha$ -latrotoxin receptor from bovine synaptosomal membranes in an active binding form. *EMBO J* 1985;4:323-327.
- Singletary EM, Rochman AS, Bodmer JCA, Holstege CP. Envenomations. *Med Clin N Am* 2005;89:1195-1224.
- Smithers RHN. Contributions to our knowledge of the genus *Latrodectus* (Araneae) in South Africa. *Ann S Afr Mus* 1944;36:263-313.
- Tzeng M-C, Siekevitz P. The effect of the purified major protein factor ( $\alpha$ -latrotoxin) of black widow spider venom on the release of acetylcholine and norepinephrine from mouse cerebral cortex slices. *Brain Res* 1978;139:190-196.
- Vetter RS, Isbister GK. Medical aspects of spider bites. *Annu Rev Entomol* 2008;53:409-429.
- Visser LH, Khushi SN. Pulmonary oedema from a widow spider bite: a case report. *S Afr Med J* 1989;75:338-339.
- White JAM. Snakebite in southern Africa. *CME* 1985;3(5):37-46.
- Wiener S. Red back spider bite in Australia: an analysis of 167 cases. *Med J Aust* 1961;11:44-49.