

Snake bite in southern Africa: diagnosis and management

There are three groups of venomous snakes in southern Africa – cytotoxic, neurotoxic and haemotoxic.

GJ Müller, BSc, MB ChB, Hons BSc (Pharm), MMed (Anaes), PhD (Tox)

Dr Müller is part-time consultant in the Division of Pharmacology, Department of Medicine, Faculty of Medicine and Health Sciences, Stellenbosch University. He is the founder of the Tygerberg Poison Information Centre.

H Modler, Dip Pharm (Pharmacy), BSc, MB ChB, MMed (Anaes)

Dr Modler is an anaesthetist in private practice, as well as a part-time lecturer and external examiner in pharmacology at the Department of Anaesthesia, Stellenbosch University and the Colleges of Medicine of South Africa.

CA Wium, MSc Medical Sciences

Ms Wium is a principal medical scientist employed as a toxicologist in the Tygerberg Poison Information Centre, Division of Pharmacology, Department of Medicine, Faculty of Medicine and Health Sciences, Stellenbosch University.

DJH Veale, PhD Pharmacology

Dr Veale is the former director of the Tygerberg Poison Information Centre and currently a consultant clinical pharmacist and lecturer in pharmacology and toxicology.

C J Marks, BSc Pharmacy, MSc Medical Sciences

Ms Marks is the director of the Tygerberg Poison Information Centre, Division of Pharmacology, Department of Medicine, Faculty of Medicine and Health Sciences, Stellenbosch University.

Correspondence to: Gert Müller (gmul@sun.ac.za)

Venomous snakes in southern Africa can, in broad terms, be divided into 3 groups: cytotoxic, neurotoxic and those that can induce haemostatic toxic effects. However, significant overlap of these effects may occur. Some snake species may, for example, display both cytotoxicity and neurotoxicity.

See Table 1 at end of article for classification, distribution, habitat and clinical toxinology of venomous snakes of southern Africa.

The identification of the snake responsible for the bite is usually difficult, unless a dead snake is brought into hospital with its victim and can be reliably identified. Descriptions of the snake and the circumstances of the bite may suggest a species diagnosis, but this is not often a satisfactory basis for specific treatment.

In most cases of snake bite appropriate clinical management requires reliable identification of a distinctive clinical syndrome based on epidemiological, clinical and laboratory data. A syndromic approach is, therefore, recommended in the majority of cases.

Main clinical syndromes

Five main clinical syndromes of snake envenoming are recognised in southern Africa:

- marked local pain and progressive swelling associated with prominent cytotoxic skin changes with coagulable blood
- progressive paralysis (neurotoxicity), with negligible or minor local swelling

- incoagulable blood, with negligible to mild local swelling
- moderate to marked local swelling, associated with neurotoxicity
- mild to moderate swelling, with negligible or absent systemic symptoms.

Marked local pain and progressive swelling associated with prominent cytotoxic skin changes with coagulable blood

Snakes responsible for this syndrome include:

- The major adders, e.g. *Bitis arietans* (puff adder) and *B. gabonica* (gaboon adder) (Figs 1 and 2).
- Spitting cobras, e.g. *Naja mossambica* (Mozambique spitting cobra, M'fesi), *N. nigricollis* (black-necked spitting cobra), *N. nigricincta* (barred, zebra spitting cobra) and *N. nigricincta woodi* (black spitting cobra) (Figs 3 - 5).
- The rinkhals, *Hemachatus haemachatus*. Although mild neurotoxic effects have been mentioned to occur in rinkhals bite, these have not been well documented (Fig. 6).

(It should be noted that extensive cytotoxicity with insignificant neurotoxicity has been described after South African green mamba bites.)

For further information with regard to the classification, morphology, habitat and distribution of the above-named snakes, see Table 1 and Figs 7 and 8.

The toxins of cytotoxic snake venom are digestive hydrolases (proteolytic enzymes and phospholipases) and polypeptides that

Snake bite



Fig. 1. Puff adder (*Bitis arietans*). A very large, heavy-bodied snake, maximum total length exceeding 190 cm. Its colour may vary from brown, reddish to orange to very dark, with distinctive pale back edged U or V markings (chevron-like patterns) along the dorsum becoming annular rings around the tail. The belly is pale. When threatened it inflates its body and hisses loudly. Bites are common. (Photo: John Visser.)



Fig. 2. The large adders (vipers) have large, hinged, tubular fangs that can fold back into a protected sheath against the roof of the mouth. When attacking, the fangs are forced forward, enabling a deep penetrating injection of venom. (Photo: John Visser.)

destroy cell membranes, skeletal muscle and other tissues. These effects increase the permeability of the vascular endothelium, which leads to local swelling, blistering and oedema. Irreversible death of tissues may occur (necrosis/gangrene).

Clinical features

The local effects of bites by spitting cobras are essentially similar to those of large adder bites. Swelling usually begins early, often within 10 - 30 minutes. It may become extensive, involving the entire limb and even adjacent areas of the trunk, especially in children. Regional lymph



Fig. 3. Mozambique spitting cobra (*Naja mossambica*). Average length 80 - 130 cm. Above it is black grey to olive brown. Below it is pale or salmon pink, sometimes yellowish with crossbars, half-bars and blotches on the throat and anterior third of the belly. Bites are common. Spits and bites. (Photo: John Visser.)



Fig. 4. Barred or zebra cobra (*Naja nigricincta*). Average length 100 - 120 cm. There are between 50 and 85 black crossbars on a brown or pinkish background. These crossbars usually encircle the body. The head is uniformly black both dorsally and ventrally. (Photo: Tony Phelps.)

nodes may become enlarged and painful within 30 - 60 minutes. The aggressive and progressive cytotoxic nature of envenoming is usually evident within hours of the bite. Blisters and bullous skin lesions, fluid or blood filled, and ecchymoses often develop, at first near the fang marks, but may later extend beyond the bite site within 6 - 24 hours.

'Skip lesions' (areas of necrosis separated by strips of apparently normal skin caused by proximal spread of venom in lymphatic vessels) are characteristic of spitting cobra bites (Fig. 10). Spitting cobras frequently enter dwellings at night and often bite victims while asleep.

Extravasations of plasma may cause hypovolaemia, which may lead to hypovolaemic shock, especially in children. The local cytotoxic effects may progress to necrosis, with spontaneous sloughing of dead tissue. Compartmental syndromes may develop, especially

Snake bite



Fig. 5. Black spitting cobra (*Naja nigricincta woodi*). Average length 120 - 150 cm; uniformly black. Spits and bites. (Photo: John Visser.)



Fig. 6. Rinkhals (*Hemachatus haemachatus*). Average length 1 m. Colour variable, but normally olive to dark brown or dull black above and below with one or two white crossbars on the throat. Specimens in the south-western and eastern Cape display numerous orange-yellow crossbands. (Photo: John Visser.)

involving the anterior tibial compartment after bites of the feet and ankles, or forearm, in bites of the hand or wrist. This complication may lead to ischaemic necrosis of the compartmental muscles and nerve damage. Late (2 - 3 days post bite) haemostatic disturbances, especially thrombocytopenia, have been described in puff adder and gaboon adder bites.

Gaboon adder bites may be accompanied by cardiovascular abnormalities, including hypotension, cardiac dysrhythmias and shock. Fortunately these bites are rare.

Fig. 9 (a - d) shows the local toxic effects of a puff adder bite. Fig. 10 shows the effects of spitting cobra bites.

Special investigations

Abnormal blood biochemistry, such as raised serum concentrations of creatine kinase and other muscle-derived enzymes, is commonly found in severe envenoming because of local muscle damage. Neglected major adder bites may be complicated by rhabdomyolysis, with release of muscle contents into the plasma (myoglobinaemia), manifesting with myoglobinuria, which may lead to compromised renal function. Thrombocytopenia is also a potential complication. Special investigations should therefore include urinalysis, urea, serum creatinine, electrolytes, and full blood count (including the blood clotting profile).

Neglected major adder bites may be complicated by rhabdomyolysis, with release of muscle contents into the plasma (myoglobinaemia), manifesting with myoglobinuria, which may lead to compromised renal function.

Snake venom ophthalmia is eye envenoming that occurs when venom is spat into the eyes (see under ancillary treatment).

Antivenom is available for bites of the abovementioned snakes (SAIMR Polyvalent Snakebite Antiserum SAVP).

Progressive paralysis (neurotoxicity), with negligible or minor local swelling

Snakes responsible for this syndrome include:

- Neurotoxic cobras: *Naja anchietae* (Anchieta's Egyptian cobra), *N. annulifera* (banded or snouted cobra), *N. melanoleuca* (forest, black and white-lipped cobra) and *N. nivea* (Cape cobra) (Figs 11 and 12). See Fig. 13 for distribution of neurotoxic cobras and Table 1 for classification and other information.
- Mambas: *Dendroaspis polylepis* (black mamba) and *D. angusticeps* (common, eastern green, white mouthed mamba).

Snake bite

It should be noted that extensive cytotoxicity with insignificant neurotoxicity has been described after South African green mamba bites (Figs 14 and 15). See Fig. 16 for distribution of mambas and Table 1 for classification and other information.

The venoms of neurotoxic cobras contain polypeptides that compete with acetylcholine for binding at post-synaptic nicotinic receptors at skeletal muscle nerve junctions, leading to a curare-like paralysis. Mamba venom, in addition to its effects on post-synaptic nicotinic receptors, also contains polypeptide toxins, which facilitate the release of acetylcholine from the nerve endings (dendrotoxins), as well as toxins which inhibit synaptic acetylcholinesterases

(fasciculins). Neurotoxins that block muscarinic receptors have also been described in mamba venom. See Fig. 4 in the article on scorpion sting with regard to the mechanisms of action of neurotoxic venoms on the peripheral nervous system.

Clinical features

Neurotoxicity is characterised by progressive, descending flaccid paralysis. Early symptoms and signs include transient paraesthesia of the tongue and lips, blurred and double vision and ptosis, pupillary abnormalities (e.g. dilated pupils), external and internal ophthalmoplegia and paralysis of facial muscles and other muscles innervated by the cranial nerves, leading to dysarthria, dysphonia,

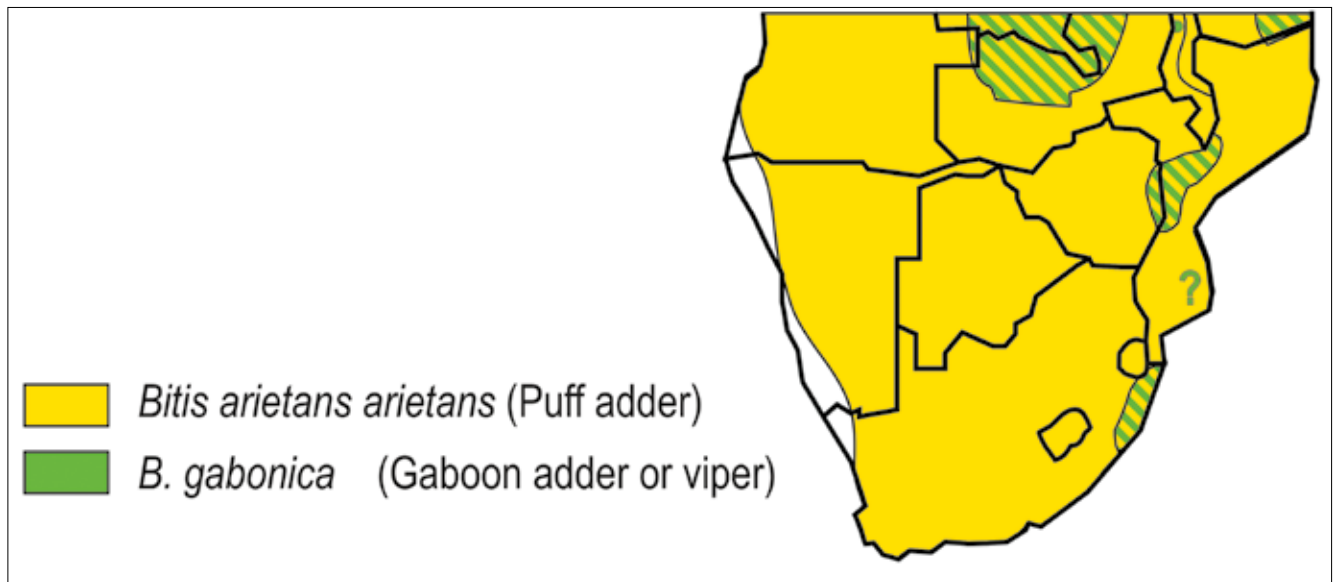


Fig. 7. Distribution of the major adders in southern Africa. All composite maps have been compiled by GJ Müller with reference to the locations published in Spawls S and Branch B: *The Dangerous Snakes of Africa*. London: Southern Book Publishers, 1995 and Visser J: *Dangerous Snakes and Snakebite*, published by John Visser (no date).

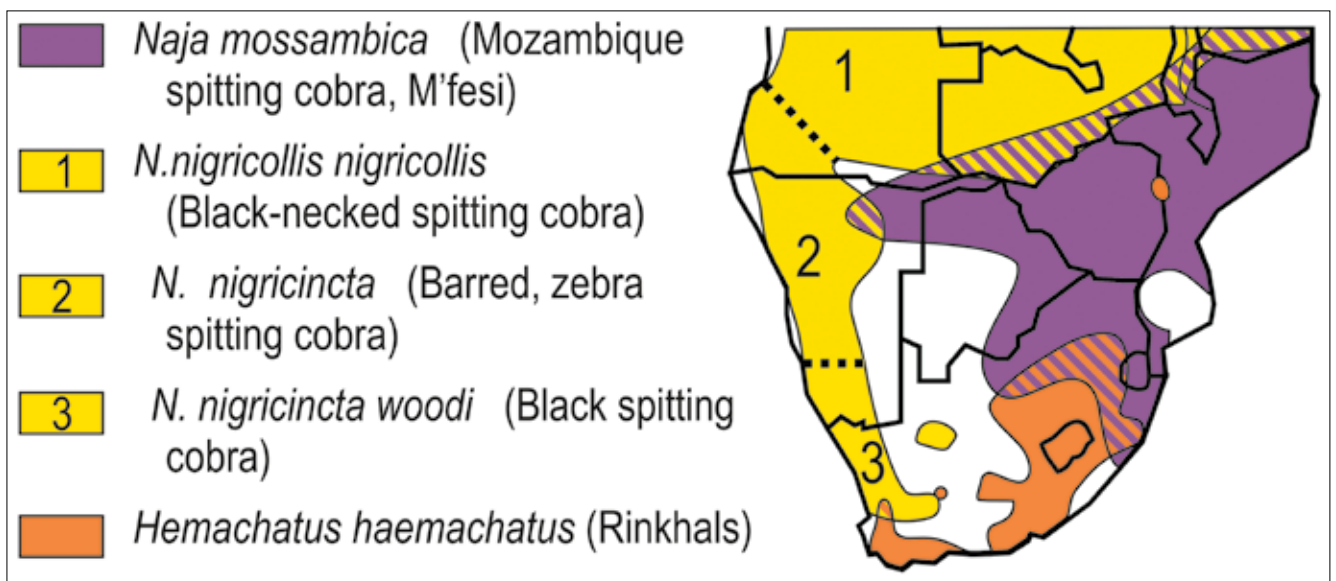


Fig. 8. Distribution of the spitting cobras and rinkhals in southern Africa.

Snake bite

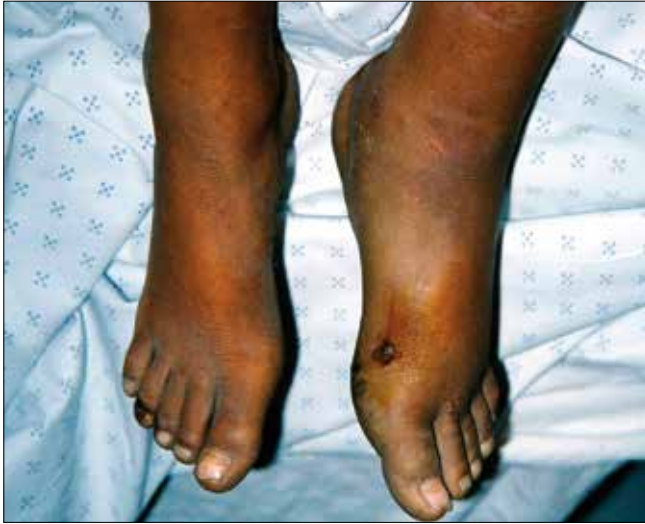

Fig. 9a. Puff adder bite. Progression of local cytotoxic effects 6 hours post bite.

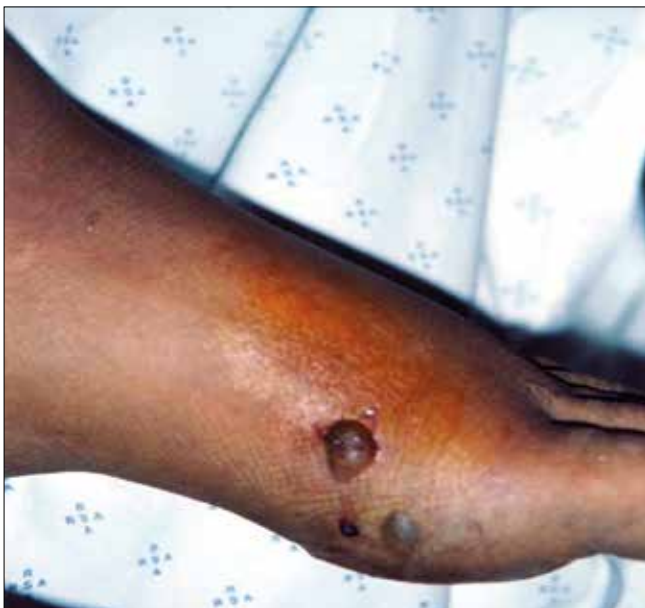

Fig. 9b. Puff adder bite. Progressive local swelling 6 hours post bite.

and dysphagia. There is an increase in oro-pharyngeal secretions due to difficulty in swallowing. This is followed by progressive, descending paralysis, and finally respiratory failure. As respiratory distress increases, the patient becomes anxious, sweaty and cyanosed and will die unless given ventilatory support. Neurotoxic snakes can cause life-threatening paralysis and death within 1 - 8 hours. Respiratory failure is usually the primary cause of death. Fig. 17 depicts ptosis after a Cape cobra bite.

In addition to the above neurotoxic effects, patients bitten by mambas may present with trembling, skeletal muscle fasciculations and signs of autonomic nervous system stimulation (due to increased acetylcholine activity in the synaptic cleft – see mechanisms above). Early features

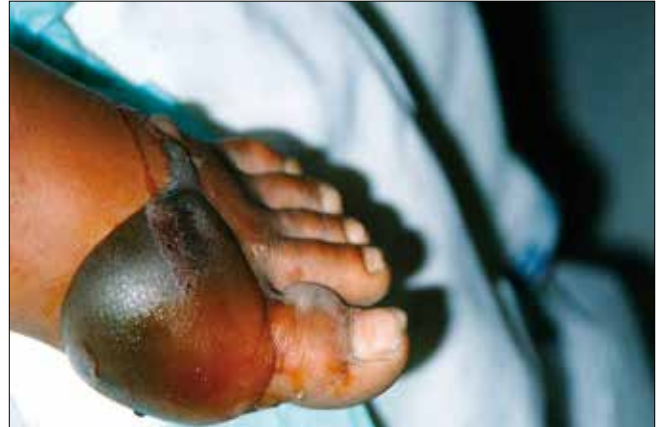

Fig. 9c. Puff adder bite 12 hours post bite.

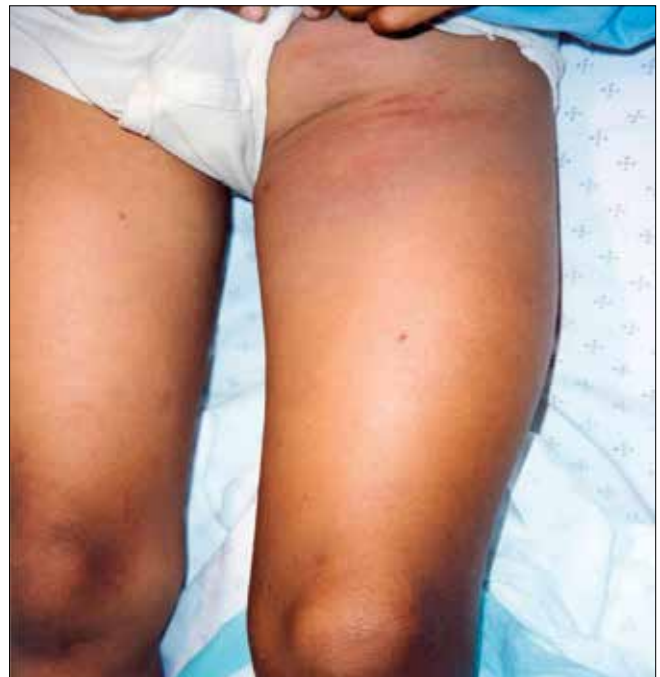

Fig. 9d. Puff adder bite 18 - 24 hours post bite. Swelling involving the whole limb extending to the lower abdomen. Note the ecchymotic skin lesions.

are vomiting, chest and limb pains and excessive salivation. Cardiac dysrhythmias have also been described in mamba bite victims.

Patients bitten by elapid neurotoxic snakes may present with pain at the bite site and varying degrees of minor local swelling. However, in some envenomed patients the bite site is difficult to locate/identify. Necrosis and other local cytotoxic effects do not usually develop to any significant degree. Fig. 18 shows minimal local swelling with Cape cobra bite, while Fig. 19 demonstrates that in some cases of Cape cobra envenomed patients the bite site is difficult to locate/identify.

Special investigations, where appropriate, should include arterial blood gas and other respiratory function tests and an ECG.

Snake bite

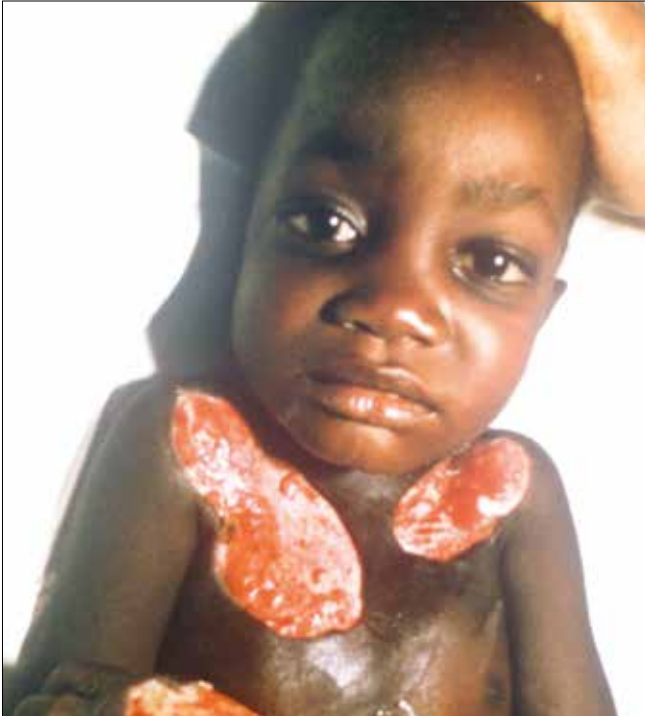

Fig. 10. A single bite on the left hand inflicted by a barred spitting cobra 2 weeks previously was responsible for the 'skip' lesions on the shoulder and chest. (Photo: John Visser.)

Differential diagnosis of neurotoxic snake bite

The diagnosis of elapid neurotoxic snake bite, especially when the patient is unaware of being bitten or where the culprit has not been identified, may occasionally be difficult. Clinical conditions that should be considered in the differential diagnosis include scorpionism and latrodectism. See Table 1 in the scorpion sting article for a comparison of major symptoms and signs of scorpionism, latrodectism and neurotoxic cobra bite. In neurotoxic/cytotoxic berg adder bite the cytotoxic component of envenoming is quite prominent when compared with the minimal local effects of elapid neurotoxic snake bite. Antivenom is available for bites of the abovementioned snakes (SAIMR Polyvalent Snakebite Antiserum SAVP).

Incoagulable blood, with negligible to mild local swelling

Snakes responsible for this syndrome include:

- boomslang (*Dispholidus typus*) (Figs 20 and 21)
- South eastern Savanna vine/bird/twig snake (*Thelotornis capensis*)
- Oate's savanna vine snake (*Thelotornis capensis oatesi*).

Fig. 21 demonstrates the position of boomslang fangs. See Fig. 22 and Table 1 for distribution of boomslang and bird snake.

Venom of the boomslang has potent pro-coagulant effects by activating factors II (prothrombin), X and possibly also IX. Severe consumptive coagulopathy develops within several hours (4 - 24 hours) after the bite. See Fig. 23, in which the blood coagulation cascade is depicted.



Fig. 11. Cape cobra, 'geelslang', 'bruinkapel' (*Naja nivea*). The average length is 150 - 180 cm. The colour of the Cape cobra is extremely variable, ranging from bright yellow, brown, reddish brown to black. Lighter copper-coloured specimens often have brown speckles. Undersurface yellowish white. All colour phases usually occur in one locality. Like all Elapidae, it spreads an impressive hood when confronted. Envenomings common in the south eastern regions of the country. (Photo: John Visser.)

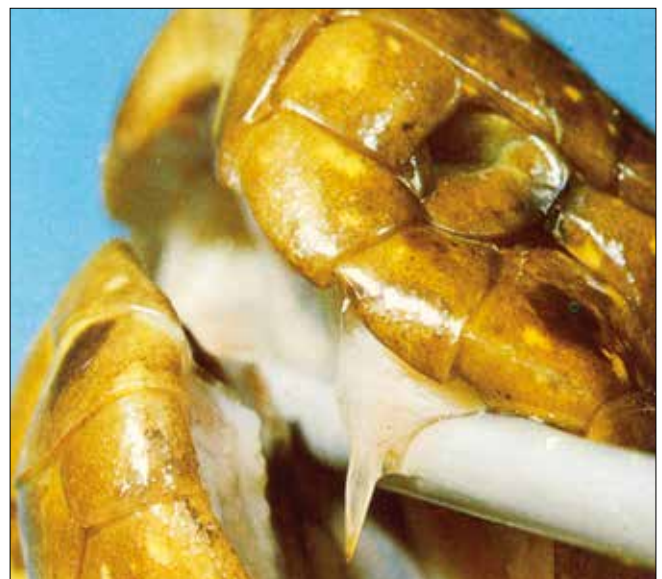

Fig. 12. The Elapidae have rigid, hollow, short fixed fangs in the front of the mouth. (Photo: John Visser.)

Snake bite

Clinical features

Patients may present with nausea, vomiting, abdominal pain, headache, dizziness and fainting. Persistent oozing of blood from fang punctures or other wound sites is often observed. Although bleeding may occur within 6 - 24 hours after a bite, systemic haemostatic symptoms and signs may be delayed for more than 24 hours, even days after the bite. Bleeding usually manifests as gingival bleeding, epistaxis, purpura, haematemesis, melaena, haematuria, extensive ecchymoses, and in severe cases, subarachnoid or intracerebral haemorrhage. Severe consumptive coagulopathy may lead to multiple organ failure. There is local pain with insignificant or mild local swelling.

Special investigations reveal incoagulable blood, defibrination, elevated fibrinogen degradation products, thrombocytopenia and anaemia. Incoagulable blood is a cardinal sign of consumptive coagulopathy. To confirm this, the '20 minute whole blood clotting test' is a simple, rapid test of blood coagulability, which can be performed at the bedside and correlates well with the fibrinogen concentration. A few milliliters of blood taken by venepuncture is placed in a new, clean, dry glass vessel and left undisturbed at room temperature for 20 minutes, then tilted once to see whether or not the blood has clotted. Other more sensitive laboratory tests include prothrombin time (often reported as INR), thrombin and fibrinogen levels, activated partial thromboplastin times and measurement of fibrinogen degradation products and D-dimer concentrations. Other laboratory investigations should include urinalysis, full blood count, urea and electrolytes and serum creatinine.

Antivenom is available for boomslang bite (SAIMR Boomslang Snakebite Antiserum SAVP). No antivenom is available for vine/bird twig (*Thelotornis*) snake bites.



Fig. 14. Black mamba (*Dendroaspis polylepis*). It is more heavily built than other mambas. Average length is 240 - 300 cm. It is coloured greyish brown to olive brown and never entirely black. Its name is derived from the colour of the inside of the mouth, which is blue-black. Undersurface uniform olive green. (Photo: John Visser.)

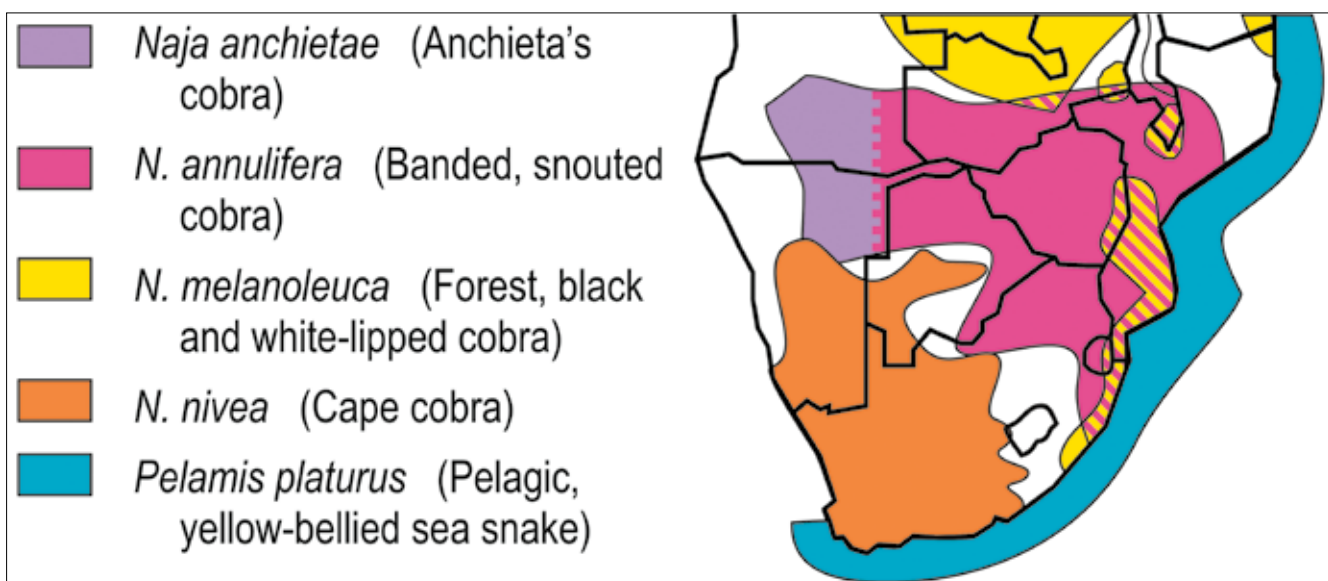


Fig. 13. Distribution of neurotoxic cobras and the sea snake in southern Africa.

Snake bite



Fig. 15. Green mamba (*Dendroaspis angusticeps*). Average length 180 - 200 cm. It is coloured uniformly bright green with undersurface pale green. The mouth lining is bluish white. (Photo: John Visser.)

Moderate to marked local swelling, associated with neurotoxicity

Snakes responsible for this syndrome include:

- berg adder (*Bitis atropos*) (Fig. 24)
- other small/dwarf adders (side-winding adder – *B. peringueyi* and desert mountain adder – *B. xeropaga*).

See Fig. 25 and Table 1 for distribution and classification of the dwarf adders.

Phospholipase A₂ neurotoxins are responsible for the toxic effects of these snake venoms. The neurotoxins act presynaptically, initially releasing acetylcholine, followed by an interference with or blockade of its release.

Clinical features

After initial pain and the development of local swelling, paraesthesiae of the tongue and lips, blurring of vision and the loss of the sense of smell (anosmia) and taste, and dysphagia develop, often within 2 - 3 hours of the bite. External and internal ophthalmoplegia are characterised by ptosis, fixed dilated pupils and loss of eye movements and accommodation. Muscle weakness and respiratory failure are common complications (in >50% of cases) and typically

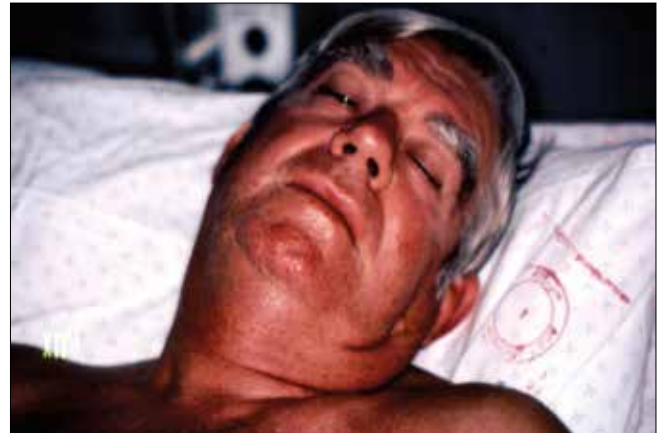

Fig. 17. Demonstration of ptosis after a Cape cobra bite.

develop late (6 - 36 hours after the bite), often at a stage when not anticipated or expected.

Hyponatraemia, attributable to a natriuretic hormone-like toxin present in the venom, is also a frequent complication. It typically develops late (24 - 36 hours post bite). If undetected this may lead to unexpected convulsions (see further under management).

Ophthalmoplegia and anosmia may take quite a long time to resolve (weeks to months).

The local effects include moderate to marked local swelling. Swelling may involve more than half the bitten limb. Blistering and necrosis may develop in the region of the bite site. Extensive cytotoxic skin changes and compartmental syndromes are not expected to develop.

Fig. 26 shows ptosis after a berg adder bite and Fig. 27 a berg adder bite demonstrating local swelling. Fig. 28 shows local necrotic changes after a berg adder bite.

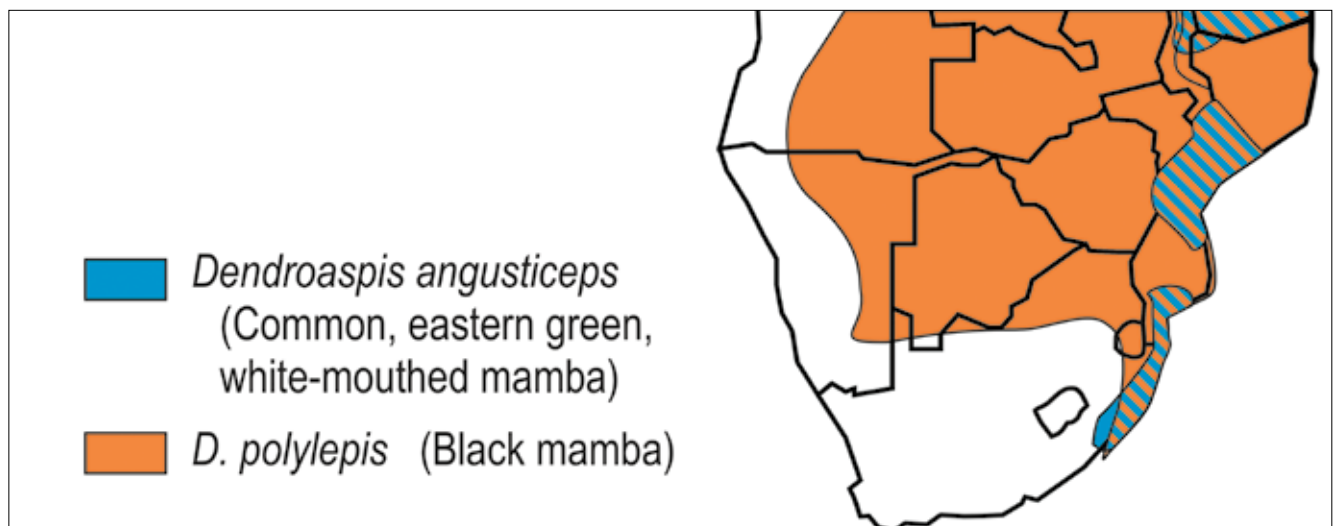


Fig. 16. Distribution of mambas in southern Africa.

Snake bite

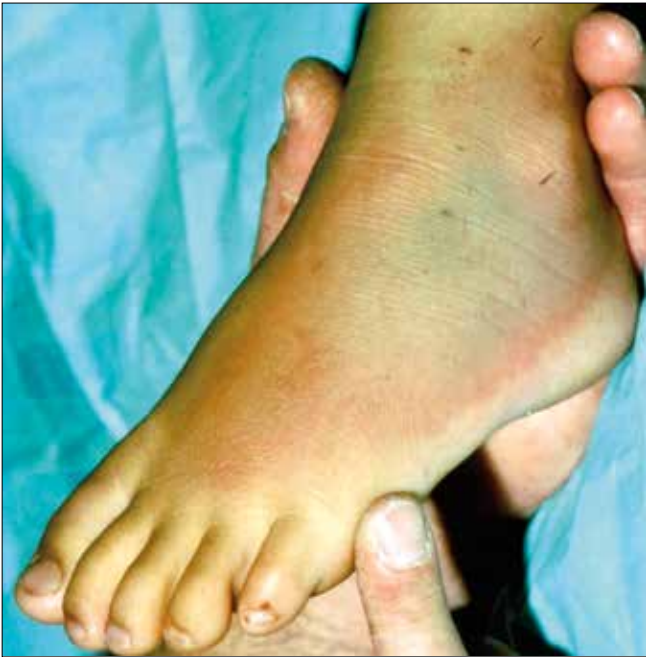

Fig. 18. Cape cobra bite. The area shown on the foot of a paralysed patient 4 days after the bite, demonstrating minimal swelling. (Photo: John Visser.)

Recommended special investigations should include urinalysis, urea and electrolytes, full blood count, oxygen saturation and other respiratory function tests. Specific attention should be given to the plasma sodium level. The sodium level should be recorded at regular intervals until hyponatraemia is noted or until such time as hyponatraemia has been excluded, e.g. at 4 days after envenoming.

No antivenom is available for berg adder and other dwarf adder bites.

Mild to moderate swelling, with negligible or absent systemic symptoms

Snakes responsible for this syndrome include:

- night adder (*Causus rhombeatus*) (Fig. 29)
- burrowing asp (*Atractaspis bibronii*) (Fig. 30)
- Natal black snake (*Macrelaps microlepidotus*)
- some dwarf adders, e.g. horned adder (*Bitis caudalis*) (Fig. 31).

Figs 32 and 33 show the distribution of the night adders, burrowing asp and the Natal black snake.

Clinical features

Associated symptoms and signs include local pain, regional lymphadenopathy and fever. Swelling rarely involves more than half of the bitten limb. Blistering and necrosis may develop at the bite site. Extensive cytotoxic skin changes and compartmental syndromes are not expected to develop. Bites by the Natal black snake are said to have resulted in collapse and loss of consciousness.

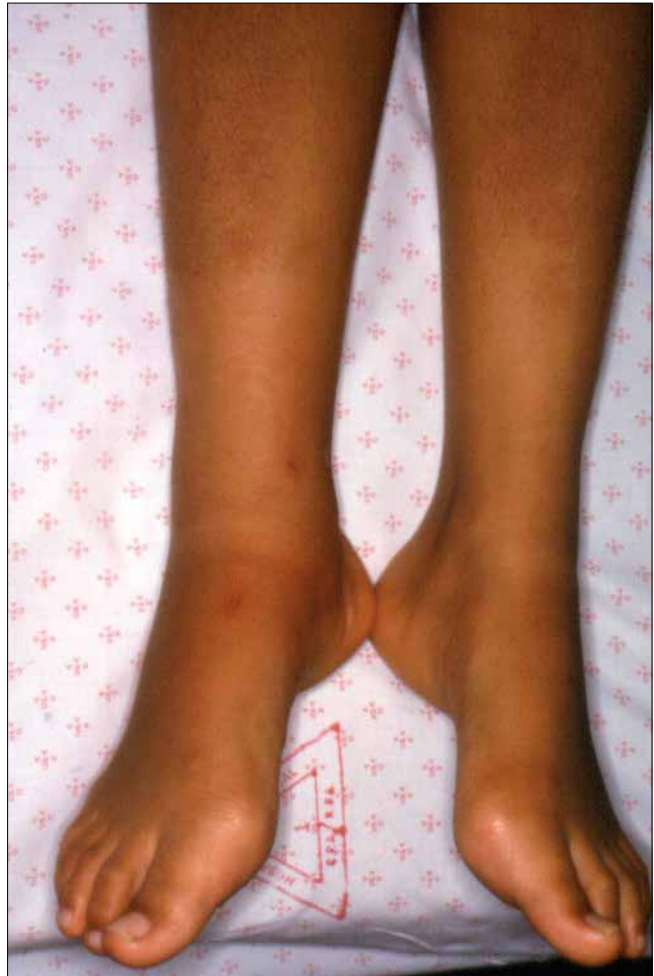

Fig. 19. Patient was completely paralysed 4 hours after a Cape cobra bite, requiring respiratory support. Note that the bite mark is difficult to locate on the right ankle.



Fig. 20. Boomslang (*Dyspholidus typus*). Average length 120 - 150 cm. It has a short chunky head with very large emerald green eyes. The colour may vary from green, brown, black to reddish, with a lighter belly. When cornered, they inflate the anterior part of the body. (Photo: John Visser.)

Snake bite



Fig. 21. The colubridae (back-fanged snakes) have small, grooved fangs that are situated far back in the mouth below the eye. Species include the boomslang and vine snake. (Photo: John Visser.)

Minor envenoming by spitting cobras and major adders should be considered in the differential diagnosis in cases where the snake has not been identified. Special investigations should include urinalysis and a full blood count.

No antivenom is available for bites of the above-mentioned snakes.

For information with regard to envenoming by the lesser known or poorly documented venomous snakes (e.g. garter and coral snakes) consult Table 1.

Management of snake bite

First aid and general management

- While instituting first aid procedures, organise transport to get the patient to a medical facility as soon as possible. Use a cell

phone and other forms of communication to call for help. Alert the medical facility or doctor ahead of arrival.

- Reassure the victim, who may be terrified.
- Remove constricting clothing, rings, bracelets, bands, shoes, etc. from the bitten limb/area.
- Immobilise the whole patient.
- Avoid the many harmful and time-wasting traditional first-aid treatments such as cauterisation, local incision or excision, tattooing, immediate prophylactic amputation of the bitten digit, suction by mouth or vacuum pumps or 'venom-ex' apparatuses, instillation of chemical compounds such as potassium permanganate, application of petrol, ice packs, 'snake stones' and electric shocks. The above measures are contraindicated as they are potentially harmful and none has any proven benefit.
- In suspected neurotoxic cobra or mamba bite, especially if the patient is far from medical help, apply a tight crepe bandage over and proximal to the bite site. This procedure may reduce rapid distribution of the venom. Avoid crepe or other bandaging in all cytotoxic bites.
- The classic 'pressure-immobilisation technique' demands special equipment and training and is considered not practicable for general use in South Africa.
- A tight arterial tourniquet should NEVER be used! The dangers of tourniquets include the development of ischaemia and gangrene if they are applied for more than about 1½ hours.
- Since species diagnosis is important, the dead snake should be taken along to hospital. However, if the snake is still at large, do not risk further bites.
- In suspected neurotoxic snake bites, the patient should be assessed regularly (e.g. every 10 - 15 minutes) for the development of complications of neurotoxicity.
- Cardiopulmonary resuscitation (CPR) may be needed. This includes clearance of the airway, oxygen administration by face mask or nasal catheters, and establishment of intravenous access.

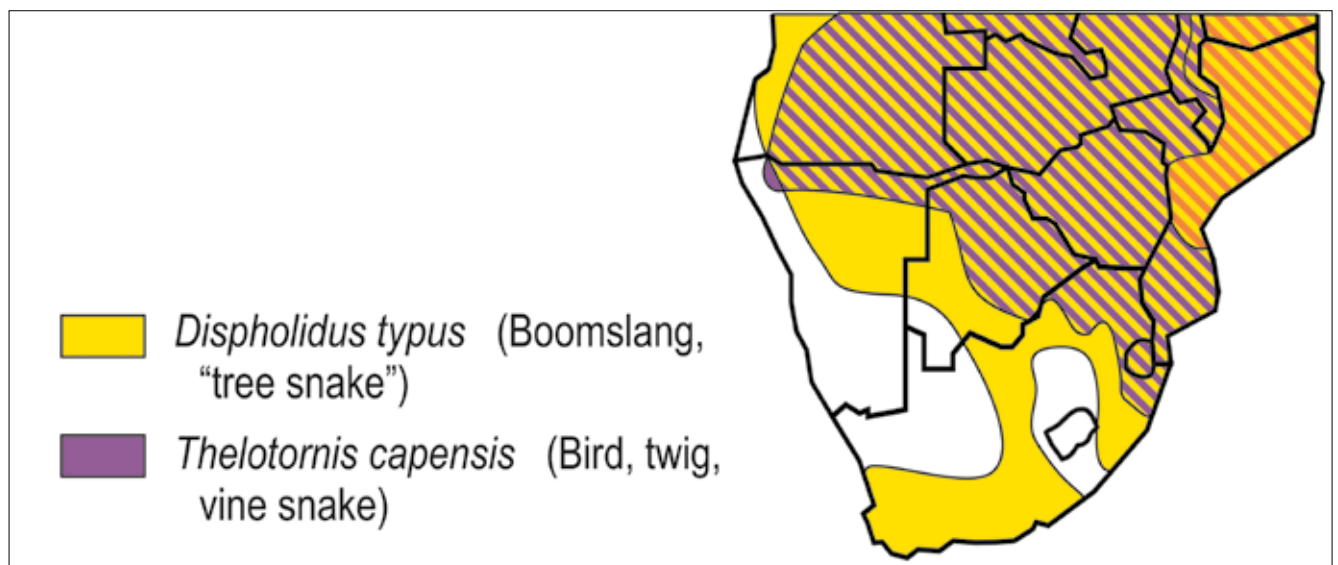


Fig. 22. Distribution of boomslang and bird snake in southern Africa.

Snake bite



Fig. 24. Berg adder (*Bitis atropos*). The berg adder is a stoutly built viper, average length 30 - 40 cm. Greyish-olive to dark brown, with two rows of triangular black dorsal markings and an off-white belly with grey infusions. (Photo: John Visser.)

If the patient is unresponsive and no respiratory movement is detectable, start CPR. In case of respiratory distress/failure: clear the airway, lift the chin, give oxygen by face mask or nasal

catheters with or without assisted ventilation and consider the need for endotracheal intubation. Shocked, hypotensive patients should be given intravenous fluids. Pressor agents, such as dopamine or phenylephrine may need to be administered.

- Give analgesia by mouth if required: paracetamol (acetaminophen) or paracetamol/codeine combinations are preferred. Aspirin and other non-steroidal anti-inflammatory agents should be avoided in patients with haemostatic disorders. When using parenteral opioids in neurotoxic snake bite, respiratory function should be monitored closely.
- In the cases of berg adder bite, hyponatraemia should not be treated by means of fluid restriction, but rather by a titrated infusion of hypertonic saline. In this respect the administration of normal saline may prove useful as a means of partially meeting both fluid and salt requirements.
- In cases where the snake has not been identified it is recommended that asymptomatic patients be admitted to a medical facility for observations for 12 - 24 hours.

Antivenom treatment

Two snakebite antivenoms are available:

- Polyvalent antivenom (SAIMR Polyvalent Snakebite Antiserum SAVP) is supplied in 10 ml ampoules. Venoms of the following snakes are used as antigens in the preparation of the polyvalent antivenom: puff adder, gaboon adder, rinkhals, green mamba,

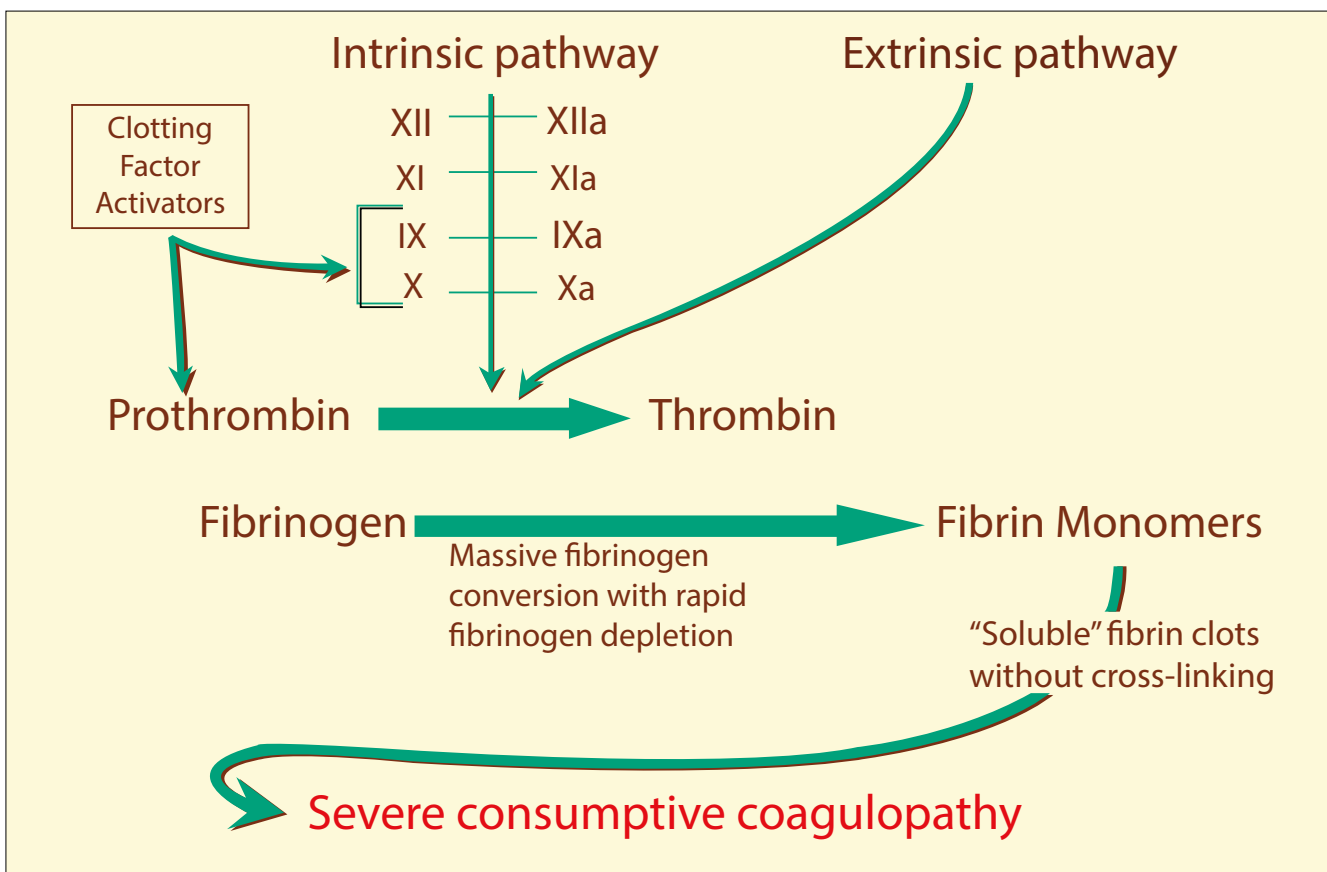


Fig. 23. Blood coagulation cascade.

Snake bite

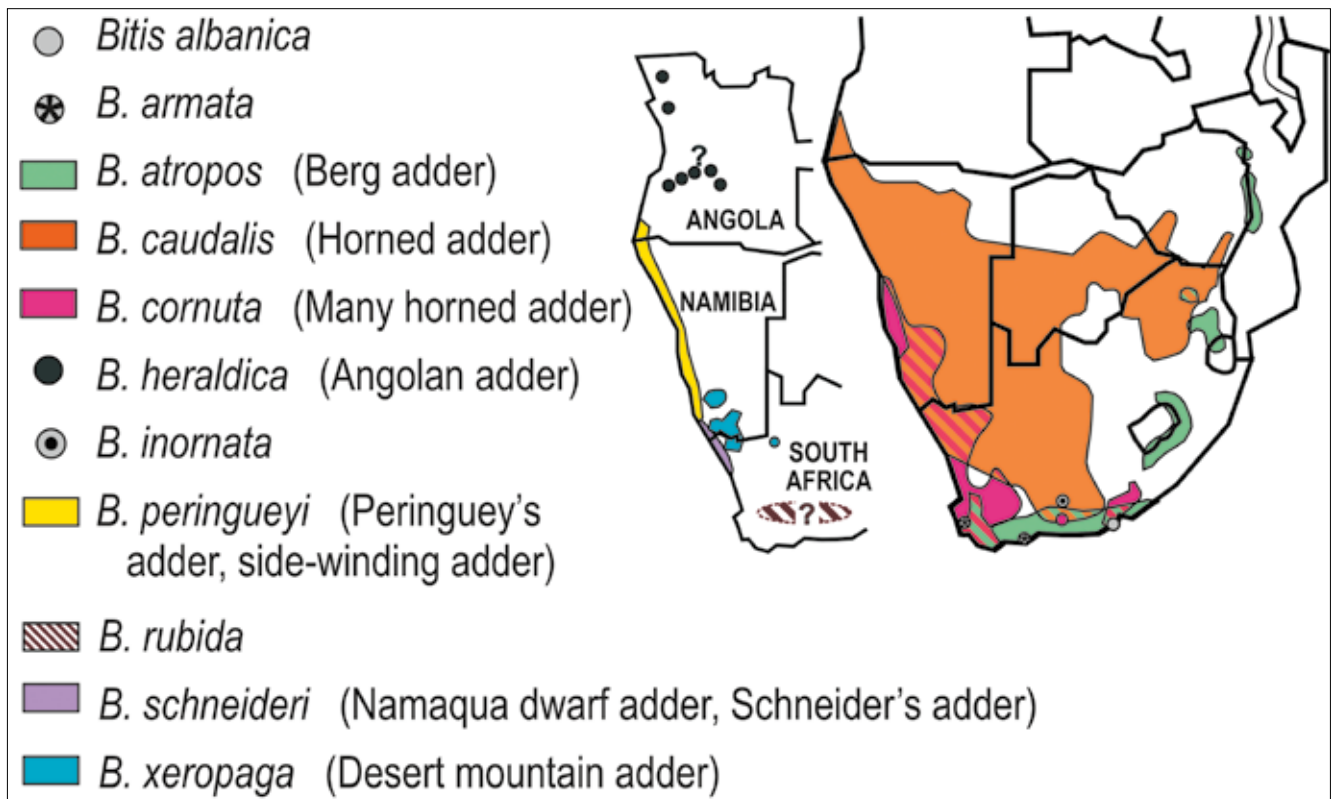


Fig. 25. Distribution of dwarf adders in southern Africa.

Jameson's mamba, black mamba, Cape cobra, forest cobra, snouted cobra and Mozambique spitting cobra. Polyvalent antivenom is ineffective AND SHOULD NOT BE USED in treatment of bites caused by the berg adder, other dwarf adders, night adders, the burrowing asp and back-fanged snakes (boomslang and vine snake).

- Boomslang antivenom (SAIMR Boomslang Snakebite Antiserum SAVP) is supplied in 10 ml ampoules. It is effective against the venom of boomslang, but not against the venom of the vine snake (bird of twig snake).

Antivenom neutralises a fixed amount of venom. Since snakes inject the same amount of venom into adults and children, the same dose/volume of antivenom must be administered to children as in adults.

Antivenom is not always necessary: some patients are bitten by non-venomous snakes and 10 - 50% of those bitten by venomous snakes are not envenomed (so called 'dry bites').

Indications for antivenom treatment after bites by South African snakes:

- neurotoxicity
- abnormal blood clotting parameters, incoagulable blood and/or spontaneous systemic bleeding
- rapidly progressive and/or extensive swelling involving more than half the bitten limb within a few hours after the bite

- cardiovascular abnormalities such as hypotension, shock and cardiac arrhythmias.

Precautions

Skin testing for sensitivity is not recommended, since it is unreliable and only delays urgent administration of antivenom.

Administration of antivenom may be associated with acute life-threatening adverse reactions (anaphylaxis), pyrogenic (feverish) reactions, or late immune complex disease (serum sickness). Most acute/severe allergic reactions occur during the first hour after antivenom administration and only a negligible number occur more than 6 hours post administration.

There is no absolute contraindication to antivenom treatment when a patient has life-threatening systemic envenoming. However, patients with an atopic history and those with a history of previous reactions to equine antisera have an increased risk of severe antivenom reactions. In these cases, pretreatment with subcutaneous adrenaline, 0.25 ml of a 1:1 000 (250 µg) solution in adults is justified to prevent or diminish the reaction. In children the dose of adrenaline is 0.01 mg/kg. Some experts recommend prophylactic adrenaline in all patients. Patients in whom adrenaline is relatively contraindicated include those with a history of ischaemic heart disease or stroke, uncontrolled hypertension and tachyarrhythmias.

Snake bite

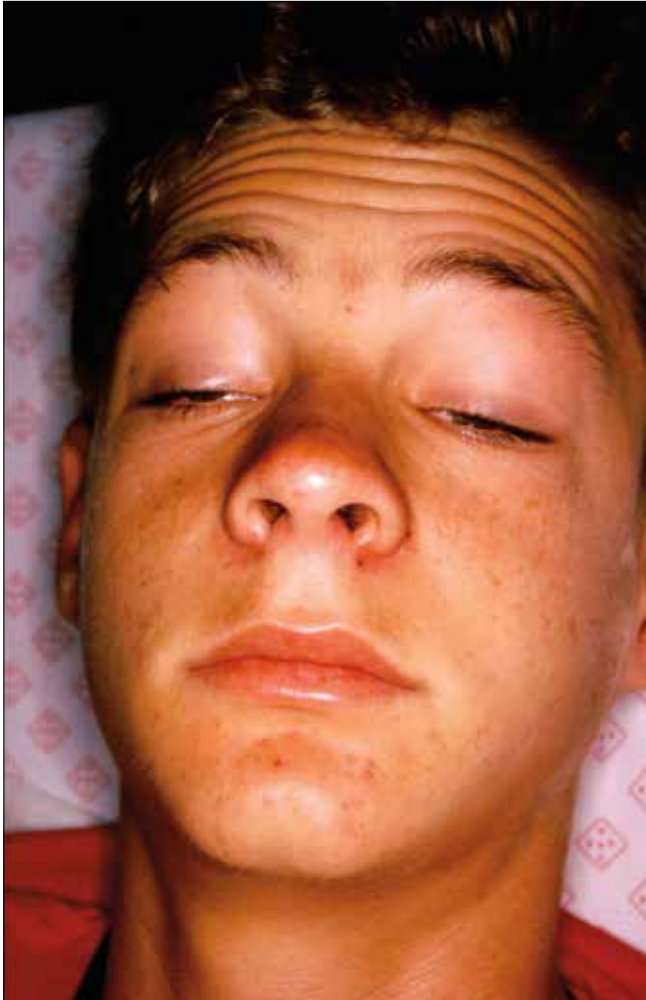

Fig. 26. Ptosis in berg adder bite. The patient is contracting the frontalis muscle in an attempt to open his eyes.

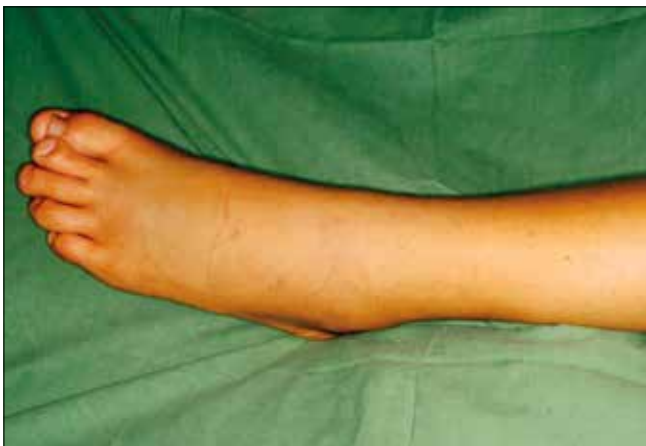

Fig. 27. Prominent swelling of lower limb after berg adder bite on base of big toe.

Premedication with antihistamines may dampen minor allergic reactions but will not prevent serious allergic/anaphylactoid

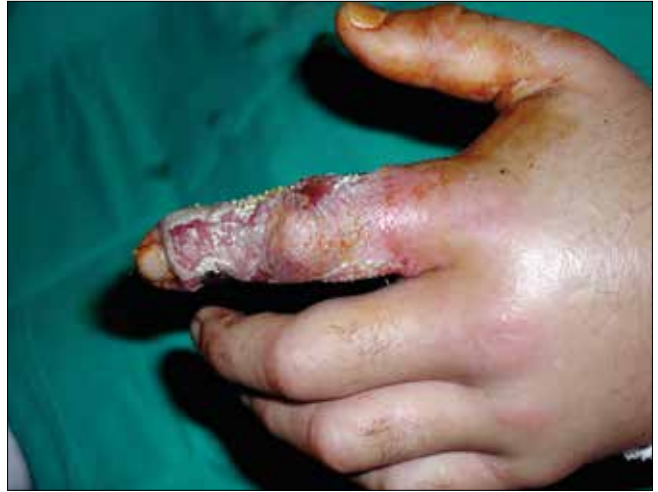

Fig. 28. Berg adder bite 6 days post bite showing local necrotic changes.



Fig. 29. Night adder (*Causus rhombeatus*). Average length 30 - 60 cm. The head has a distinct dark brown or black forward pointing V-shaped mark. There are 20 - 30 dark, pale-edged rhombic blotches along the back. The belly is pearly white to yellowish or light grey. (Photo: John Visser.)

reactions. Hydrocortisone takes several hours to act and is ineffective as a prophylactic agent against acute reactions.

Slow infusion of the antivenom, rather than administration by bolus, is recommended as a method of reducing serious antivenom reactions (be aware of acute fluid overload in children).

Dose and methods of administration

Children should be given the same dose of antivenom as adults. Antivenom should be given as soon as possible once signs of systemic or severe local envenoming are evident. Although the polyvalent antivenom is more effective when given early (within 6 hours after the bite) it may be administered up to 24 - 48 hours or later in serious envenomations – it is never too late to give antivenom.

Snake bite



Fig. 30. Burrowing asp or southern stiletto snake (*Atractaspis bibronii*). Average length 30 - 40 cm. Dorsally it is uniformly purple-brown to black. Below it is creamy white or dark brown to black. When the snake bites, the fangs are exposed out of the side of the mouth and are then hooked or jabbed into the victim with a backward jerk of the head. (Photo: Tony Phelps.)

Antivenom is most effective when given intravenously. It should be diluted in isotonic fluid and infused over 30 - 60 minutes (in most cases a 200 ml volume container is adequate). Intramuscular injection is not recommended. Do not inject antivenom into or around the wound.

The recommended intravenous dose of polyvalent antivenom in serious cytotoxic snake bite (puff adder, gaboon adder) is 50 - 100 ml (5 - 10 ampoules). In neurotoxic snake bite (mambas, neurotoxic cobras) the recommended dose is 80 - 120 ml (up to 200 ml in severe cases of mamba bites). A follow-up dose may occasionally be required in black mamba bites.

The recommended dose of boomslang antivenom is 20 ml (2 ampoules) intravenously in isotonic fluid given over 30 minutes. A follow-up dose of 10 ml may sometimes be necessary.

Response to antivenom treatment

Neurotoxic signs improve slowly after several hours (2 - 6 hours), often unconvincingly. It must be emphasised that the administration of polyvalent antivenom in the acute phase of neurotoxic snake envenoming will usually not prevent progression of neurotoxic effects, most notably respiratory paralysis, and consequently the patient will not survive without life support. Respiratory support is the only life-saving treatment modality in neurotoxic snake envenoming. However, intravenous administration of adequate doses of antivenom will decrease the time course of muscle paralysis and recovery. Similarly, in cytotoxic envenoming, administration of polyvalent antivenom will not reverse but may limit further tissue



Fig. 31. Horned adder (*Bitis caudalis*). Average length 22 - 26 cm. Colour variable. Bluish-grey with two series of dark brown blotches over the back and sides in the northern areas. Olive brown with darker blotches in the central Cape. Reddish in Namibia. Belly always white. (Photo: John Visser.)

damage. However, in boomslang bite the haemostatic effects are rapidly reversed by boomslang antivenom at any time after the bite.

Treatment of antivenom reactions

Early serious reactions may begin 3 - 60 minutes after starting intravenous administration. Adrenaline (epinephrine) 0.1% (1:1 000) should be given intramuscularly in a dose of 0.5 - 1.0 ml for adults and 0.01 mg/kg for children. This should be followed by a slow intravenous injection of an H₁ antagonist (antihistamine) such as promethazine at a dose of 25 - 50 mg in adults. It is contraindicated in children <2 years of age. In children 5 - 10 years old the dose of promethazine is 6.25 - 12.5 mg and in children 10 - 16 years of age 12.5 - 25 mg (or 0.125 - 0.5 mg/kg).

Late (serum sickness type) reactions occur 5 - 24 (average 7) days after treatment. It presents with itching, urticaria, fever, arthralgia, peri-articular swellings, proteinuria and sometimes neurological symptoms. Antihistamines are used for milder attacks, but in severe cases a short course of prednisolone should be given.

Ancillary treatment

Although most local effects of snakebite are attributable directly to cytolytic and other activities of the venom itself, the bite may introduce pathogenic bacteria. The risk of local infections greatly increases if the wound has been incised with an unsterile instrument or tampered with in some other way. The wound should be cleaned with an antiseptic. Blisters and tense bullae should be aspirated only if rupture seems imminent. Snake-bitten limbs should be nursed in the most comfortable position but should not be elevated excessively if there is tense swelling or suspicion of incipient intracompartmental syndrome, as this increases the risk of ischaemia. Debrided tissue, serosanguinous discharge and pus should be cultured and the patient treated with appropriate antimicrobials.

Expert surgical advice should be sought where applicable.

Snake bite

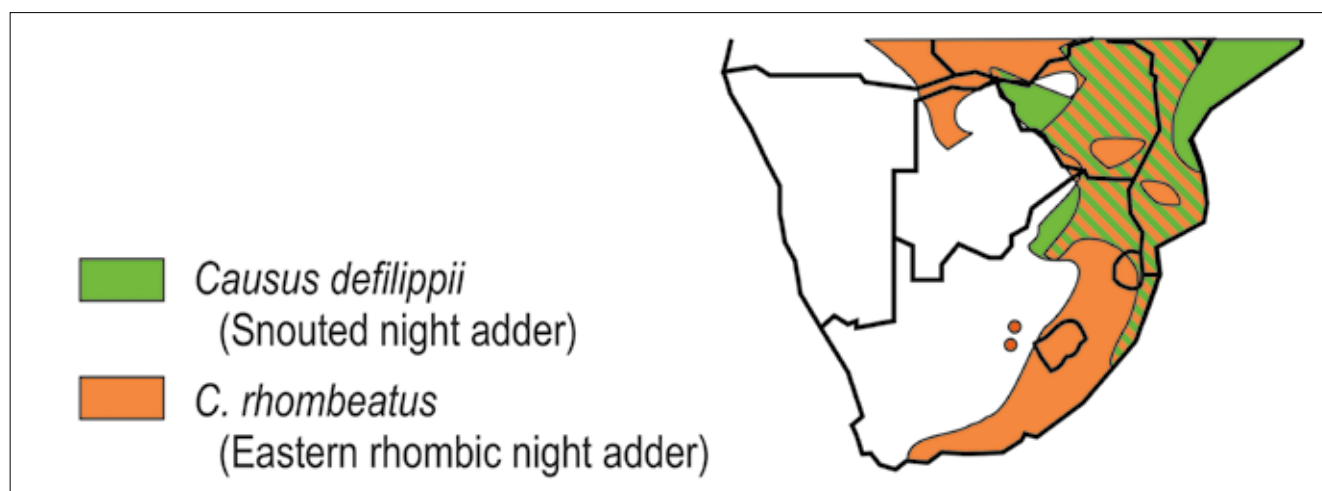


Fig. 32. Distribution of the night adders.

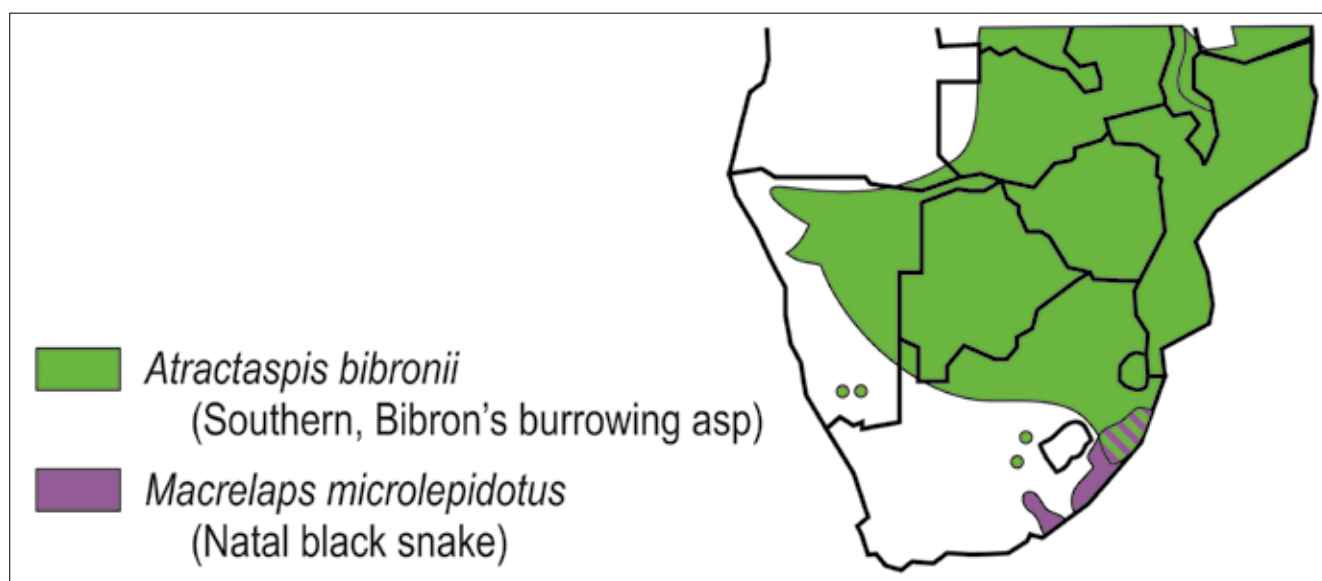


Fig. 33. Distribution of the burrowing asp and the Natal black snake.

Compartmental syndromes

These are uncommon and over-diagnosed but require urgent attention. The clinical appearance of snake-bitten limbs often suggests that there is a compartmental syndrome. There may be severe pain, tense swelling, cold cyanosed skin, pain on passive stretching of the muscles and apparently absent pulses. However, these appearances are usually misleading. When the intracompartmental (tissue) pressure is measured directly (e.g. with a Stryker monitor) pressures are usually found to be below the threshold of danger for ischaemic necrosis of the intracompartmental muscles. Should conservative treatment fail, full-length fasciotomy should be performed, providing there is no coagulopathy or gross thrombocytopenia. It should be mentioned that animal studies have shown that fasciotomy is ineffective in saving envenomed muscles. Provided that adequate antivenom treatment is given as soon as possible after the bite, fasciotomy is rarely if ever needed.

Necrotic tissue should be debrided by a surgeon. Skin grafts may be necessary.

Haemostatic abnormalities

Recovery of normal haemostatic function may be accelerated by giving fresh whole blood, fresh frozen plasma, cryoprecipitates or platelet concentrates.

NB: Heparin and antifibrinolytic agents should never be used in snake bite patients. Heparin does not inhibit the abnormal thrombin generated by snake venoms and it exaggerates, sometimes fatally, the haemostatic disturbances.

Acute renal failure may be caused by haemorrhage, ischaemia resulting from hypotension, effects of blood clotting abnormalities, renal vasoconstriction, pigment nephropathy caused by haemoglobinuria

or myoglobinuria, direct nephrotoxicity and immune complex glomerulonephritis caused by serum sickness reactions to antivenom. If the urine output falls below 400 ml in 24 hours, central venous pressure should be monitored and a urethral catheter inserted. Cautious rehydration with isotonic fluids can be followed by a high dose of furosemide. If these measures fail, dialysis may be indicated.

Anticholinesterase therapy as an option for neurotoxic cobra bite

Neuromuscular blockade by post-synaptic neurotoxins (e.g. neurotoxic cobra venom) may be partly overcome by the use of anticholinesterase drugs. Although anticholinesterase may assist in management, this should not replace antivenom therapy and should also not take priority over respiratory support. It may be of particular benefit to patients allergic to antivenom. Anticholinesterase therapy is, however, not recommended in bites by snakes with presynaptic acting neurotoxins, such as mamba or neurotoxic adders. A test dose of edrophonium to assess whether anticholinesterase therapy may be of benefit is generally recommended. However, edrophonium is not available in South Africa. Neostigmine is therefore used throughout.

The administration of anticholinesterases requires the co-administration of an anticholinergic drug to block potentially serious muscarinic effects, such as bradycardia, bronchospasm and an increase in secretions. Two anticholinergic drugs are available for this purpose, namely, atropine and glycopyrrolate. Glycopyrrolate is the preferred anticholinergic. It gained popularity because it produces less tachycardia than atropine, it is a much more potent antisialagogue and does not cross the blood-brain barrier. It should be noted that reversal of blockade is difficult with concomitant respiratory acidosis. Hypoventilation has to be addressed to decrease the PaCO₂ before neostigmine and glycopyrrolate will be optimally effective.

The recommended average dosing regimen for the reversal of non-depolarising neuromuscular blockade in adults is neostigmine 2.5 mg and glycopyrrolate 0.6 mg (or atropine 1 mg) given together as a bolus. The same dosage regimen is recommended to overcome snake bite-induced postsynaptic blockade. It is generally recommended that the dose of glycopyrrolate (Robinul®) be 0.2 mg (1 ml) for each 1.0 mg of neostigmine. In children the dosage schedule of neostigmine for the reversal of non-depolarising neuromuscular blockade is 0.03 - 0.07 mg/kg, maximum 2.5 mg). The average dose of glycopyrrolate with neostigmine is 0.010 - 0.015 mg/kg. (The recommended dose of atropine with neostigmine in children is 0.02 - 0.03 mg/kg.) Patients who respond convincingly by demonstrating increased muscle strength and/or improvement of ptosis can be maintained on neostigmine 0.5 - 2.5 mg every 1 - 3 hours intravenously up to 10 mg per 24 hours for adults or 0.01 - 0.04 mg/kg every 2 - 4 hours for children. Again, the dose of glycopyrrolate should be 0.2 mg (1ml) for each 1.0 mg of neostigmine.

Snake venom ophthalmia

Snake venom ophthalmia is caused when venom is spat into the eyes. The spitting elapid species in southern African (*Naja mossambica*, *N.*

nigricollis, *N. nigricincta* and *Hemachatus haemachatus*) can cause intense conjunctivitis and bullous corneal erosions, complicated by secondary infection, anterior uveitis, corneal opacities and permanent blindness.

First aid treatment consists of irrigating the eye or other affected mucous membrane as soon as possible, using large volumes of water or any other available bland fluid such as milk. A single application of local anaesthetic eye drops to overcome tightly closed eyelids (blepharospasm) may be used to facilitate irrigation. Topical or systemic antivenom treatment should not be applied or given. Corneal abrasions can be excluded by fluorescein staining/slit lamp examination. If there are no abrasions, treat with antibiotic eye ointment and an eye pad. Resolution should occur within 24 - 48 hours. If corneal erosions are present, antibiotic eye drops/ointment, mydriatics and an eye pad should be applied. Daily slit lamp examinations are recommended until resolved. An ophthalmologist should be consulted in all cases.

Further reading available at www.cmej.org.za

IN A NUTSHELL

- Five main clinical syndromes of snake envenoming are recognised in southern Africa:
 - marked local pain and progressive swelling associated with prominent cytotoxic skin changes with coagulable blood
 - progressive neurotoxicity (paralysis), with negligible or minor local swelling
 - incoagulable blood, with negligible to mild local swelling
 - moderate to marked local swelling associated with neurotoxicity
 - mild to moderate swelling with negligible or absent systemic symptoms.
- Neurotoxic snakes can cause life-threatening paralysis and death within 1 - 8 hours. Respiratory failure is usually the primary cause of death.
- Polyvalent antivenom is available for the management of mamba, neurotoxic cobra, spitting cobra and major adder bites. Monovalent antivenom is used in the management of boomslang bite.
- Since snakes inject the same amount of venom into adults and children, the same dose/volume of antivenom must be administered to children as in adults.
- The administration of polyvalent antivenom in the acute phase of neurotoxic snake envenoming will usually not prevent progression of neurotoxic effects, most notably respiratory paralysis, and consequently the patient will not survive without life support.
- Respiratory support is the only life-saving treatment modality in neurotoxic snake envenoming.
- Administration of antivenom may be associated with acute life-threatening anaphylactoid reactions.

Snake bite

Table 1. Venomous snakes of southern Africa: classification, distribution, habitat and clinical toxinology

Family and species	Common name	Distribution (see figures)	Clinical toxinology
Atractaspididae (Genus <i>Atractaspis</i>)	African burrowing adders or asps (burrowing or mole vipers or adders, side stabbing or stiletto snakes), Natal black snake	Approximately 15 species distributed throughout sub-Saharan Africa	Most cause local pain, swelling and lymphadenitis only; blistering, local necrosis described; life-threatening and fatal cases have been recorded
	The burrowing asps are fossorial, living mostly underground in deserted termite mounds, under stones or logs, or in soft soil or sand. They are mostly grey, black or brown and most are relatively small (30 - 70 cm). They are nocturnal and usually emerge on warm, wet summer evenings, especially after heavy rains. When the snake bites (strikes) the fangs are exposed out of the sides of the mouth and are then hooked or jabbed into the victim with a backward jerk of the head. They are extremely irritable, striking in sideways swings and sweeps, and showing annoyance by flattening the body. Accidental bites usually occur at night when the victim treads on the snake.		
<i>Atractaspis bibronii</i>	Southern, Bibron's burrowing asp	Semi-desert, savanna and woodland of southern Africa, from Kenya through to eastern Tanzania, Malawi, Zambia, Zimbabwe, Botswana, eastern parts of South Africa	Local pain, swelling, lymphadenitis, necrosis
<i>Macrelaps microlepidotus</i>	Natal black snake	East coast of South Africa: riverine forest and urban gardens	Local pain, swelling; serious cases recorded
Colubridae	Common snakes or rear-fanged snakes	Wide distribution throughout Africa	Venom of some capable of inducing fatal haemostatic defects
	The back-fanged snakes have fixed, grooved rear fangs that are situated quite far back in the mouth. Although only the boomslang and the vine snakes have caused fatal bites, all back-fanged colubrids should be regarded as potentially dangerous to man and must be handled with caution.		
<i>Dispholidus typus</i>	Boomslang ('tree snake')	Wide distribution throughout sub-Saharan open bushveld and savanna	Venom contains enzymes which activate prothrombin and factor X, leading to a consumptive coagulopathy, severe hypofibrinogenaemia and fatal bleeding if untreated
<i>Thelotornis capensis capensis</i>	South-eastern savanna vine snake	Trees and shrubs in lowland forest to moist savanna and arid savanna: south-western Zimbabwe and south-eastern Botswana, south through northern South Africa and Swaziland to southern Mozambique and KwaZulu-Natal	Same as for boomslang (see above)
<i>Thelotornis capensis oatesi</i>	Oates' savanna vine snake	Trees and shrubs in lowland forest to moist savanna and arid savanna: southern Angola and northern Namibia, west through northern Botswana, Zambia and south-east Katanga to Zimbabwe, western Mozambique and Malawi	Same as for boomslang (see above); no cases recorded
Elapidae	The majority of elapids are long and slender. The rinkhals and the cobras are easily identified, since they usually rear their heads and spread a hood. Some have the ability to spit venom. There is a relatively high incidence of serious spitting cobra bites in Africa. The black mamba may also spread a narrow hood when threatened. Compared with vipers, elapids possess relatively short (up to about 10 mm long) fixed front (proteroglyphous) fangs. In the case of mambas, the fangs are mounted at the very front of the maxilla, and can rotate at their articulation with the pre-frontal bone.		
	Cobras, rinkhals, mambas, coral, shield, nose, garter and sea snakes	Wide distribution throughout Africa	Potently neurotoxic and cytotoxic; common cause of fatal snake bite

Snake bite

Family and species	Common name	Distribution (see figures)	Clinical toxicology
Neurotoxic cobras (genus <i>Naja</i>)			
<i>Naja anchietae</i>	Anchietia's Egyptian cobra	Arid savanna: Namibia, Angola, north-western Botswana, south-west Zambia	Potently neurotoxic; see below as for <i>N. nivea</i>
<i>Naja annulifera</i>	Banded cobra	Arid and moist savanna: northern South Africa, eastern Botswana and Zimbabwe	Potently neurotoxic; see below as for <i>N. nivea</i>
<i>Naja melanoleuca</i>	Forest, black and white-lipped cobra	Forrested areas of West and Central Africa, southern East Africa and eastern coast of South Africa	Potently neurotoxic; see below as for <i>N. nivea</i>
<i>Naja nivea</i>	Cape cobra	Karoo scrub, arid savanna, Namib desert: western part of South Africa, southern Namibia and Botswana	Potently neurotoxic, causing flaccid paralysis and respiratory failure; fatalities common due to respiratory arrest
Spitting or cytotoxic cobras (genus <i>Naja</i>)			
<i>Naja mossambica</i>	Mozambique spitting cobra, M'fesi	Moist savanna and lowland forest: south-east Africa, from Pemba to northern South Africa and Namibia	Potently cytotoxic; spits and bites; severe local pain, swelling, tissue necrosis, often extensive; eye envenoming
<i>Naja nigricollis</i> : species under review			
<i>Naja nigricollis nigricollis</i>	Black-necked spitting cobra	Savanna, from West Africa to southern Sudan and southwards, through West Africa to Angola	Potently cytotoxic; spits and bites; as in <i>N. mossambica</i>
<i>Naja nigricincta</i>	Barred, zebra spitting cobra	Namib desert and Karoo scrub: southern coastal Angola and northern Namibia	Potently cytotoxic; spits and bites; as in <i>N. mossambica</i>
<i>Naja nigricincta woodi</i>	Black spitting cobra	Dry savanna: southern Namibia, Northern Cape and down to Western Cape Province of South Africa	Potently cytotoxic; spits and bites; as in <i>N. mossambica</i>
Coral/shield-nose snakes (genus <i>Aspidelaps</i>)			
Relatively small, robust elapids easily recognised by the much enlarged, shield-like rostral scale on the snout. 60 - 80 cm in size. A relatively thick-bodied elapid coloured black and orange or greyish with blackish bands. It rears up, spreads a narrow hood and hisses in defence.			
<i>Aspidelaps lubricus</i> . Three coral snake sub-species recognised: <i>Aspidelaps lubricus lubricus</i> (southern race), <i>Aspidelaps lubricus infuscatus</i> (central race) and <i>Aspidelaps lubricus cowlesi</i> (northern race)		Desert and arid savanna: south-western South Africa, through Namibia to southern Angola	Local pain, swelling, lymphangitis; mildly neurotoxic; bites not well documented
<i>Aspidelaps scutatus</i> . Three shield-nose snake subspecies (races) recognised: <i>Aspidelaps scutatus scutatus</i> (western race), <i>Aspidelaps scutatus fulafula</i> (eastern race) and <i>Aspidelaps scutatus intermedius</i> (central race)		Sandy and stony regions in Namib desert, moist and arid savanna, across northern regions of southern Africa, from Namibia across to Mozambique	Details contradictory; local pain, swelling and lymphangitis in some of the bites; neurotoxic in others, with one fatality
Mambas (genus <i>Dendroaspis</i>)			
Large, agile, slender diurnal elapid snakes with a long flat-sided head, a medium-sized eye and a round pupil. Scales are smooth and narrow. All except the black mamba (<i>Dendroaspis polylepis</i>) are arboreal. Colouration varies from light green to olive brown and dark grey. 1.5 - 3.5 m in size. Coffin-shaped head. The black mamba may spread a narrow hood.			

Snake bite

Family and species	Common name	Distribution (see figures)	Clinical toxicology
<i>Dendroaspis angusticeps</i>	Common, eastern green, white-mouthed mamba	Forests or bush on eastern coast of Africa, from Kenya to South Africa	Local pain, swelling, lymphangitis, peripheral gangrene; mildly neurotoxic; one fatal case
<i>Dendroaspis polylepis</i>	Black mamba	Savanna of eastern and southern Africa	Potently neurotoxic; nausea, vomiting, sweating, involuntary muscle contractions or fasciculations; respiratory paralysis may develop within 1 - 2 hours; cardiac dysrhythmias have been described; high incidence of fatal cases
Garter snakes (genus <i>Elapsoidea</i>)	Small fossorial, nocturnal elapid snakes, with very short tails, cylindrical bodies, with no distinct neck and a bluntly rounded rostral scale as in other burrowing species. Most have an average length of 25 - 50 cm. The young are brightly banded (except for one species), the bands fading as they grow. Sluggish when exposed and do not bite if handled gently.		
Taxonomy under revision; several subspecies			
<i>Elapsoidea semiannulata</i>	Angolan or half-banded garter snake	Savanna: Senegal to northern Uganda and a separate southern population from Angola to Mozambique	Local pain, swelling and lymphangitis
<i>Elapsoidea sundevallii</i>	Sundevall's garter snake	Karoo scrub to arid savanna, moist savanna, grassland and lowland forest: southern Africa	Local pain, swelling and lymphangitis; neurotoxic?
Other Elapidae			
<i>Hemachatus haemachatus</i>	Rinkhals	Wide variety of habitats; grassland, moist savanna, lowland forest: eastern regions of South Africa; isolated population in south-western Zimbabwe	Bites and spits; local swelling and bruising. Mildly neurotoxic?
<i>Pelamis platurus</i>	Pelagic, yellow-bellied sea snake	East coast of Africa, from Djibouti to Cape Town	Neurotoxic and myotoxic; myoglobinuria; bites are rare
Viperidae	Adders and vipers	Approximately 45 species distributed throughout Africa	Cytotoxic, haemostatic disorders, neurotoxic; common cause of life-threatening and fatal snake bite in Africa
Vipers or adders are relatively thick bodied, sluggish, mainly terrestrial snakes which have long, curved, cannulated and fully erectile fangs which fold down against the upper jaw in a mucous membrane sheath when the snake is not striking.			
Large adders (genus <i>Bitis</i>)	Wide head and narrow neck. The tail appears oddly short in females and only less so in males. The four larger species have a total length of 80 cm - 2 m. The puff adder is the most widespread and unmistakable; body stout and massive; brown or greyish with well-marked chevron markings. Medically, one of the most important snakes in Africa. The small adders of southern Africa have an average length of 20 - 50 cm.		
<i>Bitis arietans arietans</i>	Puff adder	Wide variety of habitat, savanna and open grassland, except in high montane grasslands, true desert and rainforest: widespread throughout sub-Saharan Africa, absent in African rain forests	Potently cytotoxic; severe local pain, extensive swelling and blistering, compartmental syndrome, necrosis, hypovolaemia, shock; blood coagulation abnormalities
<i>Bitis gabonica</i>	Gaboon adder or viper, forest puff adder	Tropical forests of West, Central and East Africa, and eastern parts of southern Africa	Local effects as above; cardiovascular and haemostatic abnormalities may develop

Snake bite

Family and species	Common name	Distribution (see figures)	Clinical toxicology
Small (dwarf) adders (genus <i>Bitis</i>)			
<i>Bitis atropos</i>	Berg adder	Montane fynbos and grasslands: mountains of eastern Zimbabwe, Drakensberg mountains down to mountains of south-western Cape	Cytotoxic and neurotoxic; local pain, swelling and lymphangitis, ophthalmoplegia, anosmia, hyponatraemia, life-threatening respiratory depression in some cases
<i>Bitis caudalis</i>	Horned adder	Arid savanna and desert: arid regions of south-west Africa, extending eastwards through Botswana to northern South Africa and southern Zimbabwe	Local pain and swelling (this may be extensive with necrosis) lymphangitis
<i>Bitis peringueyi</i>	Peringuey's adder, side-winding adder	Namib desert, Namibia	Local pain, swelling and lymphangitis; ophthalmoplegia and other minor neurotoxic effects observed
<i>Bitis schneideri</i>	Namaqua dwarf adder, Schneider's adder	Vegetated coastal sand: coastal regions of southern Namibia and northern Cape Province	Local pain, swelling and lymphangitis
<i>Bitis xeropaga</i>	Desert mountain adder	Sparsely vegetated rocky hillsides and mountain slopes: southern Namibia and adjacent small area across Orange River into South Africa	Local pain and swelling; ophthalmoplegia and other minor neurotoxic effects observed; hyponatraemia
<p>Other small adders (vipers) considered venomous, but for which no bites have been recorded: <i>Bitis albanica</i> (Albany adder): isolated population in the Algoa Bay region, eastern Cape, South Africa; <i>Bitis armata</i> (Southern adder): two isolated populations on the coast of the Western Cape, South Africa; <i>Bitis cornuta</i> (many-horned adder, hornsman): coastal regions of south-western and western South Africa to southern Namibia, <i>Bitis heraldica</i> (Angolan adder): high parts of central Angola; <i>Bitis inornata</i> (plain mountain adder): isolated populations in the Graaff Reinet region of the Eastern Cape, South Africa; <i>Bitis rubida</i> (red adder): southern to south-western part of South Africa: Cederberg, through Little Karoo and foothills of the Roggeveld and Komsberg.</p>			
Night adders (genus <i>Causus</i>)	The night adders are small (<1 meter) and despite their name they are active by day and by night. They are not adder-like, and are fairly stout with the head being only slightly distinct from the neck. The venom fangs are short with no hinge action compared with the genus <i>Bitis</i> . They have round pupils (most adders have vertical eye pupils) and they have large scales on top of the head (most vipers have small scales). They are not given to standing their ground, but when angry, they hiss and puff ferociously, inflating the body to great extent. They may also raise the forepart of the body off the ground and slide forward with the neck flattened, looking quite cobra-like.		
<i>Causus defilippii</i>	Snouted night adder	Moist and dry savanna and coastal thicket: eastern Africa, from Kenya and Tanzania, Malawi, Zambia, Zimbabwe and Mozambique to north-eastern South Africa	Local pain, swelling, lymphangitis and local necrosis
<i>Causus rhombeatus</i>	Eastern rhombic night adder	Savanna, from eastern Nigeria, through Central Africa, down to eastern half of South Africa	Local pain, swelling, lymphangitis and local necrosis

Snake bite

Further reading

- Ashe S, Blaylock R, Chisale MGP, et al. Guidelines for the Prevention and Clinical Management of Snakebite in Africa. World Health Organization, Regional Office for Africa, Brazzaville, 2010.
- Blaylock RSM. Snake bites at Triangle Hospital January 1975 to June 1981. *Cent Afr J Med* 1982;28:1-11.
- Blaylock R.S.M. Femoral vessel entrapment and compartment syndromes following snakebite. *S Afr J Surg* 2003;41(3):72-73.
- Blaylock R. Epidemiology of snakebite in Eshowe, KwaZulu-Natal, South Africa. *Toxicon* 2004;43(2):159-166.
- Blaylock RS, Lichtman AR, Potgieter PD. Clinical manifestations of Cape cobra (*Naja nivea*) bites. Two cases. *S Afr Med J* 1985;68(5):342-344.
- Broadley DG, Wüster W. A review of the southern African 'non-spitting' cobras (Serpentes: Elapidae: *Naja*). *Afr J Herpetology* 2004;53:101-122.
- Bush SP. Snakebite suction devices don't remove venom: they just suck. *Ann Emerg Med* 2004;43(2):187-188.
- Coetzer PWW, Tilbury CR. The epidemiology of snakebite in Northern Natal. *S Afr Med J* 1982;62:206-212.
- Davidson RA. Case of African Cobra bite. *Brit Med J* 1970;4:660.
- Hardy DL. A review of first aid measures for pit viper bite in North America with an appraisal of Extractor™ suction and stun gun electroshock. In Campbell JA, Brodie ED, eds. *Biology of the Pit Vipers*. Tyler, Texas, Selva 1992:405-414.
- Harvey AL. Snake Toxins. *International Encyclopedia of Pharmacology and Therapeutics*. New York: Pergamon Press, 1991.
- Kasilo OMJ, Nhachi CFB. A retrospective study of poisoning due to snake venom in Zimbabwe. *Hum Exp Tox* 1993;12:15-18.
- Lath NK, Patel MM. Treatment of snake venom ophthalmia. *Centr Afr J Med* 1984;30(9):175-176.
- Khandelwal G, Katz KD, Brooks DE, Gonzalez SM, Ulishney CD. *Naja Kaouthia*: two cases of Asiatic cobra envenomations. *J Emerg Med* 2007;32(2):171-174.
- Malasit P, Warrell DA, Chanthavanich P, et al. Prediction, prevention and mechanism of early (anaphylactic) antivenom reactions in victims of snake bites. *BMJ* 1986;292:17-20.
- Marsh NA, Whaler BC. The Gaboon viper (*Bitis gabonica*): its biology, venom components and toxinology. *Toxicon* 1984;22(5): 669-694.
- McNally T, Conway GS, Jackson L, et al. Accidental envenoming by a Gaboon viper (*Bitis gabonica*): the haemostatic disturbances observed and investigation of in vitro haemostatic properties of whole venom. *Trans Roy Soc Trop Med Hyg* 1993;87:66-70.
- Meier J, White J. *Handbook of Clinical Toxicology of Animal Venoms and Poisons*. CRC Press, 1995.
- Näreoja K, Kukkonen JP, Rondinelli S, Toivola DM, Meroluoto J, Näsman J. Adrenoceptor activity of muscarinic toxins identified from mamba venoms. *Br J Pharmacol* 2001;164:538-550.
- Punde DP. Management of snake-bite in rural Maharashtra: a 10-year experience. *Nat Med J India* 2005;18(2):71-75.
- Sano-Martins IS, Fan HW, Castro SC et al. Reliability of the simple 20 minute whole blood clotting test (WBCT20) as an indicator of low plasma fibrinogen concentration in patients envenomed by Bothrops snakes. *Toxicon* 1994;32:1045-1050.
- Singh G, Pannu HS, Chawla PS, Malhotra S. Neuromuscular transmission failure due to common krait (*Bungarus caeruleus*) envenomation. *Muscle & Nerve* 1999;22(12):1637-1643.
- Spawls S, Branch B: *The Dangerous Snakes of Africa*. London: Southern Book Publishers, 1995.
- Strover HM. Observations on two cases of snake bite by *Naja nigricollis* mossambica. *Cent Afr J Med* 1973;19(1):12-13.
- Sutherland SK, Coulter AR, Harris RD. Rationalisation of first-aid measures for elapid snake bite. *Lancet* 1979;1:183-186.
- Warrell DA, Ormerod LD. Snake venom ophthalmia and blindness caused by the spitting cobra (*Naja nigricollis*) in Nigeria. *Am J Trop Med Hyg* 1976;25:525-529.
- Warrell DA, Ormerod LD, Davidson NMCD. Bites by the puff adder (*Bitis arietans*) in Nigeria, and value of antivenom. *Br Med J* 1975;4:697-700.
- Warrell DA, Ormerod LD, Davidson NMCD. Bites by the night adder (*Causus maculatus*) and burrowing vipers (genus *Atractaspis*) in Nigeria. *Am J Trop Med Hyg* 1976;25:517-524.
- Wilkinson D. Retrospective analysis of snakebite at a rural hospital in Zululand. *S Afr Med J* 1994;84(12):844-847.