

## Case reports

### Thymoma-associated myasthenia gravis

A 25-year-old HIV-negative woman presented to our hospital with a 6-week history of progressive generalised muscle weakness. Her main complaints were limb weakness, blurred vision, difficulty in swallowing and a change in her voice. She was previously healthy and had a normal vaginal delivery 5 months previously. She had no family history of any neuromuscular disease.

On neurological examination she had bilateral ptosis, bilateral asymmetrical facial weakness (with involvement of the forehead) and generalised proximal muscle weakness which was characterised by fatigability. Her reflexes were generally brisk, but her tone, sensation and co-ordination were normal and her plantar responses were downgoing. Her swallowing was impaired and she had a hypophonic dysarthria. The rest of the physical examination was unremarkable.

On examination the following morning, most of her muscle weakness had resolved and she was able to swallow her breakfast with ease. However, later on during the day her ptosis, dysphasia and limb weakness became evident again.

Her serum thyroid-stimulating hormone (TSH), calcium, magnesium, phosphate and creatinine kinase were normal. Her forced vital capacity was 2 litres. A chest X-ray showed an anterior mediastinal mass with calcification (Fig. 1) and on computed tomography (CT) scan this mass was assessed as most likely being a thymoma.

Neostigmine and ice-pack tests were performed and each confirmed a diagnosis of myasthenia gravis (MG). She was started on oral pyridostigmine 60 mg 6-hourly and prednisone 20 mg daily. She responded well to treatment and had a thymectomy 2 months after presentation.

### Discussion

MG is a construct of the Greek words *myo* (muscle) + *asthenia* (weakness) and a Latin adjective *gravis* (severe). It is an uncommon autoimmune syndrome caused by failure of the neuromuscular junction as a result of formation of antibodies against acetylcholine nicotinic postsynaptic receptors. MG has an incidence of 10 - 20 new cases per million persons per year and a prevalence rate of 200 - 400 cases per million persons.<sup>1</sup> The incidence is the same in the Cape Town metropolis as the rest of

the world.<sup>2</sup> It has a bimodal distribution with an early peak of the disease in the 2nd and 3rd decades with female predominance and a late peak in the 6th and 8th decades with male predominance.

MG may affect the ocular muscles alone or cause a generalised muscle weakness. Fluctuating fatigable skeletal muscle weakness is usually diagnostic of MG. Pain and wasting are typically absent. The reflexes are preserved and usually brisk but may be fatigable. The asymmetry of skeletal muscle weakness and brisk reflexes might cause the diagnosis to be confused with that of motor neuron disease. However, bilateral ptosis in a young female patient should always make MG a priority diagnosis.

A thymoma is found in 10% of patients with MG and 99% of these patients will be seropositive. Thymoma-associated MG is generally a severe disease whose current good prognosis depends mainly on immunosuppressive therapy. A thymoma is an obvious indication for surgery because there may be an underlying malignancy. Although thymectomy improves the prognosis for thymoma it does not significantly improve the course of MG.<sup>3</sup>

The common diagnostic test is using the anticholinesterase edrophonium (tensilon test) or neostigmine for reversal of muscle weakness. Other simple tests that are cheap are the ice-pack test and sleep test for reversal of ptosis. Criteria for these tests are poorly defined. Serum assays for anticholinesterase antibodies may be positive in approximately 80 - 90% of patients with generalised MG and 30 - 50% of patients with ocular MG. Repetitive stimulation of peripheral nerves with electromyography (EMG) may also demonstrate progressively diminished action potentials or fatigability in up to 90% of cases of generalised MG.<sup>1</sup>

### Management

Management of MG ranges from symptomatic treatment with oral anticholinesterases to chronic immunomodulating drugs

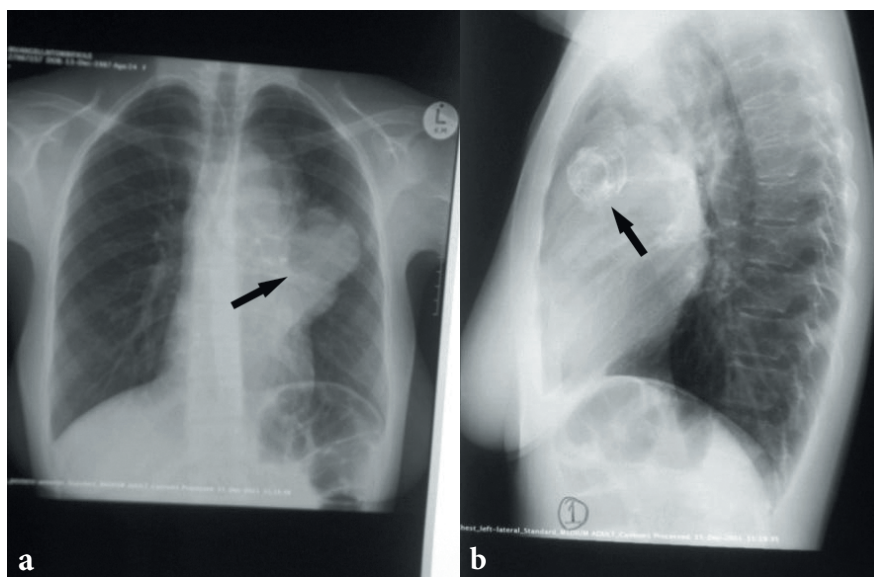


Fig. 1. Chest X-ray: a. postero-anterior view; b. lateral view.

## Case reports

for patients who remain symptomatic on anticholinesterases.<sup>4,5</sup>

### Lindisa Mbuli, MB ChB, DOH

Registrar, Department of Medicine, New Somerset Hospital, Cape Town

### Muhammed S Moosa, MB ChB, FCP

Consultant, Department of Medicine, New Somerset Hospital, Cape Town

Correspondence to: M S Moosa (shiraz.moosa@gmail.com)

### Acute coronary syndrome due to coronary vasospasm associated with thyrotoxicosis

The cardiovascular manifestations of hyperthyroidism are well known.<sup>1,2</sup> It is less well recognised that angina may be due to coronary spasm caused by hyperthyroidism in a small subset of patients.<sup>1</sup>

I report on a patient who presented with angina and hyperthyroidism in whom repeated coronary angiography revealed coronary vasospasm. The suggested mechanism of the coronary vasospasm is thyrotoxicosis due to Graves' disease.

#### Case report

A 37-year-old mother of two was referred with a 1-day history of severe ischaemic-type chest pain occurring at rest and associated autonomic symptoms of nausea, vomiting and excessive sweating. This pain was preceded by a 1-month history of intermittent chest pain. She had a background of diabetes mellitus and untreated hypertension. She also had a significant smoking history of 15 pack-years. On examination her blood pressure was 189/109 mmHg and her heart rate was 96 beats/min. Her systemic examination was unremarkable. A resting electrocardiogram (ECG) revealed sinus tachycardia with a rate of 126 beats/min, normal QRS axis, widespread ST-segment depression in the limb and precordial leads, with ST-segment elevation in the augmented unipolar limb lead (right arm) – aVR. At that time a transient run of atrial fibrillation was noted on the cardiac monitor and, on direct questioning, the patient reported having palpitations, heat

intolerance, emotional lability and weight loss of 20 kg in the preceding six months. Laboratory testing showed: troponin-T 0.42 (normal <0.03), thyroid-stimulating hormone (TSH) <0.01, and thyroxine (T4) >100. The haemoglobin was normal and her pregnancy test was negative. She was assessed as having thyrotoxicosis with non-ST-segment elevation myocardial infarction (NSTEMI) and was treated with an infusion of unfractionated heparin, aspirin, simvastatin, atenolol, Lugol's iodine, carbimazole and cholestyramine. The pain resolved on this treatment. Several hours later the pain recurred and therefore coronary angiography was done. This demonstrated severe stenosis of the left main stem. A decision to perform emergency coronary artery bypass graft surgery was made. However, the possibility of coronary vasospasm was strongly considered and consequently surgery was cancelled. It was decided that the treatment of thyrotoxicosis be continued, with angiography repeated later. She was subsequently diagnosed with Graves' disease.

With treatment of hyperthyroidism the symptoms resolved and her T4 levels fell. On day 9 coronary angiography was repeated; severe left main stem stenosis was still present. She was euthyroid at that stage. The beta-blocker was stopped and nitrates and dihydropyridine calcium-channel blockers were added to the treatment regimen. Angiography was done again on day 12, with a marked improvement in the calibre of the vessel. Subsequent ECGs revealed resolution of the initial changes and the patient remained pain free at discharge on day 18. She has been followed up closely in the cardiac clinic and had a normal exercise ECG. She remains euthyroid and symptom free.

#### Discussion

This report highlights a case of thyrotoxicosis due to Graves' disease causing coronary vasospasm and NSTEMI – the first report of its kind in South Africa.

Angina has been found to be associated with thyrotoxicosis in up to 25% of patients in one series.<sup>3</sup> In patients with coronary atheroma, the presence of angina reflects a mismatch between myocardial oxygen

supply and demand due to the increase in cardiac workload and contractility associated with thyrotoxicosis.<sup>1,4</sup> Al Suwaidi *et al.*<sup>5</sup> documented 18 published reports, with a total of 34 patients, of angina pectoris associated with coronary spasm due to thyrotoxicosis, that have been confirmed angiographically since 1979. They found that the cardiac presentation varied from angina and myocardial infarction to ventricular arrhythmias, cardiogenic shock and cardiac arrest. They also noted that in these patients the manifestations of hyperthyroidism were either scarce or absent, which was also noted in the patient presented above.

Choi *et al.*<sup>6</sup> carried out a retrospective analysis of 325 patients presenting with coronary spasm between 1994 and 2000 in Korea. They reported that of these, 8 had hyperthyroidism due to Graves' disease. In three patients, the left main stem coronary artery was involved in the spasm. Among these patients, five were female, and all the female patients were below the age of 51. All of these patients were treated with anti-thyroid medication, calcium-channel blockers, and long-acting nitroglycerines. They remained free of chest pain during the median follow-up period of five years. Resolution of chest pain with anti-thyroid treatment has also been reported by other authors.<sup>5</sup>

The mechanism of coronary vasospasm in hyperthyroidism remains unknown.

#### Conclusion

Hyperthyroidism should be considered in the differential diagnosis of chest pain due to coronary spasm, particularly in young women. Thyroid function tests should be routine in patients presenting with chest pain due to coronary spasm.

### Chishala Chishala, MB ChB

2nd-year Registrar, Department of Medicine, University of Cape Town and Groote Schuur Hospital, Cape Town

Correspondence to: C Chishala (chishala.chishala@gmail.com)

References available at [www.cmej.org.za](http://www.cmej.org.za)