

# HIV and childhood cancer

**HIV infection has had a profound impact on childhood cancer.**

**ALAN DAVIDSON, MB ChB, FCPaed (SA), Cert Medical Oncology (Paeds), MPhil**

**Head, Haematology/Oncology Service, Red Cross War Memorial Children's Hospital, School of Child and Adolescent Health, University of Cape Town**

*Alan Davidson is the outgoing chair of the South African Children's Cancer Study Group. His interests are the development of shared care platforms and locally appropriate treatment protocols. His clinical focus is HIV-related malignancy, brain tumours and bone marrow transplantation. His current research interests are a national study of malignancy in HIV-positive children, studies in supportive care and appropriate guidelines for long-term follow-up.*

**BRIAN ELEY, MB ChB, FCPaed (SA), BSc (Hons)**

**Head, Paediatric Infectious Diseases, Red Cross War Memorial Children's Hospital, and Associate Professor, School of Child and Adolescent Health**

*Brian Eley's interests and clinical focus are HIV infection, TB, and common childhood viral and bacterial infections. Current research interests include outcome of paediatric ART, pharmacokinetics of antiretroviral agents in children co-treated with anti-TB medication, genetic control of mycobacterial infection, and new diagnostic tests for TB.*

*Correspondence to: Alan.Davidson@uct.ac.za*

HIV-related immunosuppression increases the incidence of certain forms of cancer, and HIV infection and its co-morbidities such as TB have made it more difficult to treat incidental malignancies. The HIV-related malignancies (HIVRM) include AIDS-defining cancers and HIV-associated neoplasms. The AIDS-defining cancers are Kaposi's sarcoma (KS) and B-cell lymphomas (including primary CNS lymphoma), all of which are defined as WHO stage IV or CDC category C conditions. The HIV-associated neoplasms include leiomyosarcoma (a rare smooth-muscle tumour defined as CDC category B) and mixed-cellularity Hodgkin's lymphoma (not listed by WHO or CDC). They are all the result of viral transformation of DNA in host cells, by human herpesvirus-8 (HHV8) in the case of Kaposi's sarcoma and by Epstein-Barr virus (EBV) in the others. While these tumours all occur in HIV-negative patients, the incidence of B-cell lymphoma shows a modest increase and the incidence of Kaposi's sarcoma increases tenfold or more in the presence of HIV infection.<sup>1-3</sup> The number of incidental malignancies occurring in HIV-positive children rises as the prevalence of HIV increases in the population. This is a function of both an increase in the number of susceptible individuals and increased survival of this cohort as the number of children on antiretroviral therapy (ART) expands.

## **The HIV-related malignancies (HIVRM) include AIDS-defining cancers and HIV-associated neoplasms.**

The scale of the problem is potentially immense. Whereas northern hemisphere registry data show that about 13 children per 100 000 under the age of 15 develop cancer each year,<sup>4,5</sup> data from the Italian Register for HIV Infection suggest that about 450 per 100 000 ART-naïve HIV-infected children will develop cancer annually.<sup>6</sup> This risk declines to 76 per 100 000 per annum in children on ART,<sup>6</sup> demonstrating the efficacy of ART in preventing malignancy but underscoring the residual potential for malignant transformation.

These risks should be viewed against the current state of the paediatric HIV pandemic. Of 2 100 000 children younger than 15

years living with HIV in 2007, 1 800 000 (85.7%) were residing in sub-Saharan Africa and 280 000 (13.3%) in South Africa. While comprehensive prevention and treatment strategies have reduced and stabilised HIV prevalence in Europe and North America, only 35% of children in sub-Saharan Africa who need ART are receiving treatment.<sup>7,8</sup> In South Africa, according to the mid-2009 population statistics, there were 15 500 700 children aged 0 - 15 years, 280 000 - 320 000 of whom were HIV-infected.<sup>9</sup> At present 94 000 are on ART, an estimated coverage of 61%.<sup>8</sup> Using the published European estimates, we should be seeing at least 1 000 cases of HIVRM per year.<sup>4,6</sup>

A recent study of HIV and childhood malignancy from four of South Africa's nine academic sector-based paediatric oncology units<sup>10</sup> showed only 131 cases of HIV-related malignancy and 48 cases of incidental malignancy since the start of the epidemic. These low figures are probably the result of underdiagnosis and under-reporting, as well as the poor survival of HIV-infected children prior to the ART rollout.

This article will focus on the important tumours and aims to encourage early detection and appropriate decision-making in a general practice or paediatric office setting.

### *Kaposi's sarcoma (KS)*

KS is the result of uncontrolled expression of HHV-8 in endothelial cells usually secondary to immunosuppression. Although KS was already endemic in parts of sub-Saharan Africa, where the seroprevalence of HHV8 in the population often exceeds 50%,<sup>11</sup> the incidence of epidemic (or HIV-associated) KS has risen by as much as tenfold in the wake of the HIV epidemic. This also underscores the potential of ARVs to prevent KS<sup>12</sup> since the incidence is substantially lower in children established on ART.

### **Clinical presentation**

The tumour is a proliferation of spindle cells with extensive vascularisation, resulting in purple or brown macular, plaque-like or nodular lesions on mucocutaneous surfaces. KS may present as discreet indolent skin lesions (Fig. 1), oropallatal or perineal lesions with regional adenopathy, or a lymphadenopathic

form with generalised adenopathy. The lymphadenopathic form is the most common presentation<sup>13</sup> and may be the result of recent HHV8 infection with a rapid progression to malignancy (since the virus is tropic for lymph nodes during seroconversion). It's not clear exactly how often the gastrointestinal tract is involved (it has been reported to be as high as 80% at autopsies<sup>14</sup>) because lesions not visible in the oropalatal region are often clinically silent. When they do present it's usually with gastrointestinal haemorrhage, or rarely with intussusception, obstruction or ascites, and this has led some investigators to advise thallium scans or routine endoscopy for all cases.<sup>3</sup> Occasionally aggressive forms manifest with disseminated disease involving the skin, nodes, various solid viscera and the lungs with isolated pulmonary nodules or pleural effusion.

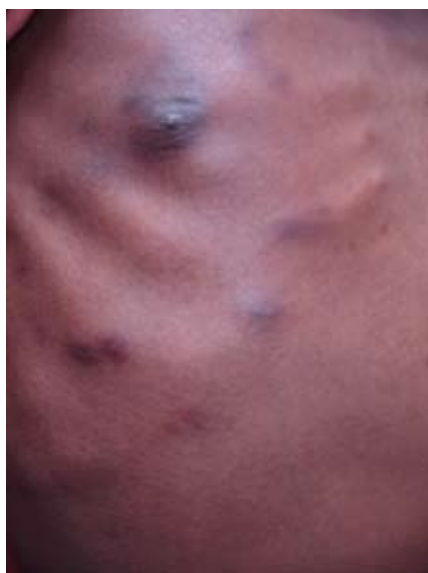

Fig. 1. Typical cutaneous lesions of Kaposi's sarcoma on the chest wall.

### Investigation and management

Appropriate investigations in a suspected case of KS would be a serum lactate dehydrogenase (LDH) which may serve as a tumour marker, together with a chest radiograph (CXR) to rule out pulmonary metastases and an abdominal ultrasound to look for lymph nodes and bowel wall thickening. The diagnosis must be proven on tissue biopsy because several conditions may mimic cutaneous KS including pyogenic granuloma, bacillary angiomatosis and dermatofibromata. The patient should have a baseline full blood count, CD4 count and percentage, and HIV viral load.

Antiretroviral therapy is the mainstay of treatment because the resultant immune restoration may be sufficient to induce remission. ART should be started promptly while the patient is being referred to a

paediatric oncology unit for staging and definitive management. In the absence of disseminated disease, a critical airway or a life-threatening haemorrhage, ART is the preferred first-line strategy in resource-limited settings. A recently published series of 73 children with HIV-associated KS in Uganda included patients treated with ART, chemotherapy or a combination of both. Although analysis of the outcomes was limited by an incomplete dataset, the response rate was better among those treated with ART, regardless of whether they received chemotherapy or not.<sup>13</sup> At Red Cross Children's Hospital we have tended to defer chemotherapy and assess the response to ART, but with a few exceptions most cases have required chemotherapy to achieve a durable remission.<sup>3</sup> Treatment options include infusional therapy with adriamycin, bleomycin and vinblastine (ABV) or oral etoposide. There are no randomised controlled trials in paediatrics, and there is almost no literature concerning the treatment of HIV-associated KS in the developing world. One adult study from Zimbabwe suggested that patients treated with oral etoposide had a better quality of life than patients treated with infusional agents or radiotherapy, but none of these patients received ART and only 2% of the cohort (11 of 470 patients) was still alive at the time of publication.<sup>15</sup>

Considering the central role of HHV-8, a possible role for antiviral agents has been explored. Ganciclovir used to treat cytomegalovirus disease in AIDS patients decreases the risk of KS but does not achieve responses in established disease.<sup>16</sup> This is probably because most cells are latently infected and do not support lytic replication. Valproate may be able to induce lytic replication rendering KS amenable to antiviral therapy<sup>17</sup> and this is being investigated.

### Suspected lymphoma

The increased incidence of high grade B-cell non-Hodgkin's lymphomas (B-NHL) in HIV-infected children is the result of malignant transformation in lymphocytes latently infected with EBV. HIV-induced immunosuppression limits the host's ability to destroy these cells, resulting in unrestricted proliferation.

The commonest B-NHL in HIV-negative children is Burkitt's lymphoma which results in rapidly growing abdominal masses usually arising in mesenteric nodes, with or without involvement of the jaw, the bone marrow or the central nervous system (CNS). Other histological forms of B-NHL may occur in HIV-infected children, most commonly the diffuse large B-cell lymphoma, which is usually more

indolent. In contrast to KS, which occurs in the profoundly immunosuppressed, B-NHLs can occur in HIV-infected children with relatively well-preserved immune systems as measured by CD4 counts.<sup>18</sup> ART does not prevent B-NHLs to the same extent as KS, and a higher incidence of B-NHL will continue to occur in the HIV-infected population.

**The number of incidental malignancies occurring in HIV-positive children rises as the prevalence of HIV increases in the population.**

Primary CNS lymphomas (PCNSL) merit special attention. These tumours are extremely rare in the HIV-negative population but have been reported to make up as much as 20% of AIDS-related lymphomas.<sup>19,20</sup> To date few cases have been reported in South Africa.<sup>10</sup> They are usually cerebral (Fig. 2) and seldom leave the CNS but may spread through the cerebrospinal fluid, resulting in spinal metastases.

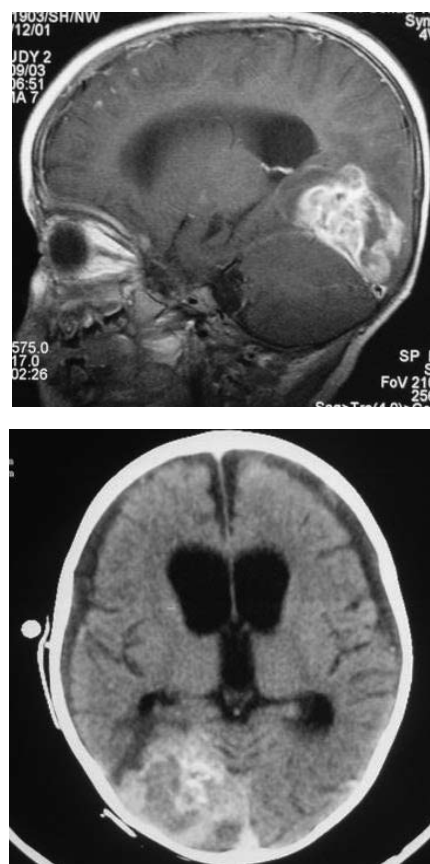


Fig. 2. A primary CNS lymphoma in the right occipital lobe.

## Clinical presentation

While presentation with an abdominal lymph node mass is still the most common, HIV-related B-NHLs are frequently extranodal, occurring in atypical sites<sup>10,21</sup> such as the lungs, the mediastinum and heart, the adrenal gland, the face and sinuses and the bones. They are also more aggressive with more frequent spread to the bone marrow and central nervous system. Any rapidly growing mass in an HIV-infected child should prompt the clinician to consider a lymphoma.

## The scale of the problem is potentially immense.

PCNSL usually present with features of raised intracranial pressure such as persistent headache and vomiting, as well as hemiparesis, seizures, ataxia or other gait disturbances, and neuropsychiatric symptoms.

## Investigation and management

Appropriate first-line investigations include LDH, which is typically elevated in the presence of normal alanine aminotransferase (thus ruling out liver dysfunction), and uric acid. Involvement of the bone marrow may be reflected in an abnormal full blood count; blasts in the peripheral blood are unusual but any combination of anaemia, thrombocytopenia or neutropenia is suspicious. The patient should have a CXR to detect mediastinal or hilar nodes, and an abdominal ultrasound to look for a mass arising from lymph nodes or the bowel wall. The possibility of a B-NHL should prompt immediate referral to a paediatric oncology unit.

Our approach is to prove the diagnosis as soon as possible after admission. If the bone marrow appears involved, a bone marrow biopsy will suffice. If not, a tissue biopsy is obtained, together with a staging bone marrow and CSF cytospin to rule out CNS involvement. We start treatment immediately in the form of chemoreduction with prednisone, vincristine and cyclophosphamide, followed by several courses of multiagent infusional chemotherapy. Considering that the patient is likely to be profoundly myelosuppressed by chemotherapy for several months we believe that there is nothing to gain and everything to lose by delaying the institution of ART in naïve patients. Consequently we start ART as soon as possible after obtaining

a baseline CD4 count, percentage and viral load, and complete the pre-ART initiation counselling during the first 2 weeks of ART. This has raised the concern that circumventing the normal pre-ART counselling process might lead to higher default rates. However, our anecdotal experience and observational data from the national database<sup>10</sup> (only 6 of the 104 (6%) children with malignancy started on ART since rollout have defaulted antiretrovirals) suggests that this approach is acceptable and that regular chemotherapy attendance probably augments adherence.

B-NHLs are exquisitely sensitive to glucocorticosteroids. Avoid giving any patient with suspected B-NHL glucocorticosteroids for any reason until the diagnosis has been established. Not only is there a danger of precipitating tumour lysis, but our ability to make a definitive diagnosis may be jeopardised.

Consideration of the diagnosis of PCNSL is prompted by neuro-imaging in the symptomatic patient. The differential diagnosis is primarily one of infectious entities such as toxoplasmosis, cerebral abscess and progressive multifocal leukoencephalopathy, and the decision to biopsy suspicious lesions requires the combined efforts of an oncologist, a surgeon, an infectious disease specialist and a radiologist. Treatment at a paediatric oncology unit would include steroids, high-dose methotrexate and radiotherapy in older children.

## ART-naïve HIV-positive children with large visceromegaly or lymph nodes

Don't be too quick to biopsy these children because HIV can present with profound lymphoproliferation. If you are concerned about lymphoma check the LDH and the urate. Provided that they are normal, and that you've ruled out tuberculosis (TB), it's quite in order to start ART and watch and wait. If, on the other hand, new lymphoproliferation occurs in a child well established on ART, then you must pursue the diagnosis aggressively. Fine-needle aspiration of enlarged lymph nodes is relatively easy to perform and is appropriate if you suspect TB, but formal excision or incision biopsy is preferable if you suspect lymphoma.

## Pancytopenia

The differential diagnosis of any of the three cytopenias in the HIV-positive child is vast, and goes beyond the scope of this

paper. That said, leukaemia or lymphoma must be strongly considered when an HIV-positive child presents with pancytopenia. The disease may be incidental (acute lymphoblastic or myeloid leukaemia) or HIV-related (a stage IV Burkitt's leukaemia). The peripheral smear should be examined for blasts, and LDH and urate concentrations determined. The causes of pancytopenia include HIV itself, severe bacterial or viral infection, disseminated TB, zidovudine or other drug-related myelosuppression, and immune cytopenias such as Evan's syndrome (immune anaemia and thrombocytopenia). A bone marrow is indicated if leukaemia or disseminated TB is suspected but is not mandatory for pancytopenia; it will be entirely nonspecific if the pancytopenia is infectious in origin or drug-related, and it may not be necessary to prove immune cytopenias.

## HIV-induced immunosuppression limits the host's ability to destroy these cells, resulting in unrestricted proliferation.

## TB, HIV and malignancy

While children on chemotherapy are at higher risk for the development of TB, and TB may masquerade as malignancy (especially lymphomas), it is a truism that HIV-negative children almost never have TB and malignancy diagnosed simultaneously. This is not the case with HIV-infected children. They can and do present with both TB and malignancy, and the definitive diagnosis of one of these diseases does not necessarily exclude the other. We believe that children diagnosed with both TB and malignancy should be started on anti-TB treatment and an appropriate ART regimen as soon as possible. The risk of immune reconstitution aggravating the symptoms of TB is lower in this group and is outweighed by the risk of the TB progressing with consequent delays in chemotherapy administration.

Another important aspect of the complex interplay between TB and malignancy is that abdominal masses should not be treated presumptively as TB in any patient whose tuberculin skin test is unreactive. This merits special emphasis in HIV-infected children; the increased likelihood



of a false negative tuberculin test cannot abrogate the clinician's responsibility to insist on a tissue diagnosis.

### What about incidental malignancy?

The spectrum of disease is similar to that in HIV-negative children. The 48 children reported in the national database<sup>10</sup> include 14 with leukaemias and lymphomas – as one would expect more than half had acute lymphoblastic leukaemia – and 34 with solid tumours – including brain tumours, and embryonal tumours of the kidney, sympathetic nervous system, liver and retina. Notably there were two squamous carcinomas of the rectum secondary to anal warts. While an increase in the incidence of cancers related to human papilloma virus (HPV) has been described in a recent meta-analysis,<sup>22</sup> malignant transformation in HPV-infected lesions has not been fully studied.

## Avoid giving any patient with suspected B-NHL glucocorticosteroids for any reason until the diagnosis has been established.

Considering that the incidence of childhood malignancy is relatively stable over time, it stands to reason that the amount of incidental malignancy is a function of the number of HIV-infected children in the population. The more HIV-infected children there are, the more cases of incidental malignancy we will see in this cohort. Even the small number reported above is unprecedented in the literature, and it underscores the need to test every child diagnosed with malignancy. There are a number of ancillary reasons. HIV immunosuppression may complicate treatment, resulting in increased toxicity and causing interruptions which could compromise outcome. This consideration has prompted us to modify therapy in some cases. In addition there is a legal consideration. Many, if not most, children with malignancy will be exposed to blood products and the small risk of HIV transmission mandates the documentation of HIV status at diagnosis.

The warning signs of malignancy (see article by Stones in this edition, p. 314) apply equally to HIV-positive children, though one must also have a higher index

of suspicion for HIVRM. The differential diagnosis is more extensive than in HIV-negative children including immune dysfunction, HIV infection itself and other opportunistic infections. Discussing each suspected case timeously with a paediatric oncologist is the recipe for success.

### What is the best combination of ARVs?

At Red Cross Children's Hospital our experience is limited to first-line therapy combinations of two nucleoside reverse transcriptase inhibitors (NRTIs) with a non-nucleoside reverse transcriptase inhibitor (NNRTI). The most frequently used combination is lamivudine, stavudine and efavirenz. This combination in association with chemotherapy has resulted in minimal toxicity or drug-drug interactions. Because of its long-term adverse toxicity profile, stavudine will be replaced with abacavir in the near future in the national first-line ART regimen. It is unlikely that this change will influence concomitant administration of chemotherapy agents. We recommend that the use of zidovudine should be restricted because it is myelosuppressive and may exacerbate chemotherapy-induced cytopenias.

In South Africa a protease inhibitor-containing first-line ART regimen is recommended for children less than 3 years of age and those who were previously exposed to perinatal nevirapine. The preferred protease inhibitor in South Africa is the lopinavir/ritonavir co-formulation (Kaletra). Protease inhibitors

may interfere with the hepatic metabolism of certain chemotherapy agents and have been shown to potentiate the myelotoxicity of cyclophosphamide, doxorubicin and etoposide.<sup>24</sup> These effects should be carefully considered when combining protease inhibitors and chemotherapy agents. Although laboratory studies have shown that protease inhibitors exert anti-angiogenic effects, protease inhibitor-containing regimens have not been shown to be superior to NNTRI-containing regimens in the treatment of KS.<sup>25-27</sup>

### Outcomes of HIV-positive children with malignancy

A diagnosis of malignancy in the pre-ART era was almost invariably a death sentence but we can now be much more optimistic. The outcomes are much improved for children who have access to ART, with an estimated 5-year overall survival for the South African cohort<sup>10</sup> of 45.2% for Burkitt's lymphoma, 67.4% for Kaposi's sarcoma, and 69.6% for incidental malignancy (Fig. 3). These results are still inferior to those for HIV-negative children, where estimated 5-year overall survival for Burkitt's lymphoma usually exceeds 80%,<sup>23,24</sup> but early data suggest that they may prove to be comparable in those children already established on ART at diagnosis, where a small cohort of children with malignancy has achieved a 74.3% estimated 5-year overall survival (Fig. 4). If you anticipate any delay in transferring a child with suspected malignancy, start ARVs in discussion with the paediatric oncology centre.

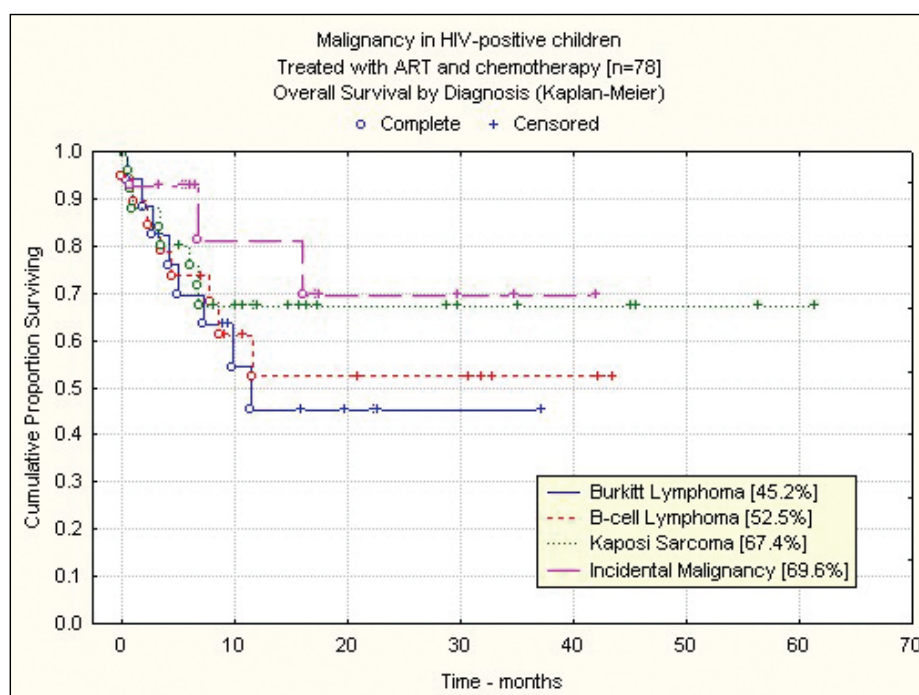


Fig. 3. Malignancy in HIV-positive children from four South African centres: patients treated with ART and chemotherapy.

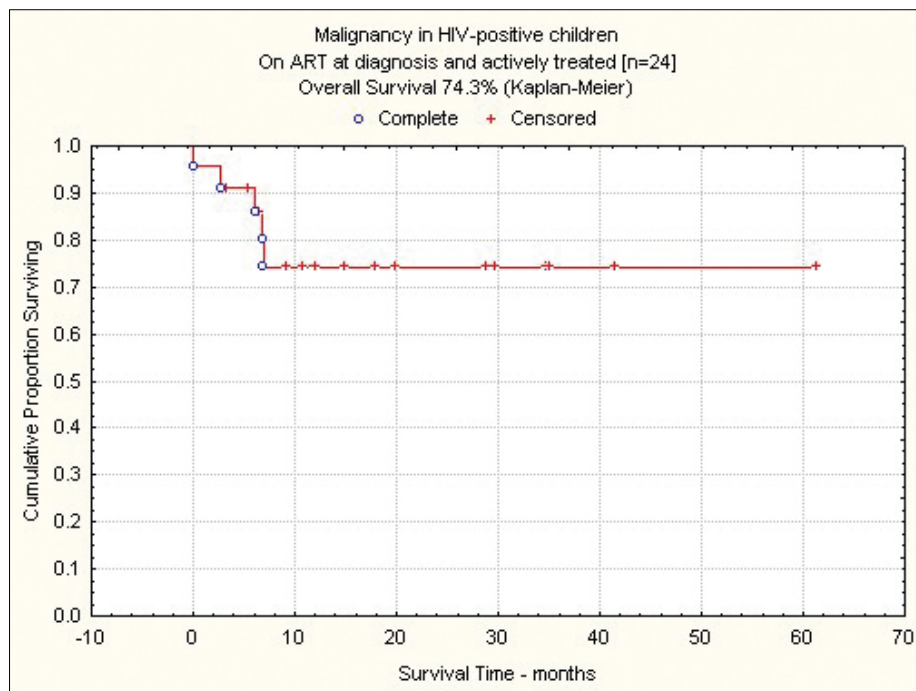


Fig. 4. Malignancy in HIV-positive children from four South African centres: patients on ART at diagnosis.

References

1. Sinfeld RL, Molyneux EM, Banda K, et al. Spectrum and presentation of paediatric malignancies in the HIV era: Experience from Blantyre, Malawi, 1998-2003. *Pediatr Blood Cancer* 2007; 48: 515-520.
2. Orem J, Otieno MW, Remick SC. AIDS-associated cancer in developing nations. *Curr Opin Oncol* 2004; 16: 468-476.
3. Cairncross L, Davidson A, Millar AJW, Pillay K. Kaposi sarcoma in children with HIV: a clinical series from Red Cross Children's Hospital. *J Ped Surg* 2009; 44: 373-376.
4. Stack M, Walsh PM, Comber H, Ryan CA, O'Lorcain P. Childhood cancer in Ireland: a population-based study. *Arch Dis Child* 2007; 92: 890-897.
5. Horner MJ, Ries LAG, Krapcho M, et al., eds. *SEER Cancer Statistics Review, 1975-2006*. Bethesda, MD: National Cancer Institute. Available at [http://seer.cancer.gov/csr/1975\\_2006/](http://seer.cancer.gov/csr/1975_2006/). Based on November 2008 SEER data submission, posted to the SEER web site, 2009. Accessed 17/1/2010.
6. Chiappini E, Galli L, Tovo P-A, et al. Cancer rates after year 2000 significantly decrease in children with perinatal HIV infection: A study by the Italian register for HIV infection in children. *J Clin Oncol* 2007; 25: 97-101.
7. UNAIDS 2008 Report on the global AIDS epidemic. <http://www.unaids.org/en/KnowledgeCentre/HIVData/GlobalReport/2008/>. Accessed 13/2/2010.
8. UNICEF. Children and AIDS: Fourth stocktaking report, 2009, November 2009. [http://www.uniteforchildren.org/files/CA\\_FSR\\_LoRes\\_PDF\\_EN\\_USLetter\\_11062009.pdf](http://www.uniteforchildren.org/files/CA_FSR_LoRes_PDF_EN_USLetter_11062009.pdf). Accessed 13/2/2010.
9. Statistics South Africa. Statistical release P0302: Mid-year population estimates 2009. <http://www.statssa.gov.za/publications/P0302/P03022009.pdf>. Accessed 13/2/2010.

10. Davidson A, Hendricks M, Geel J, Stones D, Wainwright L. Malignancy in HIV-positive South African children. *Pediatr Blood Cancer* 2009; 53: 719.
11. Dedicoat M, Newton R. Review of the distribution of Kaposi's sarcoma-associated herpesvirus (KSHV) in Africa in relation to the incidence of Kaposi's sarcoma. *Br J Cancer* 2003; 88: 1-3.
12. Davidson A. Kaposi sarcoma: The African HIV epidemic's partner in crime. *Pediatr Blood Cancer* 2010 (in press).
13. Gantt S, Kakuru A, Wald A, et al. Clinical presentation and outcome of epidemic Kaposi sarcoma in Ugandan children. *Paediatr Blood Cancer* 2010 (in press).
14. Dezube BJ, Pantanowitz L, Abouafia DM. Management of AIDS-related Kaposi sarcoma: advances in target discovery and treatment. *AIDS Read* 2004; 14: 236-238, 243-244, 251-253.
15. Olweny CLM, Borok M, Clinch J, et al. Treatment of AIDS-associated Kaposi's sarcoma in Zimbabwe: Results of a randomized quality of life focused clinical trial. *Int J Cancer* 2005; 113: 632-639.
16. Casper C, Nichols WG, Huang M-L, Corey L, Wald A. Remission of HHV-8 and HIV-associated multicentric Castleman disease with ganciclovir treatment. *Blood* 2004; 103: 1632-1634.
17. Klass CM, Offermann MK. Targeting human herpesvirus-8 for treatment of Kaposi's sarcoma and primary effusion lymphoma. *Curr Opin Oncol* 2005; 17: 447-455.
18. Mueller BU. Cancers in children infected with the human immunodeficiency virus. *The Oncologist* 1999; 4: 309-317.
19. Biggar RJ, Frisch M, Goedert JJ. Risk of cancer in children with AIDS. *JAMA* 2000; 284: 205-209.
20. Caselli D, Klersy C, de Martino M, et al. Human immunodeficiency virus-related cancer in

children: Incidence and treatment outcome - Report of the Italian register. *J Clin Oncol* 2000; 18: 3854-3861.

21. Orem J, Maganda A, Katongole Mbidde E, Weiderpass E. Clinical characteristics and outcome of children with Burkitt lymphoma in Uganda according to HIV infection. *Pediatr Blood Cancer* 2009; 52: 455-458.
22. Grulich AE, van Leeuwen MT, Falster MO, Vajdic CM. Incidence of cancers in people with HIV/AIDS compared with immunosuppressed transplant recipients: a meta-analysis. *Lancet* 2007; 370: 59-67.
23. Patte C, Auperin A, Gerrard M, et al. Results of the randomized international FAB/LMB96 trial for intermediate risk B-cell non-Hodgkin lymphoma in children and adolescents: it is possible to reduce treatment for the early responding patients. *Blood* 2007; 109: 2773-2780.
24. Patte C, Auperin A, Michon J, et al. The Société Française d'Oncologie Pédiatrique LMB89 protocol: highly effective multiagent chemotherapy tailored to the tumor burden and initial response in 561 unselected children with B-cell lymphomas and L3 leukemia. *Blood* 2001; 97: 3370-3379.
25. Sgadari C, Monini P, Barillari G, Ensoli B. Use of HIV protease inhibitors to block Kaposi's sarcoma and tumour growth. *Lancet Oncol* 2003; 4: 537-547.
26. Bower M, Weir J, Francis N, et al. The effect of HAART in 254 consecutive patients with AIDS-related Kaposi's sarcoma. *AIDS* 2009; 23: 1701-1706.
27. Bower M, Collins S, Cottrill C, et al. British HIV Association guidelines for HIV-associated malignancies 2008. *HIV Med* 2008; 9: 336-388.

In a nutshell

- There is an increased rate of Kaposi's sarcoma and B-NHL (including PCNSL) in HIV-infected children. Maintain a high index of suspicion and discuss your concerns with a paediatric oncologist.
- All children with malignancy should have their HIV status determined. A diagnosis of Kaposi's sarcoma, diffuse large B-cell lymphoma and PCNSL in particular should make one think of HIV infection.
- HIV-infected children with suspected malignancy should be referred to a paediatric oncology centre as soon as possible. Start antiretrovirals in ART-naïve children if you anticipate any delay in transfer.
- Rule out and treat TB in HIV-infected children with suspected malignancy; a diagnosis of malignancy doesn't preclude the diagnosis of TB. Initiate anti-TB medication if TB is diagnosed.