

# Laparoscopy in abdominal trauma

**The use of laparoscopy is well established in paediatric abdominal trauma.**

**ALP NUMANOGLU, MB CHB, FCS (SA)**

*Principal specialist paediatric surgeon, Red Cross War Memorial Children's Hospital, Cape Town*

*Alp Numanoglu undertook his undergraduate training in Turkey. He did his specialty training in general surgery and subspecialty training in paediatric surgery in Cape Town. His current interests are minimally invasive surgery and skill development in basic and advanced surgical techniques.*

*Correspondence to: Alp Numanoglu (alp.numanoglu@uct.ac.za)*

Use of minimally invasive surgery (MIS) in paediatrics developed more gradually than in general surgery. However, today its role is well established and indications are increasing daily. This was also the case in abdominal trauma and initial use has been mainly in diagnostics. As the technology and experience have improved indications have also become more therapeutic.

## *Minimally invasive surgery in paediatrics*

One of the main reasons for slow acceptance of minimally invasive surgery in paediatrics has been the lack of availability of appropriate instruments and equipment. Insufflators with very slow flow rates (0.1 l/m) and low pressures (6 - 8 mmHg), instruments with smaller diameter (2 - 3 mm) and short length (20 cm) had to become commercially available. Today instruments ranging from needle holders to dissectors and scissors are made in sizes that allow surgeons to operate on 1 000 g premature babies using MIS. Anaesthetic challenges also are better understood and safe surgery can be performed. Use of a digital theatre environment with improved ergonomics has resulted in faster turnover times with increased surgery.

High-definition camera systems allow the surgeon to see the surgical field in great detail and natural colours.

### **Benefits of minimally invasive surgery**

Many diagnostic methods exist (CT, ultrasound, diagnostic peritoneal lavage) for evaluation of abdominal injuries. Despite these it can sometimes still be difficult to detect the presence and evaluate the severity of intra-abdominal injuries in children. Most blunt abdominal injuries are treated non-operatively. It is also useful in children injured with sharp objects to evaluate the presence of intra-abdominal extension, establish hollow viscus injury and in some cases surgical treatment of such injury. Minimally invasive surgery has the added benefit of less postoperative pain, reduced hospital stay and fewer postoperative complications such as adhesive bowel obstructions.

The diagnosis of intestinal injuries can be delayed, despite strong clinical suspicion, serial physical examination and careful evaluation of radiological investigations such as CT scanning. Thus, in a stable patient laparoscopy has the advantage of diagnostic accuracy and can help to avoid non-therapeutic laparotomies in up to 40% of patients.

Laparotomy however remains the gold standard for diagnosis and treatment of injuries in a child with haemodynamic instability.

The algorithm for blunt and penetrating injury can be used as guidance (Figs 1 and 2).

### **Use of minimally invasive surgery in trauma**

#### ***Hollow viscus injury***

The principles of managing blunt and sharp abdominal injuries have been well established. There has been a change towards a more conservative approach in both types of injury. In adult patients, in centres where high volumes of penetrating injuries are seen, initial conservative management with careful observation and the application of set criteria for intervention have been able to reduce the need for operative intervention and negative exploration.

This has been different in paediatric groups, where laparotomy has been the choice of management of gunshot and sharp abdominal injuries. Blunt injuries resulting in hollow viscus perforation can remain undiagnosed up to an average of 18 hours before signs of peritonitis become evident. The incidence of intestinal injury following blunt abdominal trauma has been reported to be 1 - 15%. The most common site is the small intestine, the jejunum being particularly vulnerable due to its anchoring point at ligamentum Treitz. Hollow viscus perforation has a significant mortality of up to 15% in some series.

## **One of the main reasons for slow acceptance of minimally invasive surgery in paediatrics has been the lack of availability of appropriate instruments and equipment.**

Bicycle handlebar-associated injuries and seat belt injuries as well as trauma resulting in a direct blow to the abdominal cavity are well recognised causes of intestinal injury.

The diagnosis of blunt injuries is often difficult and can be delayed. Abdominal wall ecchymosis seen during initial examination is suggestive of possible hollow viscus, solid organ or spinal cord injuries. The leakage of intestinal contents resulting in peritoneal irritation may not be evident at initial examination. Abdominal radiographs are also unreliable; less than one-third may have pneumoperitoneum confirming injury. Additional studies are very often required. CT scan is currently the preferred investigation. Pneumoperitoneum once again can lead to the diagnosis but contrast studies looking for extravasation have been less helpful. Bowel wall thickening, presence of free fluid in the absence of solid organ injury and mesenteric stranding, have been proposed as markers of intestinal injury. Much emphasis has been placed on the presence of free fluid, but many would not regard this as an indication for laparotomy. Non-therapeutic laparotomy is not

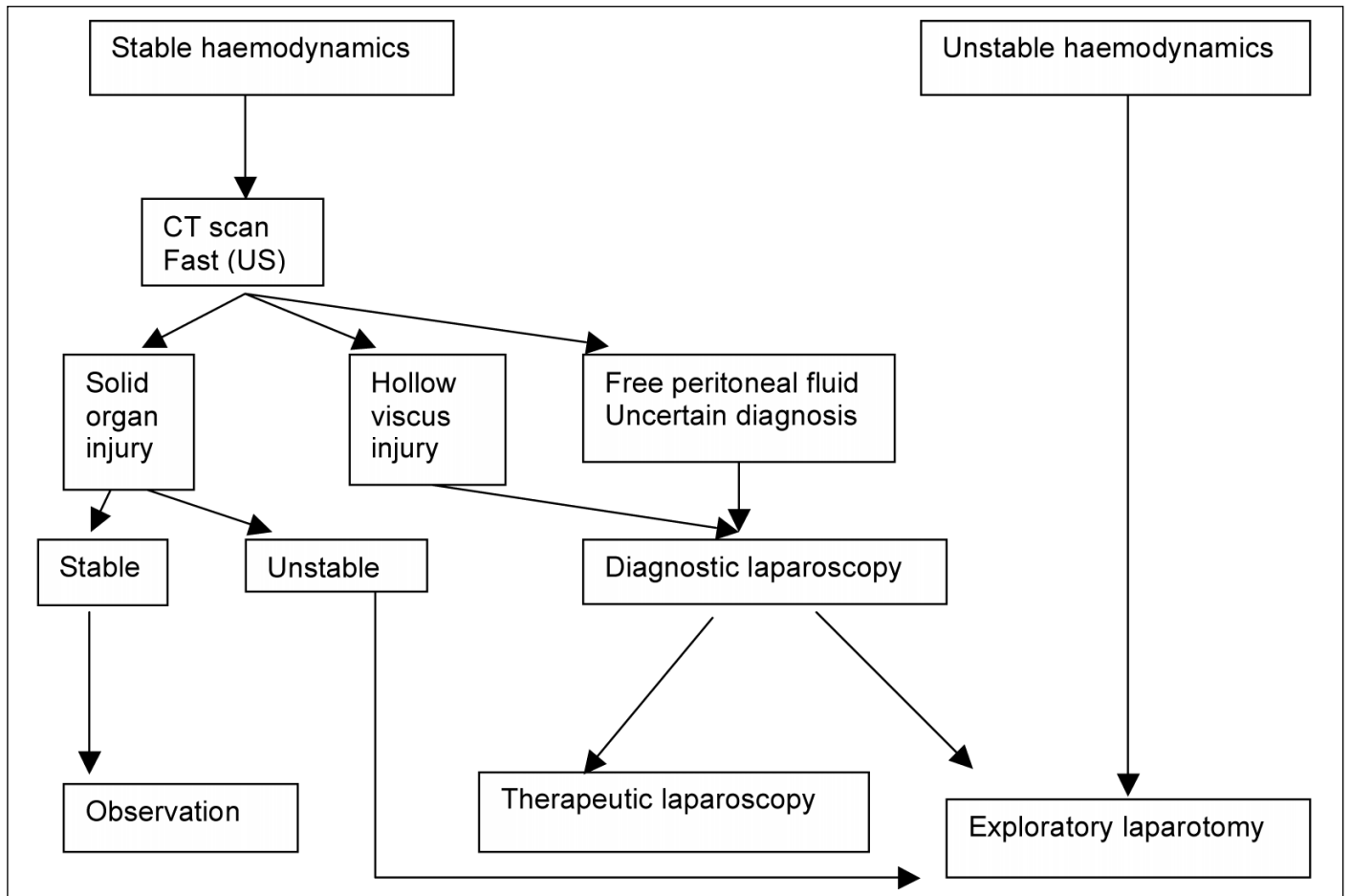


Fig. 1. Algorithm for laparoscopy in blunt abdominal trauma.

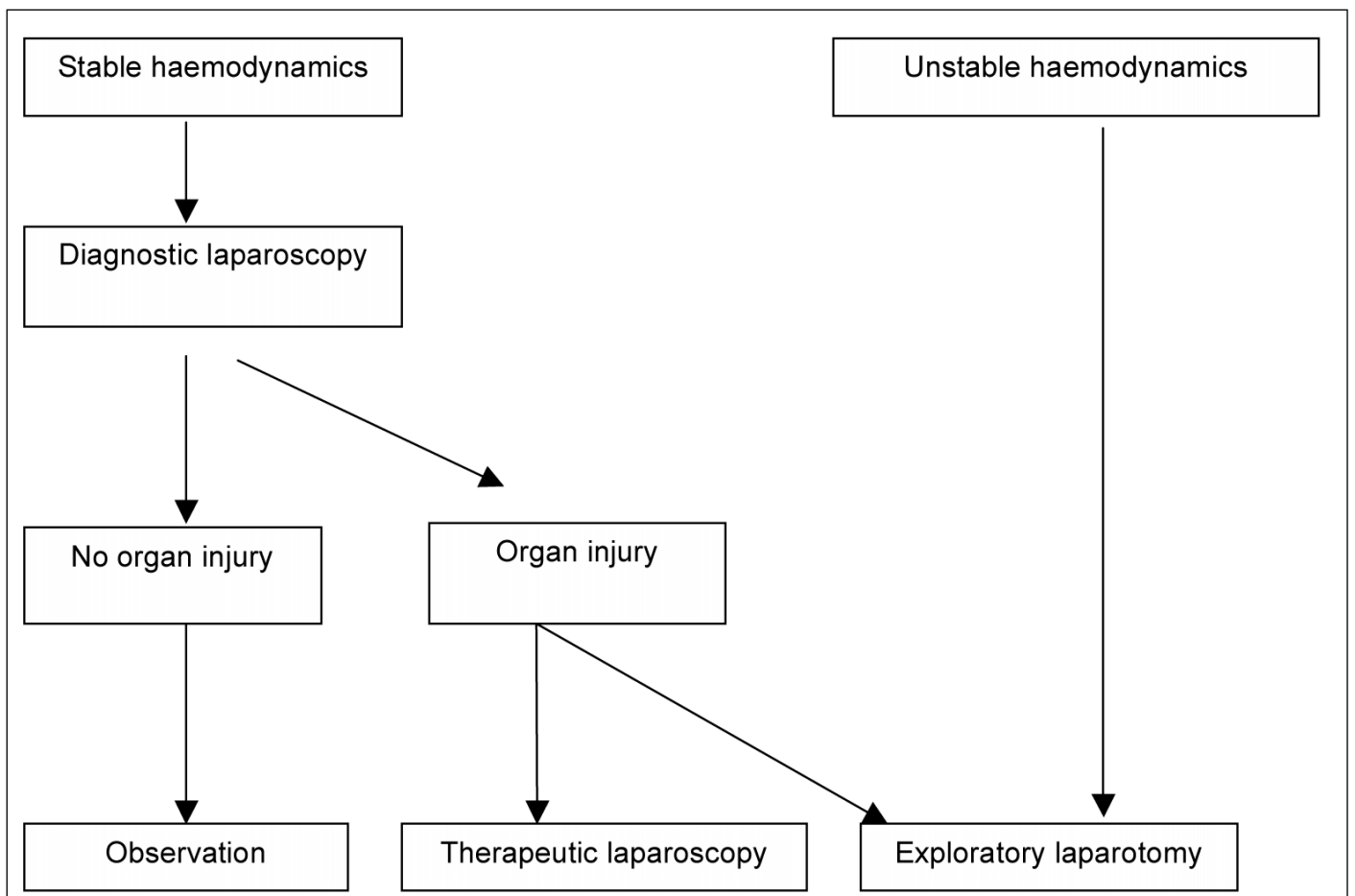


Fig. 2. Algorithm for laparoscopy in penetrating abdominal trauma (abdominal stab wounds or tangential gunshot wound injuries).

without its complications and in some series reaches an incidence of 40%.

Diagnostic laparoscopy has successfully been utilised in this setting. It is particularly important in children where short-term observations may not reveal significant information, when fever, abdominal tenderness and leucocytosis are present.

Laparoscopy allows full visual assessment of the abdominal cavity, fluid can be aspirated and sent for analysis and the whole length of the intestine can be evaluated. Retroperitoneal organs are more difficult to evaluate but very often CT scan has already demonstrated injuries prior to laparoscopy.

### Solid organ injuries

Identification of solid organ injuries depends on a high index of suspicion, abnormal physical examination findings and use of imaging and laboratory investigations.

## The diagnosis of blunt injuries is often difficult and can be delayed.

The majority of solid organ injuries are treated conservatively (90%). Abdominal CT scans are currently the most commonly used diagnostic studies; however, these expose the children to large doses of radiation. Haemodynamic instability despite aggressive resuscitation requires urgent laparotomy for diagnostic and therapeutic purposes. Valuable time should not be wasted with unnecessary imaging.

Despite the excellent accuracy of abdominal imaging there remains a subgroup of patients in which diagnostic

uncertainty remains. It is in these cases that laparoscopy has an important role.

Pancreatic injuries in children are rare. Most patients present with a classic history of having been injured directly in the epigastric region, typically with bicycle handlebars. CT scan with IV contrast is the preferred imaging technique. Pancreatic contusions are managed non-operatively with bowel rest. Duct transection management is controversial. In early publications splenic-preserving distal pancreatectomy has been advised. Laparoscopy has been successfully used both in acute and delayed distal pancreatectomies following trauma. It has been reported that magnification obtained through laparoscopic camera allows excellent identification of vessels and dissection of pancreas from splenic artery and vein. Despite the presence of fat necrosis and haematoma, dissection of the distal pancreas is possible with quick recovery and discharge from hospital.

Pancreatic pseudocyst following trauma is well recognised. It is less likely for larger cysts to resolve spontaneously and they very often require a drainage procedure. This can either be done endoscopically using a flexible endoscope to establish a fistula between cyst and stomach or with laparotomy, gastroscope and cystogastrostomy. The benefits of minimally invasive surgery over laparotomy prompted the use of this modality to establish cyst-gastrostomy. On the other hand, endoscopic drainage can be complicated by clogging of stents and inadequate drainage.

Minimally invasive surgery has also been used for the treatment of complications following conservative management of solid organ injuries. Splenic cysts which do not resolve over time can be treated with partial splenic decapsulation. Bile

leaks following conservative management of liver injuries can occur in up to 6% of patients. Endoscopic retrograde cholangio-pancreatography (ERCP) and stent placement accompanied by external drainage of bile collections is the preferred treatment modality for intrahepatic duct injuries or small extrahepatic duct leaks. Directed external drainage can be performed by laparoscopy, allowing excellent viewing of abdominal cavity breakdown of loculations and correct positioning of intra-abdominal drains.

## Laparoscopy allows full visual assessment of the abdominal cavity, fluid can be aspirated and sent for analysis and the whole length of the intestine can be evaluated.

### Conclusion

Minimally invasive surgery has been slow to gain popularity in paediatric surgical practice. However, with improved equipment and instrumentation suitable for children, more complex cases can successfully be treated today.

Laparoscopy is well established in solving diagnostic dilemmas and in many cases it can also be therapeutic. Benefits of minimally invasive surgery such as less postoperative pain, shorter hospital stay and shorter time to return to school also apply to its use in trauma.

### *In a nutshell*

- Minimally invasive surgery is increasingly used in the paediatric population.
- Small children and neonates can safely be operated on by MIS if experience is available.
- Diagnostic laparoscopy has a significant role to play when conventional imaging is inadequate.
- MIS has the added benefit of less postoperative pain and early return to home and school.
- Most solid organ injuries are treated conservatively but hollow viscus injuries can be diagnosed and treated early by MIS.
- Complications following solid organ injuries can be managed by using laparoscopy such as identification and drainage of bile duct injuries and pancreatic injuries.