

HIV-associated vasculopathy

Vasculopathy is a major feature of HIV disease.

T V MULAUDZI, MB ChB, FCS (SA), Cert Vasc Surg (SA)
Medi-Clinic Unit for Peripheral Vascular Disease, University of Pretoria

E-mail: mulaudzit@samedical.co.za

Human immunodeficiency virus (HIV) disease was first described in 1981 in the USA in young homosexual men presenting with opportunistic infections associated with severe immune deficiency.¹ The virus itself was identified 2 years later² and the link between HIV and acquired immune deficiency syndrome (AIDS) was established.

When the immune system is sufficiently depleted for the patient to develop opportunistic infection it is considered to have progressed to AIDS, and a CD4 count of less than 200 cells/ μ l is taken as AIDS-defining. Sub-Saharan Africa remains the most heavily affected, and in 2007 72% of the world population of HIV patients lived in this region.³ The global epidemic trend has stabilised but the prevalence remains high. In 2007 the estimated number of infected individuals was 33 million.³ Managing these patients has placed a huge financial burden on the already strained resources of Third World countries. HIV has brought an array of new clinical presentations and has also generated new syndromes.⁴ HIV vasculopathy was first described as an entity in 1987⁵ and may present with arterial occlusive disease and aneurysmal disease, or spontaneous arteriovenous fistula.⁶⁻⁹ The incidence of symptomatic vasculitis is in the region of 1% of HIV-infected patients.¹⁰

HIV has brought an array of new clinical presentations and has also generated new syndromes.

Aneurysms

This disease affects much younger patients than those with degenerative atherosclerotic aneurysmal disease. The median age is between 30 and 40 years.^{7,11,12} However, the majority of patients infected with HIV are females and the reason for the male preponderance of aneurysmal disease is unknown.^{3,7,11}

The pathogenesis of the aneurysms is uncertain. Histology shows obliterative endarteritis involving the vasa vasora of the major vessels. These vessels are surrounded by neutrophils, which in turn are surrounded by a cuff of plasma cells, lymphocytes and monocytes. This eventually leads to thrombotic occlusion of the vasa vasora with transmural necrosis of the vessel wall, probably due to ischaemia. HIV protein is noted in the lymphocytes, but the significance of this is uncertain as this is noted in lymphocytes throughout the body of HIV infected patients.^{7,9}

Routine cultures of the aneurysm wall have revealed no bacteria or other opportunistic infection, but this has been noted in one or two cases and is thought to be a sporadic finding. The pathogenesis is possibly related to some immune complex mechanism.

The common sites for the aneurysms are the common carotid (Fig. 1) and the superficial femoral artery (Fig. 2). They can, however, be found throughout the body, tend to be multiple, and typically have a multi-loculated appearance (Fig. 3). Many are in fact false aneurysms due to disruption of the vessel wall at the point of transmural necrosis.^{7,11,12,21}

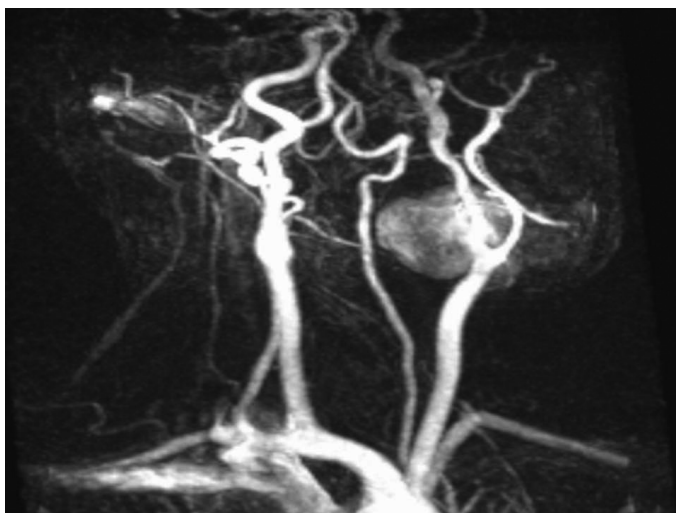


Fig. 1. Internal carotid artery aneurysm. MRA of a 33-year-old HIV-positive male patient who presented with a large neck swelling.

Symptoms and signs depend on location of the aneurysm and, for example, there may be compressive symptoms due to airway obstruction or possibly haemodynamic instability due to rupture. Thromboembolic complications are also frequent, as is associated venous thrombosis. Any patient presenting with aneurysm should be screened for multiplicity using ultrasound and CT scanning as required.

This disease affects much younger patients than those with degenerative atherosclerotic aneurysmal disease.

CD4 counts are below normal in more than 90% of patients with a median of less than 400 cells/ μ l and the CD4:CD8 ratio is usually reversed, indicative of advanced immunosuppression. However, the AIDS-defining level of less than 200 cells/ μ l is not a pathognomonic finding.

Low serum albumin with elevated globulin is a consistent feature.^{7,9,11,20,21}

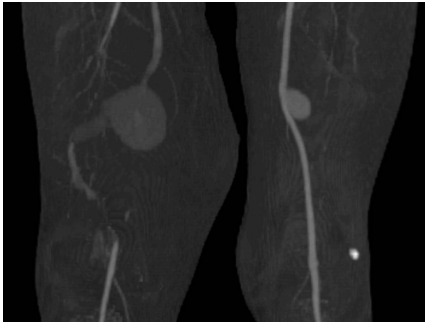


Fig. 2. Bilateral superficial artery aneurysms. CTA of a 35-year-old HIV-positive patient who presented with right thigh pain due to a ruptured SFA aneurysm.

Management of the aneurysms is according to their respective merits and patients with symptomatic lesions should not be denied therapy. However, judgement can be tested in severely malnourished and ill patients with asymptomatic lesions. The standard therapy involves open surgery following standard principles. Endovascular therapy is increasingly being applied and is an attractive option in these ill patients. Patients should be optimised as per standard practice prior to intervention although those with full-blown AIDS are probably best managed conservatively. The combination of a low CD4 count and low albumin (less than 35 g/l) are pointers towards poor operative results.^{11,20,21}

Thromboembolic complications are also frequent, as is associated venous thrombosis.

It would seem logical to offer antiretroviral therapy irrespective of the CD4 level as this manifestation is a pointer to an advanced stage of the disease. However, HIV-associated vasculopathy is not cited in the WHO clinical staging system.

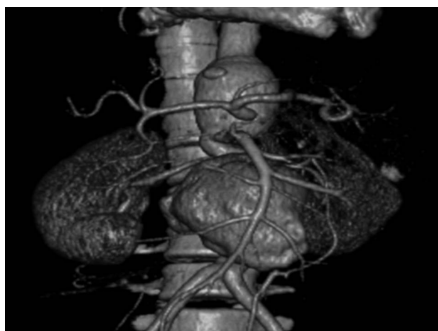

Fig. 3. Aortic aneurysms. CTA of a 40-year-old female patient who presented with abdominal pain due to a leading aortic aneurysm.

Occlusive disease

HIV-associated arterial occlusive disease is recognised as a specific clinical entity.^{6,9,11,12}

As for aneurysmal disease, young males with a median age of 30 - 40 years are mainly affected; it is difficult to explain this male preponderance.^{3,6,9,11}

The underlying cause of occlusive disease is thought to be related to vasculitis. The histological findings are similar to those found in HIV-associated aneurysmal disease, as described previously. It would appear that the manifestations are a different expression of the same vasculitic process.^{6,7,9,11,12} It has been suggested that a hypercoagulable state might be involved.¹⁵⁻¹⁸ There have been reported findings of anti-phospholipid antibody syndrome, deficiencies of free protein S, protein C and anti-thrombin 3, but these have been sporadic reports. The hypercoagulation states have been tested for in our own series and were found not to be present.^{6,9,11} Clinically most patients present with advanced disease and critical ischaemia affecting the lower limb. In most patients the disease is confined to one limb, for reasons that are obscure.^{6,9,14} It is interesting to note that on Duplex Doppler imaging there is what appears to be a pathognomonic sign with hypoechoic spotting within the arterial wall (string of pearls sign).¹⁹

Patients should be optimised as per standard practice prior to intervention although those with full-blown AIDS are probably best managed conservatively.

On arteriography it is notable that the vessels appear pristine proximal to the occlusion, as they do in the contralateral limb. The involved limb usually has extensive disease extending into the small- and medium-sized arteries with poor runoff (Fig. 4).^{6,9,11}

The management of patients with arterial thrombosis has yielded poor results.⁶ The available options are thrombo-

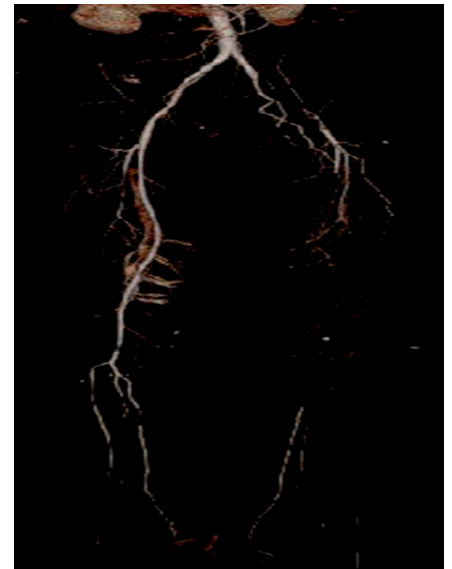


Fig. 4. Left external iliac artery occlusion. CTA of a 40-year-old HIV-positive male patient who presented with left lower limb rest pain and gangrene of the foot. He was offered an above-knee amputation.

embolectomy and thrombolysis, but the limb salvage rate has been in the region of 27%. This is thought to be due to the fact that it is mainly a vasculitic process with superimposed thrombosis, and removing the thrombus does not, in effect, solve the problem, which has a very high re-thrombosis rate. Some authors have reported acceptable patency rates in patients with disease distribution allowing for arterial reconstruction.^{11,20} A significant complication in all patients in whom surgery is attempted has been the high rate of superficial wound sepsis and graft sepsis.

Vascular surgical principles should be adhered to when managing patients with HIV-associated occlusive vasculopathy and management should be individualised. Low CD4 count should not exclude patients from surgical intervention as the surgical outcome has shown to be independent of CD4 levels.^{6,9,11,20} As for aneurysmal disease, it would appear that these patients should be offered antiretroviral therapy.

References

1. Kaposi's sarcoma and *Pneumocystis pneumonia* among homosexual men - New York City and California. *MMWR Morb Mortal Wkly Rep* 1981; 30(25): 305-308.
2. Barre-Sinoussi F, Chermann JC, Rey F, et al. Isolation of a T-lymphotropic retrovirus from a patient at risk for acquired immune deficiency syndrome (AIDS). *Science* 1983; 220(4599): 868-871.
3. UNAIDS. *Report on the Global AIDS Epidemic*. Geneva: UNAIDS, 2008.
4. Bayley AC. Surgical pathology of HIV infection: Lessons from Africa. *Br J Surg* 1990; 77: 863-881.

HIV-associated vasculopathy

- Joshi VV, Pawel B, Connor E, *et al*. Arteriopathy in children with acquired immunodeficiency syndrome. *Pediatr Pathol* 1987; 7: 261-275.
- Mulaudzi TV, Robbs JV, Pillay W, *et al*. Thrombectomy in HIV related peripheral arterial thrombosis: a preliminary report. *Eur J Vasc Endovasc Surg* 2005; 30(1): 102-106.
- Nair R, Abdool-Carrim ATO, Chetty R, Robbs JV. Arterial aneurysm in patients infected with human immunodeficiency virus: A distinct clinicopathology entity? *J Vasc Surg* 1999; 29: 600-607.
- Nair R, Chetty R, Woolgar J, Naidoo NG, Robbs JV. Spontaneous arteriovenous fistula resulting from HIV arteritis. *J Vasc Surg* 2001; 3(1): 186-187.
- Nair R, Robbs JV, Chetty R, Naidoo NG, Woolgar J. Occlusive arterial disease in HIV-infected patients: a preliminary report. *Eur J Vasc Endovasc Surg* 2000; 20: 353-357.
- Kaye B. Rheumatologic manifestations of HIV infections. *Clin Rev Allergy Immunol* 1996; 14: 385-416.
- Botes K, Van Marle J. Surgical intervention for HIV-related vascular disease. *Eur J Vasc Endovasc Surg* 2007; 34: 390-396.
- Chetty R, Batitang S, Nair R. Large vessel vasculopathy in HIV positive patients: another vasculitic enigma. *Hum Pathol* 2000; 31: 374-379.
- Revised WHO clinical staging of HIV/AIDS for adult and adolescent, 2005.
- Mulaudzi TV, Robbs JV, Paruk N, Pillay B, Madiba TE, Govindsamy V. The influence of diabetes on short-term outcome following femoro-popliteal bypass. *CVJSA* 2009; 20(3): 184-186.
- Feffer SE, Fox RL, Orsen MM, Harjai KJ, Glatt AE. Thrombotic tendencies and correlation with clinical status in patients inflected with HIV. *South Med J* 1995; 88(11): 1126-1130.
- Saif MW, Greenberg R. HIV and thrombosis: a review. *AIDS Patient Care STDS* 2001; 15(1): 15-24.
- Sorice M, Griggi T, Arcieri A, d'Agostino F, *et al*. Protein S and HIV infection.. The role of anticardiolipin and anti-protein S antibodies. *Thromb Res* 1994; 73(3-4): 65-75.
- Zietz C, Hotz B, Sturzl M, Rauch E, Penning R, Lohrs U. Aortic endothelium in HIV-1 infection: chronic injury, activation, and increased leukocyte adherence. *Am J Pathol* 1996; 149(6): 1887-1898.
- Woolgar JD, Ray R, Maharaj K, Robbs JV. Colour Doppler and grey scale ultrasound features of HIV-related vascular aneurysm. *Br J Radiol* 2002; 75: 884-888.
- Paruk N, Robbs JV, Mulaudzi TV, Pillay B. *HIV Vasculopathy*. Presentation at VASSA October 2008, Champain Spot Drakensberg Mountains.
- Nair R, Robbs JV, Naidoo NG, Woolgar J. Clinical profile of HIV related aneurysms. *Eur J Vasc Endovasc Surg* 2000; 20: 235-240.

In a nutshell

- HIV-related vasculopathy (aneurysmal and occlusive disease) may be different expressions of the same pathological process.
- This is, in both cases, due to an obliterative vasculitis affecting the vasa vasora of the vessels characterised by white cell cuffing around the vessels.
- Most patients have low CD4 counts, which indicate advanced immunosuppression although this is not an AIDS-defining condition.
- In each case management should be on individual merit. Symptomatic aneurysms should be treated as should occlusive disease.
- The operative results with aneurysm surgery are reasonable although the limb salvage rate with obliterative disease is poor.
- A case should be made for antiretroviral treatment in this group of patients.

Single suture

Cancer drugs could help alcoholics

Alcohol abuse could be treated with cancer drugs, if they work the same way in humans as they do in fruit flies. Many alcoholics can hold their drink well – one reason they overdrink. Others cannot – probably a genetic difference. A team led by Ulrike Heberlein at the University of California, San Francisco, looked at fruit flies to try to get to the bottom of this difference.

Flies respond to drink in a similar way as humans – initially hyperactive and then uncoordinated – eventually falling over and being unable to right themselves. Heberlein's team found a gene, now called *happyhour*, that makes fruit flies sensitive to alcohol. It appears to do this by damping down the activity of a cellular network called the epidermal growth factor (EGF) pathway.

The EGF pathway is also implicated in cancer, which suggests that anticancer drugs that interfere with this pathway might increase alcohol sensitivity and make alcohol less appealing. The team found that when they gave the drugs erlotinib and gefitinib to flies, they were more likely to be knocked out by alcohol. Rats also chose to drink less alcohol after taking erlotinib.

If these drugs also lower alcohol tolerance in people they could be used to treat alcoholism – hopefully at lower doses than those used in cancer treatment.

New Scientist 2009; 30 May