

HIV and ENT

It has been well documented that 70 - 90% of patients with HIV will at some stage present with an ENT manifestation of the disease.



D E LUBBE

MB ChB, FCORL (SA)

Senior Registrar

Division of Otorhinolaryngology

Groote Schuur Hospital

Cape Town

Dr Lubbe qualified as an ENT surgeon at the University of Cape Town in 2003 and is currently working as a senior registrar in the Department of Otorhinolaryngology at Groote Schuur Hospital. Her current MMed project includes the investigation of otitis media with effusion in the HIV-positive population to determine the natural progression of the disease and to establish a treatment protocol.

According to World Health Organisation (WHO) statistics for the year 2002, there are an estimated 5.3 million South Africans living with HIV. Although southern Africa is home only to 2% of the world's population, the region accounts for 30% of people living with HIV worldwide.¹

It has been well documented that 70 - 90% of patients with HIV will at some stage present with an ENT manifestation of the disease. Most of them will initially present to the general practitioner and it is important that the ENT manifestations of HIV are recognised early and that appropriate management is instituted. Antiretroviral therapy can prevent and cure most of these diseases, but as this option is not readily available to the majority of South Africans we need to look at alternative treatment.

HIV-positive patients will be included, knowingly or unknowingly, in all general practices and may present with a complaint totally unrelated to their underlying disease or with an AIDS-defining opportunistic infection or malignancy. Routine organisms predominate when it comes to infections of the ear, nose and throat, which means that HIV-positive patients should be treated with the same antibiotic as HIV-negative patients, based on the most likely organism responsible for that specific infection. The most common ENT manifestations of HIV are listed in Table I.

ORAL CAVITY MANIFESTATIONS

Contrary to medical training in the pre-HIV era, multiple lesions can be present simultaneously in those infected with HIV. Recent studies have proved that there is a decreased appearance in the occurrence of buccal lesions in those on triple antiretroviral therapy.²

Oral candidiasis is one of the earliest and most common findings suggesting HIV infection and is characterised by a typical cottage cheese inflammatory appearance. These patients usually still appear healthy, but if a known HIV-positive patient develops thrush, long-term survival appears to be diminished. Four different types of oral candidiasis can be identified:

- Pseudomembranous candidiasis. This is the classic form identified by a white plaque that can be scraped off, leaving an erythematous, bleeding base.
- Hyperplastic candidiasis. These lesions can easily be confused with leukoplakia or oral hairy leukoplakia since they appear as thick white plaques that cannot be scraped off. If there is any doubt regarding the diagnosis, a biopsy is indicated.
- Atrophic candidiasis. This presents as flat atrophic lesions involving the oral and oropharyngeal mucosa.
- Angular cheilitis. These are oral commissure erythematous lesions that can involve the adjacent skin.

Topical agents are usually effective in the early stages of HIV infection, but with advanced disease and increasing immune deficiency, systemic therapy (with fluconazole and rarely amphotericin B) may be indicated. Oesophageal or pharyngeal candidiasis is more common in this patient population and should be suspected in patients with oral candidiasis who develop a severe sore throat or difficulty in swallowing.

Table I. ENT manifestations of HIV

Oral	Nose and paranasal sinuses	Otological and neurotological	Head and neck
<ul style="list-style-type: none"> • Recurrent aphthous ulcers • Candidiasis • Herpes simplex • Gingivitis • Stomatitis • Periodontitis • Condylomata • Hairy leukoplakia • Kaposi's sarcoma • Non-Hodgkin's lymphoma 	<p>Cutaneous lesions</p> <ul style="list-style-type: none"> • Kaposi's sarcoma • Herpes simplex • Herpes zoster • Seborrhoeic dermatitis <p>Non-cutaneous</p> <ul style="list-style-type: none"> • Adenoid hypertrophy • Eustachian tube obstruction • Allergic rhinitis • Acute AND chronic sinusitis 	<ul style="list-style-type: none"> • Otitis externa • Otitis media with effusion • Eustachian tube dysfunction • Kaposi's sarcoma • Sensorineural hearing loss • Bell's palsy 	<ul style="list-style-type: none"> • Generalised lymphadenopathy • Neck mass • <i>Mycobacterium tuberculosis</i> • <i>Mycobacterium avium</i> • Cryptococcosis • Histoplasmosis • Coccidioidomycosis • Parotid gland cyst

Oral hairy leukoplakia (Fig. 1) is a condition almost pathognomonic of HIV infection and often indicates progression to AIDS. The lesion most frequently appears on the lateral aspect of the tongue with a thick, vertically correlated ('hairy') whitish plaque, very similar in appearance to the hyperplastic type of oral candidiasis. Potassium hydroxide (KOH) preparations of surface scrapings will identify the mycelia or hyphae seen in candidiasis and can therefore be used to differentiate between these two conditions. A biopsy of the lesion will be diagnostic of oral hairy leukoplakia. The Epstein-Barr virus has been identified as the most likely causative agent. Oral hairy leukoplakia is typically asymptomatic and does not usually require any treatment, but it is a significant finding because of its diagnostic and prognostic implications. The lesions have been successfully treated with aciclovir (2 g/day), sulpha drugs, zidovudine or topical retinoic acid (Fig. 1).

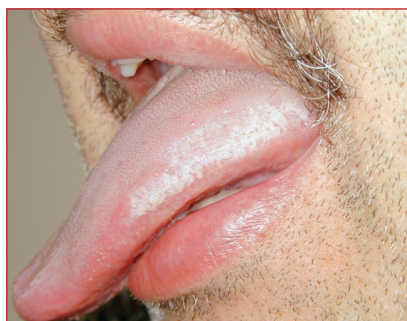

Fig. 1. Oral hairy leukoplakia (reproduced with permission from Professor Jos Hille).

Herpes simplex infections are more common in those infected with HIV, with herpes labialis being the most common manifestation. These 'fever blisters' are larger, more numerous, recur more often and persist for longer periods. Herpes simplex virus type 1 (HSV-1) is most commonly involved and usually begins as small bullae that rupture and then coalesce. It can extend onto the adjacent facial skin and form giant herpetic lesions. If the diagnosis is in doubt then smears or scrapings should be taken before starting treatment. Mild oral herpes infections can usually be treated conservatively, but high-dose oral aciclovir (up to 4 g/day) should be used for more severe lesions. Aciclovir will only be effective in eradicating the lesions if started within the first few days of infection. Prophylactic aciclovir can be used in the severely immunocompromised patient with frequent recurrences.

Periodontal disease, gingivitis and necrotising gingivitis are much more severe in the HIV-positive patient and can produce significant morbidity with extensive tissue destruction. HIV-associated gingivitis usually begins with erythematous, bleeding gums after minor trauma and can then rapidly progress to a necrotising process known as acute necrotising ulcerative gingivitis (ANUG), a condition that has once again resurfaced in the HIV-positive population. It is therefore imperative that HIV-infected indi-

viduals practise good oral hygiene and that even a mild gingivitis be treated early and adequately. Treatment consists of rinsing the mouth with chlorhexidine solution, antibiotics against Gram-negative anaerobes and early referral to an oral surgeon if the condition progresses.

Recurrent aphthous ulcers are frequently encountered in the HIV-positive patient and present as painful ulcers on the non-keratinised unattached oral mucosa. They vary in size from 0.2 mm to > 6 mm. Treatment is aimed at symptomatic relief using antiseptic mouthwashes, topical steroids and topical anaesthetics. In cases of large ulcerative lesions and frequent recurrences a biopsy should be considered if lesions do not respond to treatment.

AIDS patients have a much higher incidence of developing oral cavity Kaposi's sarcoma and non-Hodgkin's lymphoma.

Kaposi's sarcoma (Fig. 2) is the most common oral tumour in AIDS patients and one of the AIDS-defining illnesses. These dark, purple/pink macular lesions can be found on any oral mucosal surface, but the palate is involved in 95% of cases. Although the diagnosis is usually easily made based on clinical findings, an excisional biopsy is indicated, preferably from a cutaneous lesion, as these lesions are vascular and can bleed

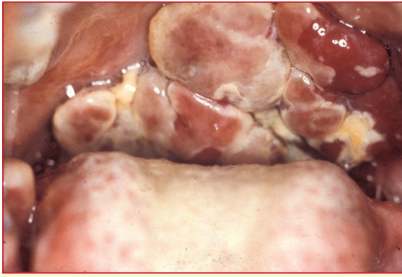


Fig. 2. Kaposi's sarcoma of the palate (reproduced with permission from Professor Jos Hille).

profusely. Treatment is mostly palliative, as HIV-positive patients with Kaposi's sarcoma are already severely immunocompromised and the eventual cause of death is usually opportunistic infections and not tumour effects. Treatment also depends on whether there is a solitary tumour or disseminated disease. Although Kaposi's sarcoma is very radiosensitive and localised tumours respond well to low-dose radiotherapy with a good palliative result, HIV-positive patients appear to be more susceptible to radiation-induced mucositis and cannot tolerate wide-field radiation. Alternative treatment options include intralesional chemotherapy for solitary lesions and systemic chemotherapy for disseminated disease. Systemic therapy causes further immunosuppression, with an increased risk of opportunistic infections. Laser and cryotherapy have also been used for localised tumours.

Non-Hodgkin's lymphoma is the second most common AIDS-associated malignancy. The tumours are exophytic and can involve the alveolar ridge, palate, gingiva, sinonasal cavity, orbit, neck and nearly any other site. Most patients have extranodal disease and 70% of cases have high-grade disease, with a poor prognosis and systemic chemotherapy options limited by the already compromised immune system. The diagnosis must be made by tissue biopsy if from an extranodal site or by doing a complete excisional biopsy from the lowest, largest involved cervical lymph node in the neck.

The association between **squamous cell carcinoma (SCC) of the head and neck** and HIV infection is still

controversial. It has been noted, however, that there are many young HIV patients with no or moderate risk factors for SCC who present with this condition of the oral cavity.³ SCC seems to present at an earlier age and tends to be more aggressive in HIV-positive patients compared with HIV-negative patients in the same age group. This suggests that there might be a relationship between SCC and HIV infection, although there is as yet little evidence to support this. The lateral tongue is most frequently involved and the lesion can be either infiltrative or exophytic. Diagnosis is made on biopsy and management of the HIV-positive patient with SCC should be no different from that of an HIV-negative patient. Unless the patient is surgically unfit or severely immunocompromised, s/he will benefit from surgical resection and neck dissection, as conventional radiotherapy is poorly tolerated.

HIV SINONASAL MANIFESTATIONS

Between 40% and 70% of patients with AIDS will present with allergic rhinitis, sinusitis, a blocked nose or symptoms suggesting a possible sinonasal malignancy. The most common sinonasal complaint is that of a blocked nose, the most likely causes being adenoidal hypertrophy and allergic rhinitis. HIV-infected individuals often suffer from other common illnesses, such as TB, which can present with unusual manifestations of the disease (Fig. 3).

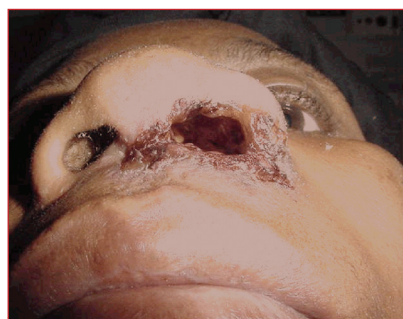

Fig. 3. An old disease (TB) with an unusual presentation.

Adenoidal hypertrophy will present as persistent nasal obstruction. In the adult patient this demands further investigation and the possibility of HIV

infection must be entertained. In HIV-positive patients enlarged adenoids are most commonly due to lymphoid hyperplasia and generalised lymphadenopathy and enlarged tonsils are frequently part of the clinical picture. The aetiology is thought to be related to B-cell activation by HIV, Epstein-Barr virus or cytomegalovirus. Otitis media with effusion (OME), causing a conductive hearing loss, often follows owing to obstruction of the Eustachian tubes by the lymphoid mass in the postnasal space. Lymphoma, especially high-grade B-cell lymphoma, needs to be excluded. The diagnosis of a postnasal mass can be made by doing a posterior rhinoscopy using an angled mirror, a lateral radiograph of the neck or a flexible nasopharyngoscope, the last being the method of choice used by ENT surgeons. A biopsy of the mass can then be taken either under local or general anaesthesia. For lymphoid hyperplasia, an adenoidectomy is frequently done to relieve symptoms of nasal obstruction and OME. Lymphoma is treated with systemic chemotherapy, and radiotherapy is given if the tumour causes any mass effect.

Allergic rhinitis is very common in the HIV-positive population. Although cellular immunity is depressed, there seems to be increased polyclonal B-cell activation with increased circulating immune complexes and increased levels of IgE. These high levels of IgE then lead to increased IgE-mediated allergic symptoms. Patients present with sneezing, watery rhinorrhoea and a blocked nose. Treatment consists of allergen avoidance, topical steroids and oral antihistamines.

Acute, recurrent and chronic **rhinosinusitis** occurs in 20 - 68% of HIV-infected patients. Predisposing factors include allergic rhinitis, with the oedematous mucosa leading to obstruction of the sinus ostia, and decreased local and systemic immunity. The microbiology is similar to that found in the HIV-negative population, with the exception of two atypical opportunistic organisms, *Pseudomonas aeruginosa* and *Aspergillus fumigatus*. Initial man-

agement should be restricted to the use of first-line drugs such as amoxicillin or amoxiclav. Mucormycosis, although found in the neutropenic immunocompromised host, is not a common disease in the HIV-infected patient. The reason for this is that the HIV-positive patient does not become neutropenic until the final stages of the disease process.

NECK MANIFESTATIONS

Enlarging neck masses frequently occur in the HIV-infected population and up to 90% of patients with an ENT manifestation will present with a neck mass as well. The diagnostic approach differs slightly from that of the HIV-negative patient where investigations are mostly aimed at excluding a malignancy. The differential diagnosis of a neck mass in the HIV-positive patient can be broadly divided into the following categories:

- HIV lymphadenopathy
- parotid disease
- infections
- neoplasms.

Persistent generalised lymphadenopathy is present in up to 70% of patients in the initial period after seroconversion and can be defined in adults as lymphadenopathy greater than 1 cm, of unexplained aetiology and involving 2 or more extra-inguinal sites for longer than 3 months.⁴ Indications for further investigations and fine-needle aspiration cytology (FNAC) include the following: rapidly enlarging lymph nodes, a dominant node, asymmetrical lymphadenopathy, firm non-mobile nodes and recent weight loss.

Parotid gland enlargement is commonly encountered in HIV-infected adults and children who are not on antiretroviral therapy. HIV-associated cystic lympho-epithelial disease (benign lympho-epithelial cysts) is a disease process unique to HIV-infected individuals and the aetiology is thought to be related to a lymphoid response to HIV infection. Patients usually present with bilateral, painless parotomegaly and, except for the cosmetic deformity, these lesions are

completely asymptomatic. The natural progression of the disease is unknown. Management of these lesions includes confirming the diagnosis with ultrasound or FNAC. Ultrasound clearly shows multiple cystic lesions within the parotid gland. Treatment is guided by the severity of the cosmetic deformity and includes antiretroviral therapy, aspiration of the cysts with tetracycline sclerosis and low-dose radiotherapy.

Infectious processes causing cervical lymphadenopathy include tuberculosis, non-tuberculous mycobacterial infections, toxoplasmosis, bacterial lymphadenitis and fungal infections.

OTOLOGICAL MANIFESTATIONS

Ear manifestations occur less frequently than the abovementioned ENT manifestations. HIV-infected individuals do not have a higher incidence of otitis externa and they are not more prone to develop necrotising otitis externa when compared with other immunocompromised patients such as diabetics.

The incidence of **OME** is higher in the HIV population than in the general population, and if an adult patient presents with bilateral middle ear effusions the possibility of HIV infection must be considered. Patients with OME must be referred to an ENT surgeon for further investigations and exclusion of a postnasal lesion obstructing the eustachian tubes. Treatment is still controversial, but includes the insertion of ventilation tubes and an adenoidectomy if indicated.

Sensorineural hearing loss occurs in the HIV-infected patient and the causes include a direct effect of the neurotropic virus on the cochlear nerve, syphilis, and cryptococcal meningitis. Investigations include a complete audiology work-up, ENT examination, laboratory tests to exclude syphilis, and imaging if indicated. Cerebrospinal fluid is sampled in some instances to detect *Treponema pallidum* and the cryptococcal antigen.

Acknowledgements

I would like to thank Professor Jos Hille of the National Health Laboratory Services/University of the Western Cape (NHLS/UWC) for providing two illustrations.

References available on request.

Further reading

Moazzez AH, Alvi A. Head and neck manifestations of AIDS in adults. *Am Fam Physician* 1998; **57**: 1813-1821.

Tami TA. Otolaryngologic manifestations of acquired immunodeficiency syndrome. *Otolaryngol Clin North Am* 1992; **25**: 1147-1367.

IN A NUTSHELL

Routine organisms predominate when it comes to infections of the ear, nose and throat.

HIV-positive patients should initially be treated with the same antibiotic as HIV-negative patients.

Multiple oral lesions can be present simultaneously.

Oral candidiasis and rhinosinusitis are the commonest ENT manifestations of HIV.

Oesophageal candidiasis must be suspected in patients with increasing dysphagia and odynophagia.

Oral hairy leukoplakia is a condition almost pathognomonic of HIV infection and often indicates progression to AIDS.

Kaposi's sarcoma is the most common HIV-associated oral tumour and predominantly occurs on the palate.

HIV-associated cystic lympho-epithelial disease of the parotid is a disease process unique to HIV-infected individuals.

OME in the adult patient must be investigated and the HIV status of the patient ascertained.