

SPORTS IMAGING FOR THE GENERAL PRACTITIONER

Sport plays a very important role in the day-to-day life of the average South African, be it at the social or professional level.



RICHARD DE VILLIERS

MB ChB, MMed (Rad D)

Radiologist in private practice

Somerset West and Stellenbosch

Dr De Villiers is an honorary consultant radiologist at the SA Sports Science Institute, Newlands and at Tygerberg Academic Hospital, University of Stellenbosch. He specialises in musculoskeletal imaging with a special interest in imaging of sports injuries. He was the Convenor of the 1st and 2nd SA Sports Imaging Congresses and Chairman of the SASMA Imaging Group, and was a member of the Sydney Olympics 2000 radiology staff.



JEAN-CLAUDE KOENIG

MB ChB, BSc (Med) Hons

(Sports Medicine)

Radiology Registrar

Groote Schuur Hospital Cape Town

Dr Koenig practised as a sports physician for 10 years in private practice in Stellenbosch and Cape Town. In 1994 he worked in Wellington, New Zealand, in an accredited sports medicine training practice. In 1998 he joined the private practice of Derman, Noakes and Schweltnus at the Sports Science Institute in Newlands, Cape Town.

Injury commonly results from wear and tear during sport, and the minor ailments that may be tolerated or overlooked by the less active become a significant problem to the athlete. These injuries interfere with performance and enjoyment, and if subjected to continued stress can develop into significant problems. As many of these conditions are sports related and sometimes even specific to a particular sport, the care of the athlete has become a specialised field of medicine.

The skill of many different practitioners can be utilised in the sports medicine team, namely the general practitioner, sports physician, orthopaedic surgeon, radiologist and physiotherapist. Accurate information and communication between these practitioners is vital in providing the best service to sportsmen and women. The range of radiological imaging modalities available today allows accurate assessment of acute and chronic injuries to bone, articular cartilage, joints, ligaments, tendons, muscles, bursae and nerves.

Sports imaging in South Africa has become the latest addition to the multifaceted radiology discipline. The recent advances in high-quality radiography, high-resolution ultrasound, helical multi-slice computed tomography (CT) and high field strength magnetic resonance imaging (MRI) have been able to demonstrate the musculoskeletal system as never before. Interventional procedures under ultrasonic and CT guidance can accurately infiltrate areas of interest. Sports injuries are often subtle and difficult to pinpoint clinically. Radiology has demonstrated the ability to help the multidisciplinary sports medicine fraternity in the quest to establish the correct diagnosis, so as to expedite treatment and return the athlete to competitive level as soon as possible.¹

IMAGING MODALITIES

Plain film

X-rays are the initial modality of choice due to availability and cost. Image quality is of the utmost importance as pathology may be missed on poor-quality radiographs. The importance of optimal radiographic technique is stressed. Correct positioning, knowledge of additional views to demonstrate the suspected abnormality, correct exposure values, correct film-screen combinations, good-quality film and good equipment are all factors contributing to the final result of the X-ray film from which the radiologist must make the diagnosis. The importance of demonstrating the soft tissues is important to evaluate subtle calcification, bone flakes, periosteal reaction and muscle/tendon inser-

tions. Usually two opposite planes are requested, e.g. antero-posterior (AP) and lateral. If indicated, additional specific views, such as oblique views of a hip joint or lumbar spine, ankle mortise, tibiofibular joint, etc. must be requested.²

Other special views

Spine. Tomography for vertebral injuries, especially upper cervical and thoracic spine where CT is not available. Swimmers view to assess cervicothoracic junction. Flexion and extension views to assess ligamentous injury. Active patient control of movement, not passive, in suspected acute ligamentous injury. Stress views of the lumbar spine are used to assess the degree of spondylolisthesis with bilateral pars interarticularis fractures.

Shoulder. Rotated views, e.g. external rotation view of greater tuberosity of humerus. Outlet view for impingement. Scapular views for focal scapular pathology. Acromioclavicular joint — weight-bearing stress views are indicated to assess ligamentous integrity (Fig. 1).

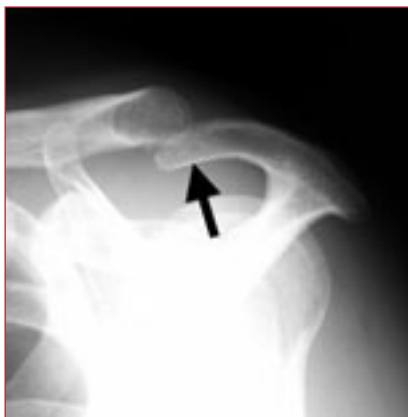

Fig. 1. Outlet view of the shoulder, demonstrating a hooked acromial profile.

Elbow. Supination and pronation.

Wrist. Clenched fist view, scaphoid views, ulnar and radial deviation.

Pelvis. Flamingo view for pubic symphysis instability, Judet views of anterior and posterior columns.

Femur. Internal or external rotation views to assess the lesser and greater trochanters.

Knee. Both oblique views with internal rotation profiling the tibiofibular joint and external rotation of the medial tibiofemoral joint, lateral shoot through to assess for joint effusions, intercondylar notch view to assess for osteochondritis dissecans and tibial spine fractures, skyline view of patella to assess the patello-femoral joint as well as stress views to assess ligamentous injury. Tomography is useful to assess tibial plateau fractures.³

Ankle. The distal tibiofibular joint is best imaged with rotational (external) stress views for the anterior-inferior tibiofibular ligament/syndesmosis injuries. Stress views are indicated only if one is clinically uncertain of ligamentous injury and comparison with the uninjured side is important.² Anterior-posterior (drawer sign) stress view for the anterior talo-fibular ligament; inversion (varus) views for the calcaneofibular and posterior talofibular ligaments; eversion (valgus) stress views for the deltoid ligament; anterior (dorsiflexion) and posterior (plantar-flexion) impingement views for impingement syndromes.⁴

Foot. In fractures of the base of the fifth metatarsal it is important to distinguish between an avulsion fracture of the tuberosity and a Jones fracture (proximal metaphysis/diaphysis), as the latter requires more aggressive treatment and is prone to non-union. It is also important to be aware of the normal parallel secondary ossification centre that may be present, as well as two accessory ossicles (os peroneum in peroneus longus tendon and os vesalianum in peroneus brevis), and not to confuse these with fractures.

NB: In general, follow-up X-rays at 2 weeks may reveal a periosteal reaction around a previously occult fracture.⁵

Ultrasound

High-definition ultrasound has improved the imaging of tendinopathies, ligament injuries, muscle tears/haematomas and bursal pathology. Other than its ever-growing use in soft-tissue, ligament and joint injuries, ultrasound can detect periosteal injuries as well as subtle flakes of bone in injuries to the clavicle, fibula, tibia and iliac crest (hip pointer — injury to periosteum of iliac crest) (Figs 2 and 3).

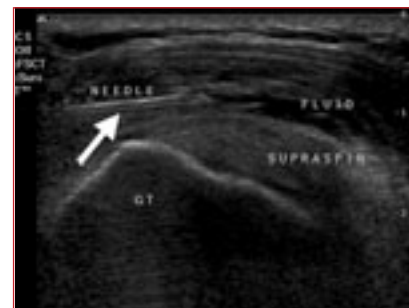

Fig. 2. Ultrasound-guided injection into subacromial bursa.

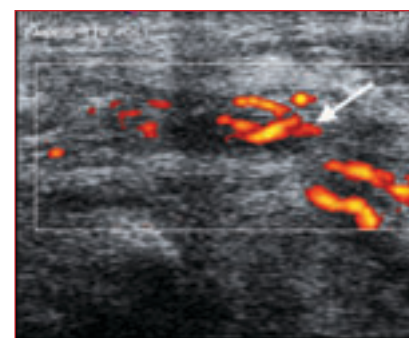


Fig. 3. Power Doppler ultrasound showing increased vascularity of tibialis posterior tenosynovitis.

Linear array transducers able to achieve 10 - 14 MHz frequencies are able to evaluate the soft tissues as never before, having the added bonus of scanning both in the static and dynamic state.⁶ Diagnosis of sports hernia by static and dynamic ultrasound is now possible. Shoulder ultrasound is well established as the primary diagnostic tool in the management of rotator cuff injury.⁷ Interventional procedures are possible under ultrasonic guidance. The addition of power Doppler to the above can identify active inflammation due to the increased peripheral blood flow.²

Conventional tomography

This modality is useful when more detailed information is required by providing an image of any selected plane in the body while blurring out structures above and below that plane. It is only used where CT is not readily available.⁵

Computed tomography

CT is the examination of choice for bone pathology. Images are obtained in the axial (transverse) plane and can be reconstructed into sagittal, coronal and 3D images. Thin 1 - 2 mm slices give high-resolution images. Spiral CT has the advantage of ultra-fast scanning times, which decrease movement artefacts. Lately, multi-slice CT provides excellent contrast and sub-millimetre resolution of bony injuries (Figs 4 - 6). CT is particularly useful in subtle fractures in difficult areas, e.g. sacrum, pars interarticularis of the spine acetabulum, shoulder and sternoclavicular joint. CT arthrography is of particular use in the evaluation of acetabular and glenoid labral injury.²

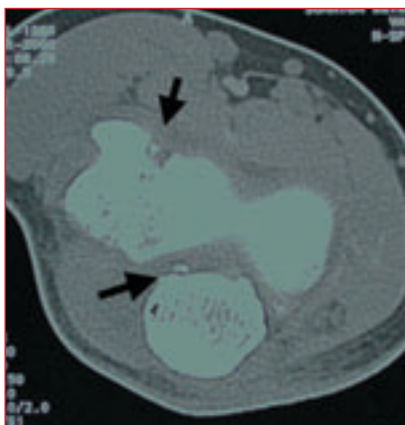


Fig. 4. CT of the elbow showing loose bony fragments from osteochondritis dissecans of the humeral capitellum in the joint space.

Magnetic resonance imaging

MRI has the advantage of imaging in the axial, sagittal and coronal planes. Soft-tissue contrast is superior to other imaging techniques. With conventional pulse sequences normal anatomic tissues have fairly characteristic signal intensities. T1-weighted images generally display anatomy optimally, while T2-weighted images display pathological conditions in broad terms. On T1

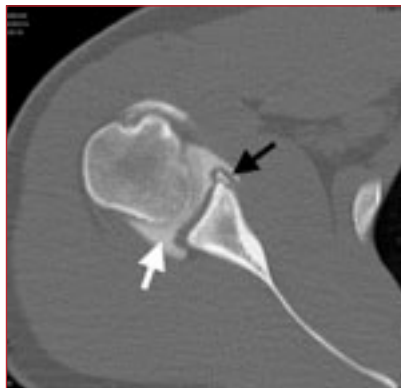

Fig. 5. CT arthrogram of the shoulder demonstrating Bankart lesion of anterior glenoid (black arrow). Note contrast in joint space (white arrow).

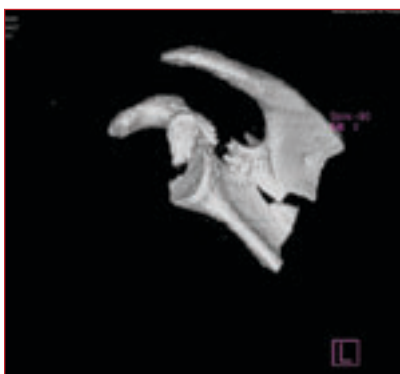


Fig. 6. 3D reconstruction of complex scapula fracture.

studies, fat and medullary bone are hyperintense (white), articular cartilage intermediate (grey) and fibrocartilage, tendons, ligaments and cortical bone hypo-intense (black). On T2 studies, pathology is often hyperintense (white) and tissue suppression studies (e.g. STIR) are used to differentiate pathology from normal anatomy. Contrast (gadolinium) is often given to demonstrate active synovial disease.^{2,5} Recent advances are high-strength magnets (1.5 Tesla plus), high-strength open tunnel magnets (1 Tesla) and dynamic MRI. Open magnet systems are more patient-friendly and decrease claustrophobia. Easier and alternative positioning is achieved and interventional techniques are possible. Specialised coils (e.g. shoulder and wrist) make optimal studies possible. MR of the knee shows injuries of the cruciate ligaments, menisci and collateral ligaments optimally.⁸ MR-arthrography is the examination of choice in evaluation of subtle shoulder pathol-

ogy of the rotator cuff, glenoid labrum, acetabular labrum⁹ and glenohumeral ligaments.^{2,5} It is also the definitive non-invasive modality of choice in assessing many other musculoskeletal conditions and in most instances has replaced or reduced the role of invasive arthroscopy as a diagnostic tool (Figs 7 and 8).¹⁰

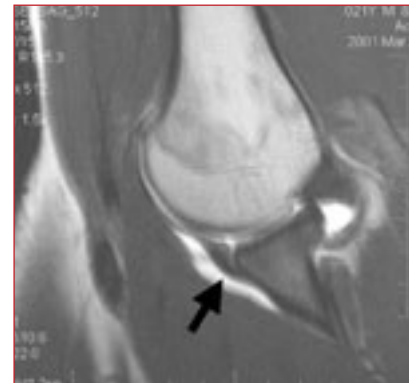


Fig. 7. MRI arthrogram demonstrating a Bankart lesion of the glenoid labrum in a patient with recurrent shoulder instability.

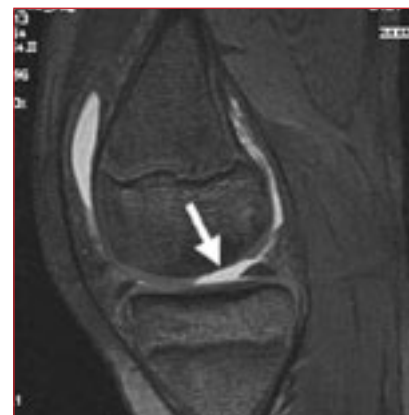

Fig. 8. MR of the knee showing full-thickness chondral fracture of the medial femoral condyle. Note intact cartilage on both sides of the defect.

Radio-isotope studies

Indicated in injuries where the source of the pain is vague or multiple in nature as it has 100% sensitivity for bony injury. Nuclear medicine studies demonstrate functional abnormalities by assessing increased blood flow or radioactive tracer uptake in abnormal tissue (Fig. 9). The examination is extremely sensitive, but not specific for disease. Correlation with the clinical picture and other imaging modalities is important for the correct conclusion.

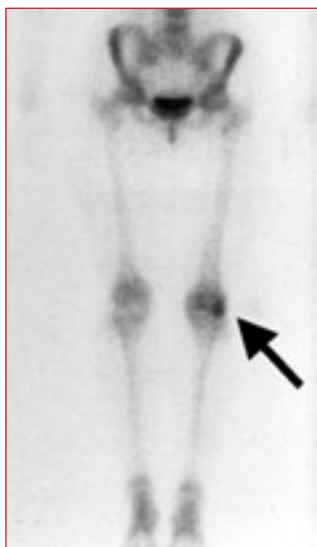

Fig. 9. Isotope bone scan demonstrating increased uptake in the lateral femoral condyle.

Often CT or MRI is required to grade the bony injury. Isotope studies are commonly used for the diagnosis of stress and occult fracture, infection and enthesopathy.^{2,5}

Angiography

Angiography is rarely used, but has a role in the diagnosis of claudication in the athlete. Possible causes such as intimal hyperplasia, intimal cysts or popliteal artery entrapment syndrome can be diagnosed. Interventional procedures, e.g. balloon angioplasty, can treat certain causes of claudication.^{2,5}

APPROACH TO IMAGING

Bone injury

This sequence of investigation of bone/joint sports injuries is suggested. An initial X-ray is followed up by re-X-ray 2 - 3 weeks later if there is no improvement. MRI and isotope studies can be performed if clinical findings are vague. Either MRI or CT is used for accurate grading. This protocol is the key to diagnosing and managing difficult bone and joint injuries, the most common application being osteochondral injuries of the dome of the talus (ankle mortise) with an incidence of 10% in ankle ligament sprains.

Osteochondral fracture of the medial talar dome should especially be suspected if a joint injury does not heal with correct treatment and time (Fig. 10).²

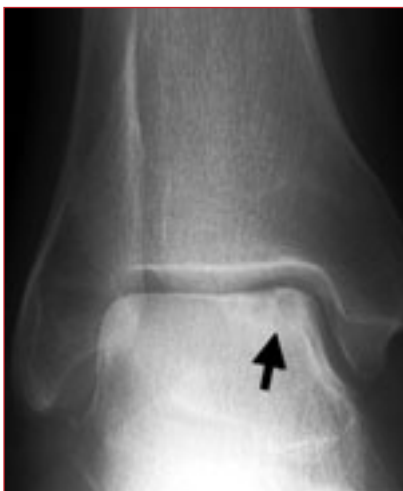

Fig. 10. Osteochondral fracture of the medial talar dome.

Joint injuries

An effusion is a sign of intra-articular injury. In the knee there is distention of the suprapatellar bursa. The elbow demonstrates elevation of the anterior and posterior fat pads (Fig. 11).⁵

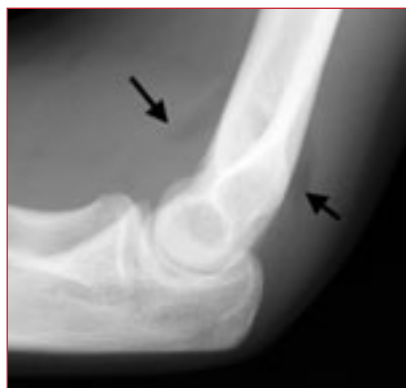

Fig. 11. Elevation of anterior and posterior fat pads indicating a joint effusion.

Ligament injury

X-rays may show indirect evidence of ligamentous injury by demonstrating soft-tissue swelling. Ultrasound demonstrates superficial ligaments, e.g. anterior talofibular ligament of the ankle, while MRI demonstrates deeper ligaments, e.g. anterior cruciate ligament of the knee (Fig. 12).

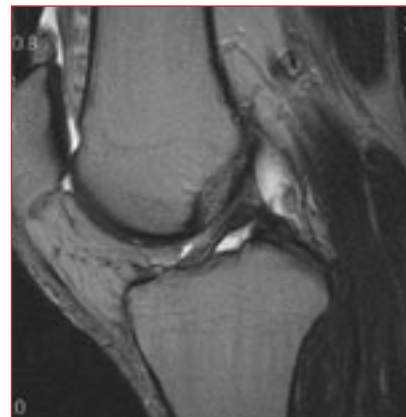


Fig. 12. MRI of the knee shows normal anterior cruciate ligament.

Interestingly, ankle ligament stress views should not be routinely requested, unless the clinician is uncertain as to whether there is laxity or not.²

Muscle strain/tear

These injuries are evaluated with high-resolution ultrasound, but subtle muscle strains may be missed. MRI is the gold standard for evaluating these injuries (Fig. 13). Complications like haematomas and abscesses are well seen on ultrasound. A long-term complication, myositis ossificans, may be seen on X-rays.²

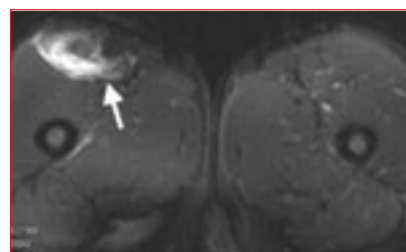


Fig. 13. MRI of both quadriceps muscles showing grade 2 tear of right rectus femoris muscle.

Overuse injuries

These injuries are due to repetitive micro-trauma.

Bone stress injury

This injury is often not visible on X-rays and may need ultrasound to show periosteal elevation. Isotope studies and/or MRI make the diagnosis. If uncertain of the origin of the pain, isotope studies are suggested to localise the injury and MRI is used to grade. If clinically accurately assessed, go to MRI.

Stress fractures occur commonly at the following sites:

- pars interarticularis — gymnastics, ballet, cricket fast bowling
- pubic ramus — distance running and ballet
- femur neck — distance running, ballet and jumping
- femur shaft — distance running
- tibial plateau — running
- tibial shaft — running and ballet
- fibula — running, ballet, aerobics
- medial malleolus — running
- calcaneus — long-distance walking
- navicula — running
- metatarsals — running and walking
- sesamoid bones of foot — running (Fig. 14).

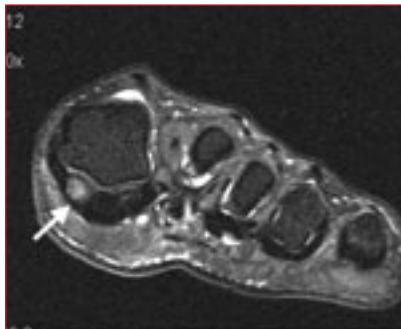


Fig. 14. MRI of the sesamoids showing bone marrow oedema of the medial sesamoid compatible with a bone stress injury.

The most commonly affected bones are the tibia, metatarsals, fibula, navicular, neck of femur and pelvis. Although often easy to localise, sometimes stress fractures can present with vague pain either proximal or distal to the fracture site, e.g. tibial stress fracture may present with upper femur pain. In such cases, isotope studies are most useful. Another useful cost-effective follow-up assessment is the plain film repeated 2 - 3 weeks later, which may then show up a periosteal reaction. Certain stress fractures, such as tarsal navicular stress fractures, are best evaluated and followed up by CT where it is very important, as with scaphoid fractures, to define the bony extent of the fracture as well as to assess bony union.¹⁰

Osteitis and periostitis

Osteitis, e.g. pubic symphysis, namely osteitis pubis, is inflammation of the

bone. Chronic changes can be seen on plain film. Pelvic instability views (flamingo or single leg standing view) may help in determining the cause — greater than 3 - 5 mm displacement plane is abnormal (Fig. 15).

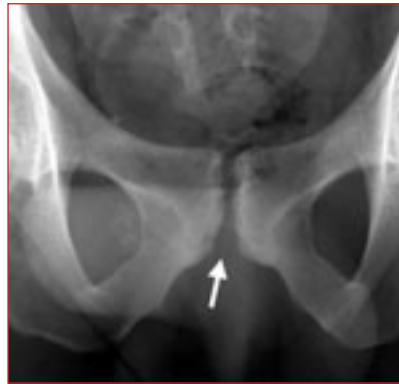

Fig. 15. Erosions and sclerosis of pubic symphysis joint compatible with osteitis pubis.

Periostitis refers more to inflammation of bone at muscle/tendon attachment sites. Most commonly periostitis is tibial (shin splints) in origin. As opposed to a focal area of bony abnormality in stress fractures, periostitis typically occurs over a diffuse area best seen in isotope studies although in severe chronic cases subtle X-ray changes may be noticeable. Ultrasound, although operator-dependent, is also a useful diagnostic modality.²

The classic triad of tibial periostitis, stress fractures and deep post-traumatic compartment syndrome can be difficult to diagnose and often some or all three co-exist. Deep posterior compartment syndrome is best diagnosed by invasive component pressure studies.

Another diagnosis to consider in this region is skin pain due to popliteal vascular entrapment syndrome. Vascular ultrasound is very useful. It is important to know that more than 50% of people compress their popliteal artery in active plantar flexion, but the vessel should remain in its position and not deviate. MRI is useful in defining the aberrant course of popliteal arteries. There are a number of well-documented anatomical variants that need to be considered. Deviation is due to muscular bands, e.g. medial

head of gastrocnemius pulling the artery medially on active plantar flexion. Once confirmed non-invasively, and the benefits of surgery outweigh the risks, invasive angiography is indicated.

There are other causes of vascular symptoms in the lower limbs such as popliteal artery cysts, atherosclerosis and aneurysms.

In athletes with vascular-type symptoms of the lower limbs, assessment of iliac and femoral vessels is important as stenosis in this region is the most common cause of calf/shin pain. In young athletes, especially cyclists, intimal thickening of the external iliac artery is an important diagnosis. It is confirmed non-invasively by colour-flow Doppler and angiographically if open surgery or angioplasty is the decided treatment. Once again, atherosclerosis is the most common cause for exercise-induced vascular symptoms in older athletes.¹⁰

Apophysitis and enthesitis

Bony inflammation and bony separation may occur at the attachment of strong, large tendons to the growth areas of children's bones. Examples include Sever's disease (calcaneal apophysitis) and Osgood Schlatter's disease (tibial apophysitis). Other sites of occurrence are the distal patella (Sinding-Larsen-Johannson syndrome), anterior-inferior iliac spine (rectus femoris), anterior-superior iliac spine (sartorius), ischial tuberosity (hamstring) (Fig. 16), lesser trochanter (iliopsoas).

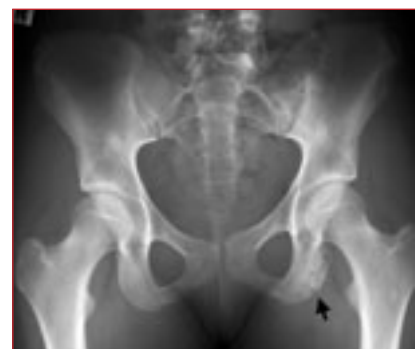

Fig. 16. Ischial apophysitis due to chronic hamstring traction stress.

The range of radiological imaging modalities available today allows accurate assessment of acute and chronic injuries to bone, articular cartilage, joints, ligaments, tendons, muscles, bursae and nerves.

The importance of demonstrating the soft tissues is important to evaluate subtle calcification, bone flakes, periosteal reaction and muscle/tendon insertions.

Always keep in mind that an apophysitis may mimic a bone tumour as the radiological appearance may be similar.²

In adults navicular enthesitis may be caused by traction of tibialis posterior tendon at its medial attachment to the navicula. This condition is often associated with an accessory navicular bone or a prominent navicular tuberosity. Plain films usually suffice, but in difficult cases, particularly adults, ultrasound and MRI are sometimes necessary to differentiate tendinopathy from bony injury.¹¹

THE YOUNGER ATHLETE

The most obvious difference between the skeleton of a child and that of an adult is the degree of skeletal maturity. This is manifested radiographically by the presence of an epiphyseal ossification centre that is separated from the metaphysis by a band of unossified cartilage, the physis. The classification most widely used to classify fractures involving the physis is that described by Salter and Harris (Fig. 17). Five basic types are described. Recognising the different types is important for proper treatment and determination of prognosis. The prognosis is best for type II and worst for type V, which causes premature growth-plate fusion.³

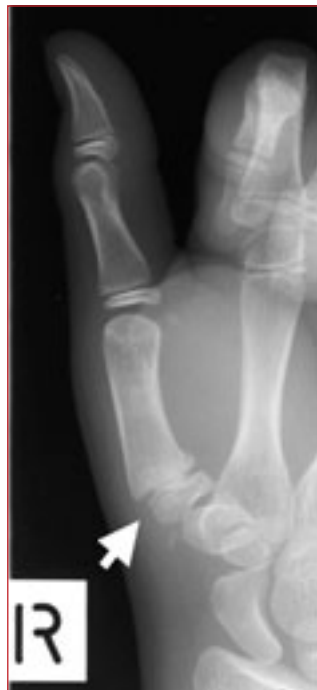

Fig. 17. Salter-Harris fracture of the growth plate of the base of the 1st metacarpal.

Because the growing skeleton is more elastic than the adult skeleton, paediatric fractures often do not extend completely through the entire circumference of a bone. This can produce a greenstick, torus, or bowing fracture. Greenstick fractures show disruption of the cortex on the side of the bone undergoing tensile forces, whereas the opposite cortex undergoing compression remains intact. Torus fractures have a similar mechanism of action, but it is the compressive force that causes a buckling of the cortex. Bowing, or plastic, fractures are subtle microscopic fractures, showing only a bowed or bent appearance, with the cortices radiographically intact.¹²

Acknowledgements

Professor Alan Scher, Dr Jock Anderson and Drs Van Wageningen and Partners for images supplied. Professors Derman, Noakes and Schwellnus of the SA Sports Science Institute for clinical input.

References available on request.

IN A NUTSHELL

The recent advances in high-quality radiography, high-resolution ultrasound, helical multi-slice CT and high field strength MRI, have been able to demonstrate the musculoskeletal system as never before.

Image quality is of the utmost importance as pathology may be missed on poor-quality radiographs.

Stress views are only indicated if one is clinically uncertain of ligamentous injury and comparison with the uninjured side is important.

Shoulder ultrasound is well-established as the primary diagnostic tool in the management of rotator cuff injury.

CT is the examination of choice for bone pathology.

With MRI, T1-weighted images generally display anatomy optimally, while T2-weighted images display pathological conditions in broad terms.

Nuclear medicine isotope imaging is extremely sensitive, but not specific for disease.

An effusion is a sign of intra-articular injury.

Bony inflammation and bony separation may occur at the attachment of strong, large tendons to the growth areas of children's bones.

The classification most widely used to classify fractures involving the physis is that described by Salter and Harris.