

Case Report

Non-Puerperal Uterine Inversion Following a Prolapsed Leiomyoma in a Cameroonian Woman

F. Fouelifack Ymele,¹ P. Nana,^{1,2} J. H. Fouedjio,^{1,2} E. Bechem,² and R. E. Mbu^{1,2}

¹Obstetrics and Gynaecology Unit, Central Hospital of Yaounde, P.O. Box 31186, Yaounde, Cameroon

²Department of Obstetrics & Gynaecology, Faculty of Medicine and Biomedical Sciences, University of Yaounde I, P.O. Box 1365, Yaounde, Cameroon

Address correspondence to F. Fouelifack Ymele, yfouelifack@yahoo.fr

Received 18 June 2011; Accepted 4 July 2011

Abstract Non-puerperal uterine inversion is a rare condition that occurs as a complication of intrauterine tumors, especially giant submucosal leiomyomas. This condition can cause severe pain and hemorrhage. Management can consist of manual repositioning through the cervical ring, or surgical corrective measures. We report here a case of uterine inversion following the prolapse of a submucosal leiomyoma, managed by laparotomy. We also discuss alternative therapeutic approaches.

Keywords uterine inversion; non-puerperal; leiomyoma

1 Introduction

Inversion of the uterus is a rare condition that occurs usually in early post partum [1]. This is associated with poor obstetrical practices. Non-puerperal uterine inversion is an exceptional condition affecting mostly women with intrauterine tumors like polyps and leiomyomas. These conditions that are frequent in African women [1]. We are presenting the case of uterine inversion following a prolapsed submucosal leiomyoma in an African woman.

2 Case presentation

A 34-year-old married woman, G₂P₁010, consulted in our service for lower abdominal pains, per vaginal bleeding and a vaginal mass. These symptoms started a week before her consultation with a sudden onset of mild dark red vaginal bleeding and lower abdominal pains. The symptoms aggravated the day of her consultation by a sensation of a foreign body in her vagina that protruded through the introitus. She had a history of myomectomy 5 years ago. A year before, she was hospitalized for severe management of anemia following heavy vaginal bleeding. She was diagnosed with uterine fibroids but refused myomectomy for financial reasons.

On physical examination, she was pale. Her pelvic exam revealed a dark red solid mass of about 7 cm attached to

a second smooth bluish red mass (Figure 1). Neither the cervix nor the uterus could be identified by bimanual palpation. The rest of physical examination was not contributive.

A pelvic ultrasound was done. The findings were as follows: uterus with a submucosal fibroid of 77 mm by 35 mm, with probable inversion of the uterus, prolapsed into the vagina.

Her hemoglobin level was 7.6 g/dl, and she was transfused 4 units of packed cells. Otherwise, she was HIV negative, and her pre-operative work up was normal.

We performed a vaginal myomectomy; the fibroid weighed 300 g, but could not correct the uterine inversion vaginally through the cervical ring. A laparotomy was done immediately and the inversion was easily corrected through an anterior vertical incision on the uterus.

She had an uneventful post-operative period, and was discharged after 5 days. Histology of the tumor revealed a necrotic leiomyoma. Two months after surgery, she is alive and free of complications.

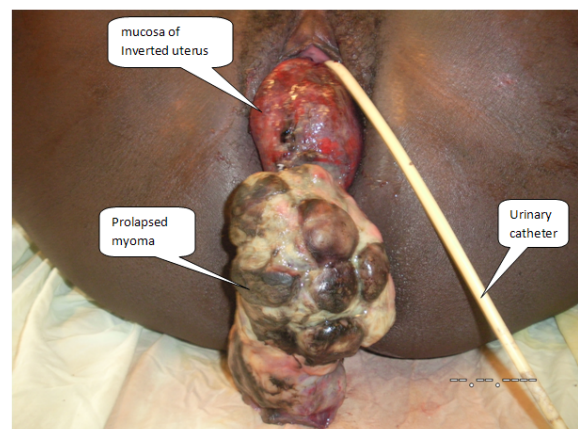


Figure 1: The prolapsed submucosal myoma on the inverted uterus.

3 Discussion

Uterine inversion refers to a descent of the uterine fundus to or through the cervix, so that the uterus is turned inside out. Uterine inversion is a rare affection that occurs usually as a complication of deliveries [1]. Non-puerperal inversion is extremely rare, representing about one sixth of all inversions [8]. Non-puerperal inversions are usually caused by intrauterine tumors. Mwinyoglee et al. reported that 97.4% of uterine inversions are associated with tumors, out of which 20% were malignant [11], while Takano et al. reported that 71.6% of cases of uterine inversion are associated with leiomyomas [14]. Leiomyomas are common in African women [2, 10, 16] as was with the case of our patient. Risk factors for uterine inversion may include fundal attachment of tumor, thickness of the tumor pedicle, tumor size, thin uterine wall and dilatation of the cervix [9] as was the case with our patient.

Uterine inversions can be classified as follows: stage 1: the inverted fundus remains in the uterine cavity, stage 2: complete inversion of the fundus through the cervix, stage 3, the inverted fundus protrudes through the vulva, stage 4: inversion of the uterus and the vaginal wall through the vulva [13]. Non-puerperal inversion can also be classified into acute and chronic uterine inversions. Our patient presented with a stage 3 inversion.

Acute uterine inversion causes severe pain and hemorrhage whereas chronic inversion is insidious and characterized by pelvic discomfort, vaginal discharge, irregular vaginal bleeding and anemia. The diagnosis is easier with a stage 3 or 4 disease when a bluish-red mass is identified from the vulva. In other cases, the diagnosis can be difficult and the use of ultrasound or computer tomography [13] can be used.

Repositioning of the uterus is usually done after the tumor has been removed. In-depth investigations are required to identify malignant tumors. Manual repositioning through the vagina was described by Johnson [7] and is possible with acute inversions. Saline hydrostatic pressure positioning was also described by O'Sullivan and modified by Oguey and Ayida [12]. In chronic uterine inversions, surgery is imperative. Depending on the clients reproductive desire and associated conditions, surgical reposition or hysterectomy could be considered. Spinell and Kustner [3] are similar trans-vaginal surgical reposition techniques with the basic differences being that Spinell's approach is anterior and requires dissection of the bladder and an anterior uterine wall incision, while Kustner's is a posterior approach with incision on the posterior uterine wall, which makes it a bit easier and safer [3].

Surgical repositioning can also be done through a laparotomy using the Huntington procedure, which consists in locating the cup of uterus formed by the inversion, dilating the cervical ring digitally, and gentle upward

traction of the round ligaments of the uterus [6]. The Haultaim procedure uses a vertical incision in the post portion of the ring (which ring) and gentle traction on the round ligaments [4]. We used an anterior vertical incision for our patient because we found it to be easier, with a lower likelihood of adhesions.

Uterine inversion has a good prognosis when managed in a timely correct manner. Subsequent pregnancies should be monitored closely especially if an anterior vertical incision or the Haultaim procedure was used for repositioning [15].

4 Conclusion and recommendation

Non-puerperal uterine inversion, although it is a rare condition, can be fatal to the patient [5]. Most cases occur following intrauterine tumors especially leiomyomas. Repositioning can be done vaginally or through laparotomy.

We recommend to practitioners that patients with giant intrauterine tumors should be well counseled for surgery to prevent this complication.

References

- [1] T. F. Baskett, *Acute uterine inversion: a review of 40 cases*, J Obstet Gynaecol Can, 24 (2002), 953–956.
- [2] D. Day Baird, D. B. Dunson, M. C. Hill, D. Cousins, and J. M. Schectman, *High cumulative incidence of uterine leiomyoma in black and white women: ultrasound evidence*, Am J Obstet Gynecol, 188 (2003), 100–107.
- [3] C. Fofie and P. Baffoe, *Non puerperal uterine inversion: a case report*, Ghana Med J, 44 (2010), 79–81.
- [4] F. Haultain, *The treatment of chronic uterine inversion by uterine hysterotomy*, BMJ, 2 (1901), 974–980.
- [5] D. R. Hostetler and M. F. Bosworth, *Uterine inversion: a life-threatening obstetric emergency*, J Am Board Fam Pract, 13 (2000), 120–123.
- [6] J. L. Huntington, *Abdominal reposition in acute inversion of the puerperal uterus*, AM J Obstetr Gynaecol, 15 (1928), 34–40.
- [7] N. K. Kochenour, *Intrapartum obstetric emergencies*, Crit Care Clin, 7 (1991), 851–864.
- [8] R. A. Krenning, *Nonpuerperal uterine inversion. Review of literature*, Clin Exp Obstet Gynecol, 9 (1982), 12–15.
- [9] E. Lascarides and M. Cohen, *Surgical management of non-puerperal inversion of the uterus*, Obstet Gynecol, 32 (1968), 376–381.
- [10] A. B. Moore, G. P. Flake, C. D. Swartz, G. Heartwell, D. Cousins, J. K. Haseman, et al., *Association of race, age and body mass index with gross pathology of uterine fibroids*, J Reprod Med, 53 (2008), 90–96.
- [11] J. Mwinyoglee, N. Simelela, and M. Marivate, *Non-puerperal uterine inversions. A two case report and review of literature*, Central African J Med, 43 (1997), 268–271.
- [12] O. Oguey and G. Ayida, *Acute uterine inversion: a new technique of hydrostatic replacement*, Br J Obstet Gynaecol, 104 (1997), 951–952.
- [13] C. G. Salomon and S. K. Patel, *Computed tomography of chronic nonpuerperal uterine inversion*, J Comput Assist Tomogr, 14 (1990), 1024–1026.
- [14] K. Takano, Y. Ichikawa, H. Tsunoda, and M. Nishida, *Uterine inversion caused by uterine sarcoma: a case report*, Jpn Clin Oncol, 31 (2001), 39–42.

-
- [15] P. Tank, N. Mayadeo, and S. Nandanwar, *Pregnancy outcome after operative correction of puerperal uterine inversion*, Arch Gynecol Obstet, 269 (2004), 214–216.
- [16] L. A. Wise, J. R. Palmer, Y. C. Cozier, M. O. Hunt, E. A. Stewart, and L. Rosenberg, *Perceived racial discrimination and risk of uterine leiomyomata*, Epidemiology, 18 (2007), 747–757.