

Quercetin Ameliorates Zinc Oxide Nanoparticles-induced Impaired Testicular Functions by Regulating Inflammation, Oxidative, and Hormonal Status

Oghenetega OB¹[ID](#), Oyovwi MO²[ID](#), Obidimma CE¹[ID](#), Ijabodede TV¹[ID](#), Oghenetega EG³[ID](#), Okwute PG¹[ID](#), Kpai T⁴[ID](#), Oluwatunase GO⁵[ID](#), Adeoye AD¹[ID](#), Abraham TF⁶[ID](#), Ugwuishi EW⁷[ID](#)

¹Department of Physiology, School of Basic Medical Science, Babcock University, Ilishan-Remo, Ogun State

²Department of Physiology, Adeleke University, Ede, Osun State, Nigeria

³Department of Biochemistry, School of Basic Medical Science, Babcock University, Ilishan-Remo, Ogun State

⁴Department of Human Kinetics, Health and Safety Education, Ignatius Ajuru University of Education, Port Harcourt, River state

⁵Department of Anatomy, University of Medical Sciences, Ondo, Ondo State

⁶Departamento de fisiologia e farmacologia, Instituto de Ciencias Biologicas, Universidade Federal de Minas Gerais, Belo Horizonte, Minas Gerais, Brasil

⁷Department of Physiology, College of Medicine, Enugu State University, Enugu, Nigeria

Submitted: 1st January 2024

Accepted: 29th May 2024

Published:

[ID](#): Orcid ID

Abstract

Objective: Zinc oxide nanoparticles (ZnO NPs) have various applications, but concerns about their potential adverse effects on human health, particularly the male reproductive system, have led to toxicity. This study investigates the effects of quercetin, a natural compound with anti-oxidative and anti-inflammatory properties, on ZnO NP-induced testicular toxicity in male Swiss mice.

Method: In this study, 25 male mice were randomly allocated into 5 groups, each consisting of 5 mice (n=5). The groups were labelled as Control, Corn Oil, Quercetin, ZnO NPs, and ZnO NPs + Quercetin. The dosages administered were 100mg/kg for ZnO NPs and 20mg/kg for quercetin, relative to the weight of the animals. The treatments were conducted for 7 days following a two-week acclimatization period.

Results: Zinc oxide nanoparticles (ZnO NPs) were found to increase testicular TNF- α , indicating inflammation at the testes which may have resulted in a significant decrease in testosterone. Malondialdehyde (MDA), an oxidative stress marker was also found to be increased at the level of the testes, in the ZnO NPs group when compared to the control group. Treatment with quercetin, however, was able to reduce the levels of inflammatory and oxidative stress markers at the testes, and restore testosterone to control levels, demonstrating its potential ameliorative effects on testicular toxicity via anti-inflammatory and anti-oxidative properties.

Conclusion: The findings from this study indicated that Quercetin is a potential therapeutic agent against inflammation and oxidative stress in ZnO NPs-induced testicular toxicity.

Keywords: Zinc Oxide Nanoparticles, Quercetin, Inflammation, Oxidative stress, Testes

Correspondence:

Oghenetega, Onome B

Department of Physiology, School of Basic Medical Science,

Babcock University, Ilishan-Remo,

Ogun State, Nigeria.

+2348165148214, tegabonome@gmail.com

Plain English Summary

This study looks at how quercetin, a natural substance that fights free radicals and inflammation, affects the testicular toxicity caused by Zinc Oxide nanoparticles (ZnO NPs) in male Swiss mice. Twenty-five male mice were randomly put into five groups of five mice each. Control, Corn Oil, Quercetin, ZnO NPs, and ZnO NPs + Quercetin were the names of the groups. The amounts given were 100 mg/kg for ZnO NPs and 20 mg/kg for quercetin, based on the weight of the animals for seven days.

The results showed that zinc oxide nanoparticles raised testicular TNF- α levels. This means that the testes were inflamed, which may have caused the major drop in testosterone. Malondialdehyde (MDA), a sign of oxidative stress, was also found to be higher in the testes of the ZnO NPs group compared to the control group. However, treatment with quercetin was able to lower the levels of inflammatory and oxidative stress markers in the testes and bring testosterone levels back to normal. This study showed that quercetin may be able to help treat inflammation and oxidative stress in testicular damage caused by ZnO nanoparticles.

Introduction

Nanoparticles (NPs) are materials with dimensions between 1 to 100nm, offering unique properties like optical, reactivity, and toughness (1). They are suitable for various commercial, industrial, and domestic applications, including catalysis, imaging, medical, energy-based research, and environmental applications (1). Zinc oxide, a prominent metal nanoparticle, is increasingly common due to its unique properties in various industries (2). However, the increasing use of zinc oxide in consumer products increases the risk of exposure due to contamination from industrial processes and their easy entry into the systemic circulation through respiratory, gastrointestinal, and dermal pathways (3). These nanoparticles can cause toxicity in the reproductive system by disrupting sex hormone production, leading to oxidative stress, inflammation, DNA damage and cell death or apoptosis (4, 5).

Oxidative stress is a condition where the body's ability to detoxify or repair cellular damage is disrupted by the generation of reactive oxygen species (ROS), which are by-products of cellular metabolism (6). The testes, due to their high metabolic activity, lipid content, and reliance on unsaturated fatty acids, are particularly susceptible to oxidative stress (7). When ROS production exceeds antioxidant defences, oxidative stress leads to lipid peroxidation, protein damage, and inflammation (7). Inflammation, a complex immune response, can also cause testicular toxicity (8, 9). Inflammation involves the infiltration of immune cells into testicular tissue, releasing pro-inflammatory cytokines like TNF- α and IL-1 β (10, 11). This can disrupt the normal testicular microenvironment, affecting spermatogenesis and causing oxidative stress. Chronic inflammation in the testes is associated with conditions like orchitis and epididymitis, which can result in testicular dysfunction and impaired sperm production (12). ZnO NP-induced increased testicular injury has been shown to induce oxidative stress and cytotoxicity in lab animals (5). In this scenario,

antioxidant supplementation with quercetin becomes essential, and quercetin therapy is becoming more and more popular for treating repro-toxicant-related repro-pathologies (13, 14, 15).

Quercetin, a naturally occurring compound abundant in a wide range of fruits, vegetables, and herbs, has garnered considerable attention for its multifaceted health-promoting attributes (16). Notably, it exhibits remarkable anti-inflammatory properties and demonstrates the ability to shield the body from the harmful effects of diverse agents, such as heavy metals, pesticides, and nanoparticles, as demonstrated in the study conducted by Ay et al. in 2021 (17). The innate duality of zinc oxide nanoparticles (ZnO NPs) as promising technological innovations and potential health hazards underscores the urgency of investigating protective measures against their deleterious effects. This study sets out to examine the promising potential of quercetin as a mitigating agent in the context of testicular toxicity, specifically due to oxidative stress and inflammation induced by ZnO NPs.

Materials and Methods

Experimental model

Twenty-five (25) healthy male mice (20-25g) obtained from the animal house, Babcock University were kept at the animal house, Babcock University, Ilishan-Remo, Ogun State, Nigeria. The ethical approval for all handling of animals and protocols for the experiment used in the study was obtained from the Babcock University Health Research Ethics Committee, and this adheres to the international guidelines for using laboratory animals outlined in the Helsinki Declaration.

Animal care

The mice were housed at an average room temperature of 23 °C, with a relative humidity of 55% and a 12 h light / 12 h dark cycle and provided a standard diet and drinkable tap water ad libitum. The animals were acclimatized for two

weeks at the animal house of the Department of Physiology, Babcock University.

Experimental design

Twenty-five (25) male Swiss mice were allocated into five groups (n = 5). The treatment group include the Control group (0.2mL of distilled water), the Corn Oil group (0.2mL of corn oil), Quercetin (20mg/kg), Zinc Oxide Nanoparticles (100mg/kg), Zinc Oxide Nanoparticles + Quercetin (100mg/kg+20mg/kg). The vehicles for the administration of Quercetin and Zinc Oxide nanoparticles were corn oil and distilled water respectively. The treatments were administered via oral cannula for seven days after 14 days of acclimatization.

Drug administration

Zinc oxide nanoparticles (ZnO NPs), quercetin, and corn oil were purchased from Sigma Aldrich, St. Louis, USA, Central Drug House (CDH) Limited, New Delhi, India, and Babcock Superstore, Ogun State, Nigeria respectively.

Physicochemical characterisation of Zinc Oxide nanoparticle

The dispersion protocol, morphology, and size distribution of Zinc Oxide Nanoparticles have been documented in our previous studies (18). The dispersion procedure and morphology assessment of Zinc nanoparticles were conducted in adherence to the methodology outlined by Georgantzopoulou et al. (2016) (19). Utilizing dynamic light scattering (DLS), the particle size distribution, zeta potential, and polydispersity indexes of ZnO NPs were determined, as detailed in the study by Cambier et al. (2018) (20).

Sample collection

After one week of treatment, blood was collected from each animal under ether anaesthesia through the retro-orbital sinus and centrifuged at 3000rpm for 15 minutes. The sera collected were used for hormonal analysis using the Enzyme-linked immunosorbent assay (ELISA) technique, and the animal was euthanized via cervical dislocation. The reproductive organs were extracted, separated from adhering tissues, and weighed using an electronic scale. The testes and epididymis were dissected for sperm analysis, biochemical assays, immunoassays, and histological examinations.

Biochemical assays

Malondialdehyde (MDA) assay was performed using the method described by Wallin et al. (21). The interaction of Malondialdehyde, a byproduct of lipid peroxidation, with thiobarbituric acid, produces a red species detectable at 535 nm.

Superoxide Dismutase (SOD) was performed using Misra and Fridovich's (22) technique. The principle is based on the rapid auto-oxidation of the presence of superoxide anions, adrenaline in aqueous solution converts to adrenochrome. A spectrophotometer set to 420 nm was used to measure the concentration. Catalase (CAT) was determined using Aebi's (23) technique. Catalase (CAT) activity was measured as a reduction in H₂O₂ absorbance at 520 nm. Total antioxidant capacity (TAC) and reduced glutathione (GSH) were the methods by Ellman (24) and Degraft-Johnson (25) respectively. The Colorimetric method was used in the determination of testicular zinc levels using kits (Fortress Diagnostics Limited, United Kingdom).

Hormonal and testicular TNF- α assay

The Enzyme-linked immunosorbent assay (ELISA) technique was used to determine serum testosterone, luteinizing hormone, follicle-stimulating hormone and testicular tumour necrotic factor-alpha using kits (Calbiotech Inc. California). The procedures for the estimation of testosterone, luteinizing hormone and follicle-stimulating hormone were carried out according to the manufacturer instructions in the kits' manual.

Semen analysis

Sperm motility

The sperm motility was performed immediately following the collection of epididymal fluid using Zemjanis' (26) traditional technique. After dropping the epididymal fluid onto the slide, two drops of warm 2.9% sodium citrate were added to it. This was covered with a cover slip and examined under the microscope using an X40 objective in low light.

Sperm viability

The Eosin/Nigrosin stain was used for this examination. The epididymal sperm motility specimen was retrieved and the coverslip was rapidly removed. Two drops of Eosin/Nigrosin stain were applied to this, and a smear was produced and air-dried. The slides were observed under a microscope with an X40 objective. The live sperm cells were unstained; however, the dead sperm cells did. The % live/death ratio was calculated by counting 100 cells per slide (26).

Sperm count

The caudal epididymis was excised and homogenized in 5ml of normal saline, and the volume change was measured. Sperm count was determined using an improved Neubauer counting chamber. The counted sperm was expressed in million/ml suspension.

Histopathological examination of testes

The testis and hypothalamus were fixed in 10% buffered formalin, embedded in paraffin wax, and sectioned at 3m. Sections were stained with Hematoxylin and Eosin (H&E) stain and mounted on slides for light microscopic inspection. To eliminate bias, the slides were reviewed by a histopathologist who was unaware of the treatment groups.

Statistical analysis

The data was expressed as Mean ± standard error of the mean (SEM). Analysis was carried out using one-way analysis of variance (one-way ANOVA) followed by the Bonferroni post hoc test

for multiple comparisons in GraphPad Prism version 8 software. p < 0.05 was considered significant.

Results

The Effects of Zinc Oxide Nanoparticles and Quercetin on Testicular Zinc Levels

The results indicated a significant increase in zinc levels found in the testes of the nanoparticles group when compared to the negative control (p<0.001) as shown in Figure 1. Furthermore, Quercetin was also found to have mitigated the increased testicular zinc levels with a significant decrease in testicular zinc levels compared to the nanoparticles group (p<0.05).

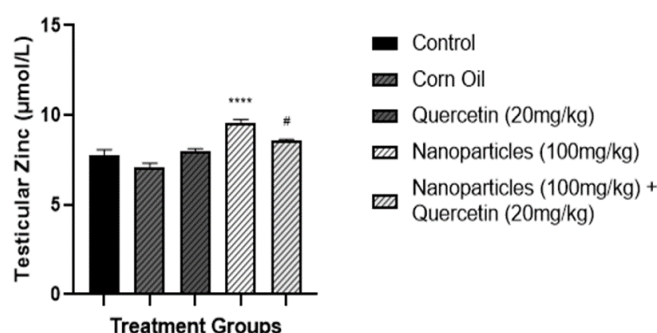


Figure 1: The effects of nanoparticles and quercetin on testicular zinc levels

Data were expressed as Mean ± S.E.M (n = 5) and One-way ANOVA followed by the Bonferroni post hoc test was used for data analysis. ****p <0.0001 when compared with Control; #p < 0.05 when compared to Nanoparticles Group

The Effects of Zinc Oxide Nanoparticles and Quercetin on Testicular MDA Concentration

The result of this present study as shown in Figure 2 showed a significant increase in MDA concentration in the Zinc Oxide nanoparticles

(ZnO NPs) group when compared to the control group. However, in the Nanoparticle+Quercetin group, there was a significant reduction in the mean testicular MDA concentration when compared to the Nanoparticle treatment group.

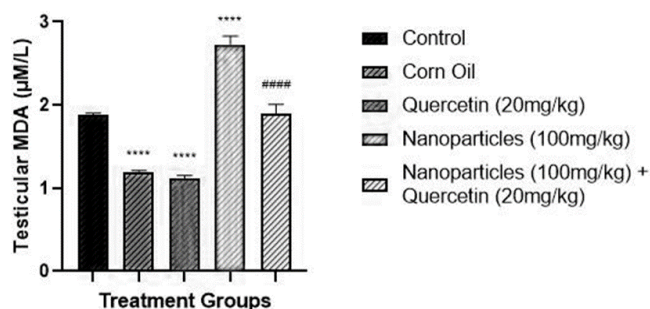


Figure 2: The effects of zinc oxide nanoparticles and quercetin on testicular malondialdehyde (MDA) concentration

Data were expressed as Mean ± S.E.M (n = 5) and One-way ANOVA followed by the Bonferroni post hoc test was used for data analysis. ****p <0.0001 when compared with Control; ####p < 0.0001 when compared to Nanoparticles Group

The Effects of Zinc Oxide Nanoparticles and Quercetin on Testicular Superoxide Dismutase (SOD) Concentration

The result as shown in Figure 3 showed that the nanoparticle treatment group showed a significant decrease in the mean testicular SOD

concentration when compared to the control group. Furthermore, the Nanoparticle + Quercetin treatment group when compared to the Nanoparticle treatment group showed a significantly higher mean testicular SOD concentration.

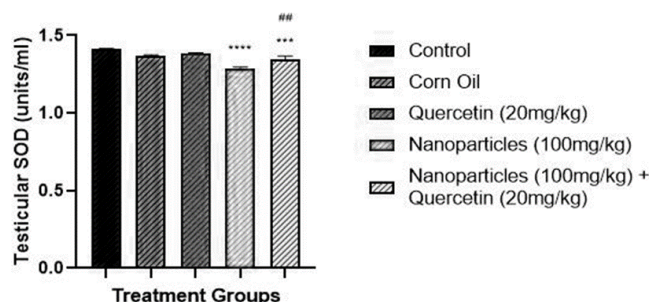


Figure 3: The Effects of Zinc Oxide Nanoparticles and Quercetin on Testicular Superoxide Dismutase (SOD) concentration

Data were expressed as Mean ± S.E.M (n = 5) and One-way ANOVA followed by the Bonferroni post hoc test was used for data analysis. ****p <0.0001 when compared with Control; ##p < 0.01 when compared to Nanoparticles Group

The Effects of Zinc Oxide Nanoparticles and Quercetin on Testicular Catalase (CAT) Concentration

The result as shown in Figure 4 showed the mean testicular Catalase (CAT) concentration was significantly lower in the Nanoparticle

treatment group when compared to the control group. Furthermore, there was no significant difference in the mean testicular Catalase (CAT) concentration between the Nanoparticle and the Nanoparticle + Quercetin treatment groups.

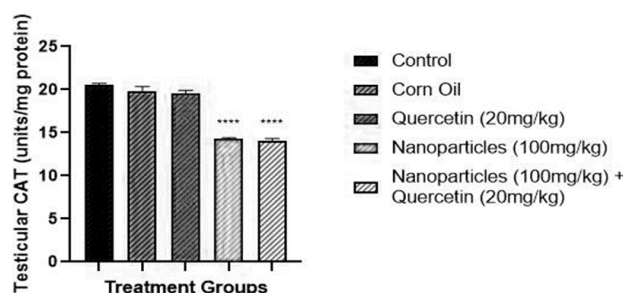


Figure 4: The Effects of Zinc Oxide Nanoparticles and Quercetin on Testicular Catalase (CAT) Concentration

Data were expressed as Mean ± S.E.M (n = 5) and One-way ANOVA followed by the Bonferroni post hoc test was used for data analysis. ****p <0.0001 when compared with Control

The Effects of Zinc Oxide Nanoparticles and Quercetin on Testicular Glutathione (GSH) Concentration

The result as shown in Figure 5 showed a significant decrease in mean testicular GSH in

the Nanoparticle treatment group when compared to the Control group. Furthermore, the Nanoparticle + Quercetin group did not show a significant difference when compared to the Nanoparticle only treated group.

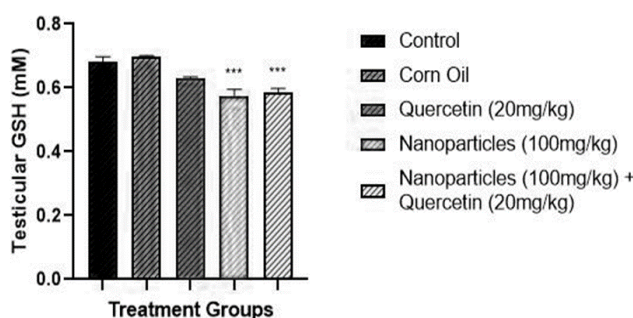


Figure 5: The Effects of Zinc Oxide Nanoparticles and Quercetin on Testicular Glutathione (GSH) Concentration

Data were expressed as Mean ± S.E.M (n = 5) and One-way ANOVA followed by the Bonferroni post hoc test was used for data analysis. ****p <0.0001 when compared with Control

The Effects of Zinc Oxide Nanoparticles and Quercetin on Testicular Total Antioxidant Capacity (TAC)

The result as shown in Figure 6, showed that the mean testicular Total Antioxidant Capacity (TAC) of the nanoparticle-treated group showed a significant decrease when compared to the

Control group. However, the Nanoparticle+Quercetin showed increased levels of the mean testicular Total Antioxidant

capacity (TAC) when compared to the Nanoparticle treatment group.

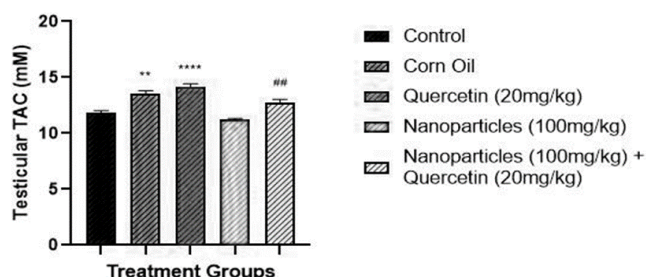


Figure 6. The Effects of Zinc Oxide Nanoparticles and Quercetin on Testicular Total Antioxidant Capacity (TAC)

Data were expressed as Mean ± S.E.M (n = 5) and One-way ANOVA followed by the Bonferroni post hoc test was used for data analysis. ****p <0.0001 when compared with Control; ##p < 0.01 when compared to Nanoparticles Group

The Effects of Zinc Oxide Nanoparticles and Quercetin on TNF-α

A significant increase in TNF-α was indicated in the nanoparticles group when compared to the control (p<0.0001) as illustrated in Figure 7,

however, quercetin was shown to ameliorate the effects of the nanoparticles as the co-administration group showed no significant difference in TNF-α when compared to the control group.

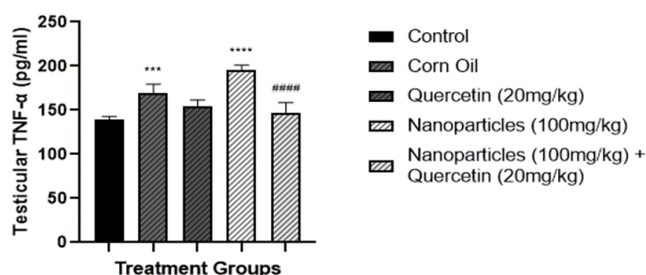


Figure 7: The effects of nanoparticles and quercetin on TNF-α

Data were expressed as Mean ± S.E.M (n = 5) and One-way ANOVA followed by Bonferroni post hoc test was used for data analysis ***p <0.001 when compared with Control; ****p <0.0001 when compared with Control; #####p < 0.0001 when compared to Nanoparticles Group

The Effects of Zinc Oxide Nanoparticles and Quercetin on Follicle-Stimulating Hormone

The results as illustrated in Figure 8 show no significant changes in serum FSH levels in both the nanoparticles group and the co-

administration group to the control group, as well as no significant alteration in serum FSH levels of the co-administration group when compared to the nanoparticles group.

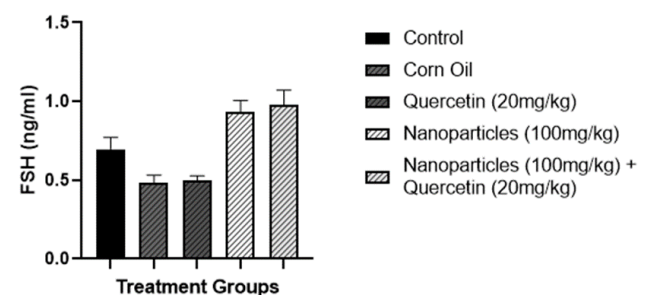


Figure 8: The effects of nanoparticles and quercetin on follicle-stimulating hormone

Data were expressed as Mean ± S.E.M (n = 5) and One-way ANOVA followed by the Bonferroni post hoc test was used for data analysis

The Effects of Zinc Oxide Nanoparticles and Quercetin on Luteinizing Hormone

The results as illustrated in figure 9 showed no significant difference among the groups when

compared to the control or the nanoparticle group.

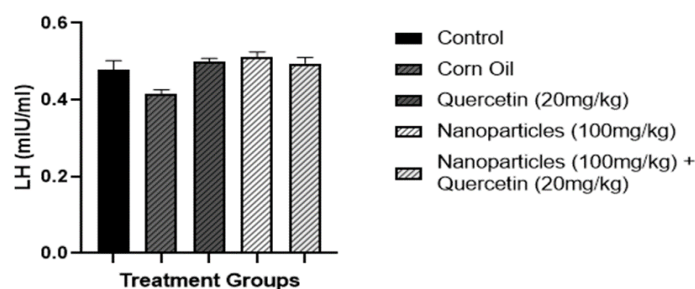


Figure 9: The effects of nanoparticles and quercetin on luteinizing hormone

Data were expressed as Mean ± S.E.M (n = 5) and One-way ANOVA followed by the Bonferroni post hoc test was used for data analysis

The Effects of Zinc Oxide Nanoparticles and Quercetin on Serum Testosterone Levels

The results as presented in Figure 10 indicate a significant decrease in testosterone levels in the Nanoparticle-treated animals (p <0.0001). Moreover, quercetin was found to ameliorate the deleterious effects of Nanoparticles, with its

testosterone levels showing no significant difference compared to the control. As shown in the graph below, there was a significant difference in serum testosterone levels in the co-administration group compared to the Nanoparticle-treated group (p<0.0001).

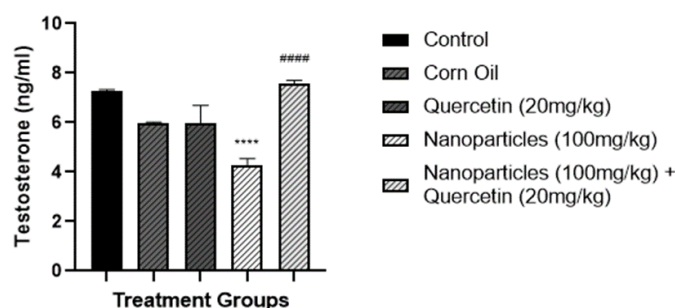


Figure 10: The effects of nanoparticles and quercetin on serum testosterone levels

Data were expressed as Mean ± S.E.M (n = 5) and One-way ANOVA followed by the Bonferroni post hoc test was used for data analysis. ****p <0.0001 when compared with Control; #####p < 0.0001 when compared to Nanoparticles Group

The Effects of Zinc Oxide Nanoparticles and Quercetin on Testosterone-LH Ratio

The results as shown in Figure 11 indicate a significant decrease in the testosterone-LH ratio when compared to the Control group (p<0.0001).

Furthermore, quercetin was able to ameliorate the deleterious effects of the nanoparticles in the nanoparticles and quercetin group co-administration group (p<0.0001) when compared to the control.

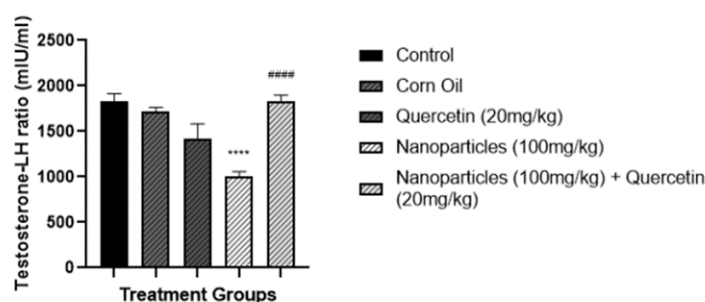


Figure 11: The effects of nanoparticles and quercetin on testosterone-LH ratio

Data were expressed as Mean ± S.E.M (n = 5) and One-way ANOVA followed by the Bonferroni post hoc test was used for data analysis. ****p <0.0001 when compared with Control; #####p < 0.0001 when compared to Nanoparticles Group

The Effects of Zinc Oxide Nanoparticles and Quercetin on Sperm Motility

The result as shown in Table 1 reveals that the treatment groups showed no significant difference in sperm motility, viability and count

when compared to the control group. Moreover, the result also showed no significant difference in sperm motility, viability and count between the Nanoparticle treatment group and those of the Nanoparticle + Quercetin treatment group.

Table 1: The effects of Zinc Oxide Nanoparticles and Quercetin on Sperm motility, viability and count

Treatment Group	Sperm Motility (%)	Sperm Viability (%)	Sperm Count (million/mL)
Control	86.00 ± 2.45	90.40 ± 1.91	104.20 ± 6.14
Corn Oil	81.00 ± 2.45	86.00 ± 1.87	116.60 ± 4.84
Quercetin	85.00 ± 1.58	91.00 ± 1.87	103.20 ± 7.43
ZnO NPs	81.00 ± 3.32	90.00 ± 1.58	104.40 ± 5.40
ZnO NPs + Quercetin	86.00 ± 1.87	91.00 ± 1.87	113.40 ± 5.87

Data were expressed as Mean ± S.E.M (n = 5) and One-way ANOVA followed by the Bonferroni post hoc test was used for data analysis.

The Effects of Zinc Oxide of Nanoparticles and Quercetin on Histology of the Testes

Results show that intoxication with ZnO resulted in degeneration of testicular morphology characterized by decentralised lumen, with necrotic Leydig cells and pyknotic Sertoli cells. Furthermore, the testes showed hypertrophy with germinal epithelium that is disarranged and

fragmented. However, treatment of Quercetin alongside ZnO significantly normalized the testicular cytoarchitecture as the cellular assessments in this group show a well-centralized lumen. Moreover, Leydig cells are properly arranged and surrounded by connective tissues in the interstitial space and the germinal epithelium was properly arranged.

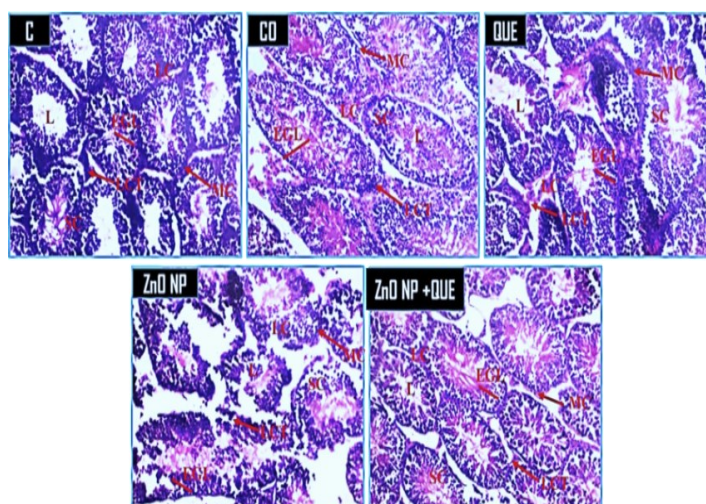


Figure 12: The effects of zinc oxide of nanoparticles and quercetin on the histology of the testes

C - Control, CO - Corn Oil, QUE-Quercetin, and ZnO NPs – Zinc Oxide nanoparticles

Discussion

This study aimed to investigate the anti-oxidative and anti-inflammatory effects of quercetin administration against testicular toxicity induced by zinc oxide nanoparticles (ZnO NPs). We observed a significant increase in testicular zinc concentration in the group treated with ZnO NPs when compared to the control group. This elevation in zinc levels can be attributed to the dissolution of ZnO NPs, leading to the release of zinc ions, a phenomenon documented in previous research (27). Interestingly, in the ZnO NPs+Quercetin group, we noted a significant difference in testicular zinc concentration when compared to the group treated with zinc oxide nanoparticles alone. This observation aligns with the known metal-chelating properties of quercetin, as reported in prior studies (28). These findings suggest that quercetin may exert its

influence by interacting with zinc ions, potentially chelating or sequestering them to some extent. Oxidative stress arises from an imbalance between pro-oxidant and antioxidant substances within a biological system, as highlighted in research by Pizzino et al. (29). This imbalance triggers lipid peroxidation, leading to the formation of aldehydes and related compounds such as Malondialdehyde (MDA), as described in the study by Moldogazieva et al. (30). MDA levels have been widely utilized as a reliable indicator for assessing oxidative stress, as demonstrated in studies by Altun et al. (31) and Ghonimi et al. (32). In our study, we observed significantly elevated testicular MDA levels in the group exposed to zinc oxide nanoparticles (ZnO NPs) when compared to the control group. However, in the ZnO NPs+Quercetin group, a notable reduction in testicular MDA concentration was evident in comparison to the ZnO NPs group.

This finding suggests that quercetin effectively mitigated the oxidative stress induced by ZnO NPs within the testes. This result aligns with the findings reported by Li *et al.* (33), who demonstrated a decrease in MDA concentrations in a rat model of Acute Myocardial Infarction following quercetin administration.

In a study by Xu *et al.* (34) on silk worms exposed to ZnO NPs, SOD and CAT levels initially increased, but a decline was observed after 36 hours. The study hypothesized that excess superoxide ions might inhibit SOD activity, indirectly affecting CAT. Our current study aligns with this hypothesis, as it revealed a significant decrease in mean testicular SOD and CAT concentrations in the Nanoparticle treatment group. Interestingly, the Nanoparticle+Quercetin group displayed a notable increase in mean testicular SOD levels, indicating that quercetin had an ameliorative effect. However, quercetin was unable to restore CAT concentrations, which remained significantly reduced.

Testicular Total Antioxidant Capacity (TAC), an indicator of testicular antioxidant activity, reveals a significant decrease in the Zinc Oxide Nanoparticles treatment group. Conversely, quercetin ameliorated this effect in the Zinc Oxide Nanoparticle + Quercetin treatment group. This suggests that co-administration of quercetin may have restored the total antioxidant capacity to levels akin to the normal physiological state. These findings can be corroborated by the research conducted by Ziamajidi *et al.* in 2023 (35), which demonstrated the successful mitigation of ZnO NP-induced oxidative stress by well-known antioxidants such as Vitamins A, C, and E. This further underscores the remarkable antioxidant potential of Quercetin and its ability to counteract the oxidative effects triggered by ZnO NPs.

Multiple studies (36, 37, 38) have examined the impact of zinc oxide nanoparticles (ZnO NPs) on hormone levels. These studies collectively show that ZnO NPs tend to raise follicle-stimulating hormone (FSH) and testosterone levels while leaving luteinizing hormone (LH) levels relatively unchanged. For instance, a 2020 study on male NMRI rats revealed increased serum testosterone and FSH levels with intra-peritoneal ZnO NP administration (37). Conversely, another study on mice reported a dose-dependent decrease in testosterone levels following oral ZnO NP administration (36). Our study, however, aligns with this later finding, indicating a significant reduction in testosterone levels without significant changes in FSH and LH levels. These discrepancies may be due to variations in exposure duration, nanoparticle dosage, animal models, and administration routes. The decrease in testosterone indicated in this study could be a

result of inflammation at the Leydig cells of the testes. This is corroborated by the results of this study which shows a significant increase in the concentration of testicular TNF- α , a pro-inflammatory cytokine, in the nanoparticle-treated group when compared to the control. Quercetin however was shown to ameliorate the effect of zinc oxide nanoparticles on testosterone levels. Several plausible mechanisms may underlie these observed effects. First, quercetin has demonstrated metal-chelating properties in multiple studies, enabling it to bind with zinc within cells, and aiding in the elimination of zinc from the body (39). This aligns with our findings of a significant reduction in testicular zinc oxide levels in the groups treated with quercetin. Additionally, quercetin's ameliorative effects might be attributed to its anti-inflammatory mechanisms. Our analysis of tumour necrotic factor (TNF- α) levels revealed a significant increase in the nanoparticle-treated groups. TNF- α , an inflammatory cytokine produced during acute inflammation by macrophage (40), has been linked to increased expression due to zinc oxide nanoparticles, signifying the presence of cellular inflammation (41). Our study supports this by showing significantly elevated TNF- α levels in the group treated solely with zinc oxide nanoparticles compared to the control, indicating testicular inflammation. Quercetin demonstrated anti-inflammatory properties in our study, as evidenced by its ability to mitigate the potentially pro-inflammatory effects induced by zinc oxide nanoparticles in the testes. This was highlighted by a significant reduction in TNF- α levels in the co-administration group compared to the nanoparticle group.

Also, in this study, the observed decrease in serum testosterone levels relative to serum luteinizing hormone (Testosterone-LH ratio) in the nanoparticle-treated group compared to the control holds important implications. It signifies a reduction in testosterone production from the Leydig cells, while LH secretion remained unaffected. This imbalance, characterized by low testosterone levels concerning LH, is associated with primary hypogonadism or primary testicular failure (42). Such an outcome may be attributed to potential damage to the Leydig cells, impairing their ability to produce testosterone despite the continued secretion of LH by the anterior pituitary. This finding is consistent with the increased levels of the inflammatory marker TNF- α in the nanoparticle-treated groups compared to the control, indicating the presence of inflammation in the testes, as demonstrated in our study. Moreover, other research studies have also reported heightened inflammatory responses at various sites, including the testes, following nanoparticle exposure (43, 44).

The spermatogenesis cycle in mice typically spans around 35 days, as indicated by Perrard et al. (45). During this process, germ cells transform spermatozoa. In our study, the treatment period was limited to 7 days, which falls short of completing one full cycle of spermatogenesis. This shortened exposure duration may explain the absence of significant alterations in sperm parameters, including motility, viability, and count, as revealed in our semen analysis. This underscores the importance of considering the timing and duration of treatments when assessing their impact on sperm parameters and reproductive outcomes in animal studies. Lastly, histological examination of the testes revealed degeneration of testicular morphology due to ZnO NP administration. This finding can be corroborated by the results of Mozaffari et al. (2015) (44). However, in the group receiving a combination of ZnO NPs and Quercetin, the histological analysis revealed a normal cytoarchitecture, indicating the ameliorative effects of Quercetin on the alterations induced by ZnO NPs.

Conclusion

Quercetin in this study was shown to demonstrate its anti-inflammatory and anti-oxidative properties against zinc oxide nanoparticles inducing testicular toxicity by restoring serum testosterone levels.

List of Abbreviations

MDA:	Malondialdehyde
SOD:	Superoxide dismutase
CAT:	Catalase
GSH:	Glutathione peroxidase
TAC:	Total antioxidant capacity
ZnO NPs:	Zinc oxide nanoparticles
TNF- α :	Tumour necrotic factor – alpha
FSH:	Follicle-stimulating hormone
LH:	Luteinizing hormone

Declarations

Ethics approval and consent to participate

Ethical approval was obtained from Babcock University Health Research Ethics Committee (BUHREC), with registration number 320/24.

Consent for Publication:

All the authors gave their consent for the publication of the work under the Creative Commons Attribution Non-Commercial 4.0 license. Otherwise, all copyright ownership including all rights incidental thereto is conveyed to the journal when published.

Availability of data and materials

The study data is available upon request to the corresponding author.

Competing interests

The authors declare that there are no conflicts of interest.

Funding

The authors did not receive any funding from funding agencies.

Authors' contributions

Conceptualization, OBO, GOO, EWU and EGO.; methodology, OBO, OMO, CEO and TVO.; validation, OBO, PGO and EGO; formal analysis, OBO, CEO, EGO and TK; investigation, CEO, TVO; resources, OBO, CEO, TVO and EWU; data curation, OBO and CEO; writing—original draft preparation, OBO, ADA, TK and TFA; writing—review and editing, OMO, ADA, PGO, GOO; supervision, OBO; project administration, ADA, CEO and TVO; funding acquisition, OBO, CEO and TVO. All authors have read and agreed to the published version of the manuscript.

Acknowledgements

The authors are grateful to the technical staff of the Department of Physiology, Babcock University, Ogun State, Nigeria, and the technical unit of the Histology Department of the University Teaching Hospital of the University of Ibadan, Ibadan, Oyo State, Nigeria.

References

1. Khan ZU H, Sadiq HM, Shah NS, Khan AU, Muhammad N, Hassan SU, Tahir K, Safi SZ, Khan FU, Imran M, Ahmad N, Ullah F, Ahmad A, Sayed M, Khalid MS, Qaisrani SA, Ali M, Zakir A. Greener synthesis of zinc oxide nanoparticles using *Trianthema portulacastrum* extract and evaluation of its photocatalytic and biological applications. *Journal of Photochemistry and Photobiology B: Biology*, 2019;192, 147–157. <https://doi.org/10.1016/j.jphotobiol.2019.01.013>
2. Bedi P, Kaur A. An overview of uses of zinc oxide nanoparticles. *World Journal of Pharmacy and Pharmaceutical Sciences*, 2015; 4(12), 1177-1196.
3. Ferdous Z, Nemmar A. Health Impact of Silver Nanoparticles: A Review of the Biodistribution and Toxicity Following Various Routes of Exposure. *Inter*, 2020. <https://doi.org/10.3390/ijms21072375>
4. Pinho AR, Rebelo S, Pereira MDL. The Impact of Zinc Oxide Nanoparticles on Male (In)Fertility. *Materials*, 2020;13(4), 849. <https://doi.org/10.3390/ma13040849>

5. Oghenetega OB, Oyovwi OM, Obidimma CE, Ijabodede VT, Oghenetega GE, Okwute GP. The Spermatotoxic Effects of Some Selected Metal Nanoparticles. *International Journal of Basic Science and Technology*. 2023, 9 (2); Pages 124–138. <https://doi.org/10.5555/NFLC5219>
6. Sies H. Oxidative stress: a concept in redox biology and medicine. *Redox Biology*, 2015, 4, 180–183. <https://doi.org/10.1016/j.redox.2015.01.002>
7. Asadi N. The Impact of Oxidative Stress on Testicular Function and the Role of Antioxidants in Improving it: A Review. *Journal of Clinical and Diagnostic Research*. 2017, <https://doi.org/10.7860/jcdr/2017/23927.9886>
8. Asadi N. The Impact of Oxidative Stress on Testicular Function and the Role of Antioxidants in Improving it: A Review. *Journal of Clinical and Diagnostic Research*. 2017 <https://doi.org/10.7860/jcdr/2017/23927.9886>
9. Pahwa R, Goyal A, Jialal I. Chronic Inflammation - StatPearls - NCBI Bookshelf. *Chronic Inflammation - StatPearls - NCBI Bookshelf*. 2023, <https://www.ncbi.nlm.nih.gov/books/NBK493173/>
10. Zhao S, Zhu W, Xue S, Han D. Testicular defence systems: immune privilege and innate immunity. *Cellular & Molecular Immunology*, 2014,11(5), 428–437. <https://doi.org/10.1038/cmi.2014.38>
11. Behairy A, Hashem MM, Abo-El-Sooud K., El-Metwally AE, Hassan BA, Abd-Elhakim YM. Quercetin Abates Aluminum Trioxide Nanoparticles and Lead Acetate Induced Altered Sperm Quality, Testicular Oxidative Damage, and Sexual Hormones Disruption in Male Rats. *Antioxidants*, 2022,11(11), 2133. <https://doi.org/10.3390/antiox11112133>
12. Dutta S, Sengupta P, Slama P, Roychoudhury S. Oxidative Stress, Testicular Inflammatory Pathways, and Male Reproduction. *International Journal of Molecular Sciences*, 2021, 22(18), 10043. <https://doi.org/10.3390/ijms221810043>
13. Oyovwi MO, Ben-Azu B, Tesi EP, Oyeleke AA., Uruaka CI, Rotu RA., Aya-Ebi EO. Repeated endosulfan exposure induces changes in neurochemicals, decreases ATPase transmembrane ionic-pumps, and increased oxidative/nitrosative stress in the brains of rats: Reversal by quercetin. *Pesticide Biochemistry and Physiology*, 2021,175, 104833. <https://doi.org/10.1016/j.pestbp.2021.104833>
14. Oyovwi MO, Benneth BA, Edesiri TP, Rume RA, Victor E, Rotu RA, Adebayo OG. Possible mechanisms involved in the testicular-protective property of quercetin in rats exposed to endosulfan toxicity. *Pesticide Biochemistry and Physiology*, 2022a,188, 105224. <https://doi.org/10.1016/j.pestbp.2022.105224>
15. Oghenetega OB, Okwute PG, Nweke ML, Ugwuishi EW, Oyovwi OM, Oghenetega GE, Emojevwe V, Abraham TF. The Effects of Quercetin on Testicular Toxicity Induced by Water-soluble Fraction of Crude Oil in Male Wistar Rats. *Nigerian Journal of Biochemistry and Molecular Biology*. 2022 Oct 28;37(3):222-8.
16. Oyovwi OM, Onome BO, Emojevwe V, Falajiki YF, Joseph GU. Quercetin Protects against Levetiracetam induced gonadotoxicity in rats. *Toxicology*; Available online 23 2023, 153518. <https://doi.org/10.1016/j.tox.2023.153518>
17. Ay M, Charli A, Jin H, Anantharam V, Kanthasamy A, Kanthasamy AG. Quercetin. *Nutraceuticals*, 2021,749–755. <https://doi.org/10.1016/b978-0-12-821038-3.00043-4>
18. Fadoju O, Ogunsuyi O, Akanni O, Alabi O, Alimba C, Adaramoye O, Cambier S, Eswara S, Gutleb AC, Bakare A. Evaluation of cytogenotoxicity and oxidative stress parameters in male Swiss mice co-exposed to titanium dioxide and zinc oxide nanoparticles. *Environmental Toxicology and Pharmacology*. 2019 Aug 1;70:103204. <https://doi.org/10.1016/j.etap.2019.103204>
19. Georgantzopoulou A, Serchi T, Cambier S, Leclercq CC, Renaut J, Shao J., Kruszewski M, Lentzen E, Grysan P, Eswara S, Audinot JN, Contal S, Ziebel J, Guignard C, Hoffmann L, Murk AJ, Gutleb AC. Effects of silver nanoparticles and ions on a co-culture model for the gastrointestinal epithelium. *Particle and Fibre Toxicology*, (2015,13(1). <https://doi.org/10.1186/s12989-016-0117-9>
20. Cambier S, Røgeberg M, Georgantzopoulou A, Serchi T, Karlsson C, Verhaegen S., Iversen T G, Guignard C, Kruszewski M, Hoffmann L, Audinot J N, Ropstad E, Gutleb AC. Fate and effects of silver nanoparticles on early life-stage development of zebrafish (*Danio rerio*) in comparison to silver nitrate. *Science of the Total Environment*, 2018, 610–611, 972–982. <https://doi.org/10.1016/j.scitotenv.2017.08.115>

21. Wallin B, Rosengren B, Shertzer HG, Camejo G. Lipoprotein oxidation and measurement of thiobarbituric acid reacting substances formation in a single microtiter plate: its use for evaluation of antioxidants. *Analytical biochemistry*. 1993 Jan 1;208(1):10-5. <https://doi.org/10.1006/abio.1993.1002>
22. Misra HP, Fridovich I. Superoxide dismutase: "positive" spectrophotometric assays. *Analytical biochemistry*. 1977 May 1;79(1-2):553-60. [https://doi.org/10.1016/0003-2697\(77\)90429-8](https://doi.org/10.1016/0003-2697(77)90429-8)
23. Aebi H. Catalase in vitro. In *Methods in enzymology* 1984 Jan 1 (Vol. 105, pp. 121-126). Academic press. [https://doi.org/10.1016/S0076-6879\(84\)05016-3](https://doi.org/10.1016/S0076-6879(84)05016-3)
24. Ellman GL. Tissue sulfhydryl groups. *Archives of biochemistry and biophysics*. 1959 May 1;82(1):70-7. [https://doi.org/10.1016/0003-9861\(59\)90090-6](https://doi.org/10.1016/0003-9861(59)90090-6)
25. DeGraft-Johnson J, Kolodziejczyk K, Krol M, Nowak P, Krol B, Nowak D. Ferric-reducing ability power of selected plant polyphenols and their metabolites: implications for clinical studies on the antioxidant effects of fruits and vegetable consumption. *Basic & clinical pharmacology & toxicology*. 2007 May;100(5):345-52. <https://doi.org/10.1111/j.1742-7843.2007.00056.x>
26. Zemjanis R. Diagnostic and therapeutic techniques in animal reproduction. *Diagnostic and therapeutic techniques in animal reproduction*. 1970(2nd edn).
27. Xia T, Kovochich M, Liang M, Mädler L, Gilbert B, Shi H, Yeh JI, Zink JI, Nel AE. Comparison of the Mechanism of Toxicity of Zinc Oxide and Cerium Oxide Nanoparticles Based on Dissolution and Oxidative Stress Properties. *ACS Nano*, 2008 2(10), 2121–2134. <https://doi.org/10.1021/nn800511k>
28. Primikyri A, Mazzone G, Lekka C, Tzakos AG, Russo N, Gerathanassis IP. Understanding Zinc(II) Chelation with Quercetin and Luteolin: A Combined NMR and Theoretical Study. *The Journal of Physical Chemistry B*, 2014,119(1), 83–95. <https://doi.org/10.1021/jp509752s>
29. Pizzino G, Irrera N, Cucinotta M, Pallio G, Mannino F, Arcoraci V, Squadrito F, Altavilla D, Bitto A. Oxidative Stress: Harms and Benefits for Human Health. *Oxidative Medicine and Cellular Longevity*, 2017, 1–13. <https://doi.org/10.1155/2017/8416763>
30. Moldogazieva NT, Mokhosoev IM, Mel'nikova TI, Porozov YB, Terentiev AA. Oxidative Stress and Advanced Lipoxidation and Glycation End Products (ALEs and AGEs) in Aging and Age-Related Diseases. *Oxidative Medicine and Cellular Longevity*, 2019, 1–14. <https://doi.org/10.1155/2019/3085756>
31. Altun H, Şahin N, Kurutaş EB, Karaaslan U, Sevgen FH, Fındıklı E. Assessment of malondialdehyde levels, superoxide dismutase, and catalase activity in children with autism spectrum disorders. *Psychiatry and Clinical Psychopharmacology*, 2018,28(4), 408–415. <https://doi.org/10.1080/24750573.2018.1470360>
32. Ghonimi NA, Elsharkawi KA, Khyal DS, Abdelghani AA. Serum malondialdehyde as a lipid peroxidation marker in multiple sclerosis patients and its relation to disease characteristics. *Multiple Sclerosis and Related Disorders*, 2021;51, 102941. <https://doi.org/10.1016/j.msard.2021.102941>
33. Li YR, Trush M. Defining ROS in Biology and Medicine. *Reactive Oxygen Species*, 2016;1(1). <https://doi.org/10.20455/ros.2016.803>
34. Xu L, Wang YY, Huang J, Chen CY, Wang ZX, Xie H. Silver nanoparticles: Synthesis, medical applications and biosafety. *Theranostics*, 2020,10(20), 8996–9031. <https://doi.org/10.7150/thno.45413>
35. Ziamajidi,N, Khajvand-Abedini M, Daei S, Abbasalipourkabir R, Nourian A. Ameliorative Effects of Vitamins A, C, and E on Sperm Parameters, Testis Histopathology, and Oxidative Stress Status in Zinc Oxide Nanoparticle-Treated Rats. *BioMed Research International*, 2023, 1–14. <https://doi.org/10.1155/2023/4371611>
36. Tang Y, Chen B, Hong W, Chen L, Yao L, Zhao Y, Aguilar ZP, Xu H. ZnO nanoparticles induced male reproductive toxicity based on the effects on the endoplasmic reticulum stress signaling pathway. *International Journal of Nanomedicine*. 2019 Dec 4:9563-76. <https://doi.org/10.2147/ijn.s223318>
37. Mozaffari Z, Parivar K, Roodbari NH, Irani S. The Impact of Zinc Oxide Nanoparticle on LH, FSH, and Testosterone Hormones in Mature Male NMRI Rats. *Journal of Pharmaceutical Research International*, 2020,30–37. <https://doi.org/10.9734/jpri/2020/v32i430422>
38. Ogunsuyi OM, Ogunsuyi OI, Akanni O, Alabi OA, Alimba CG, Adaramoye OA, Cambier S, Eswara S, Gutleb AC, Bakare AA. Alteration of sperm parameters and reproductive hormones in Swiss mice via oxidative stress after co-exposure to titanium dioxide and zinc oxide nanoparticles. *Andrologia*,

- 2020,52(10).
<https://doi.org/10.1111/and.13758>
39. de Castilho TS, Matias TB, Nicolini KP, Nicolini J. Study of interaction between metal ions and quercetin. *Food Science and Human Wellness*, 2018,7(3), 215–219. <https://doi.org/10.1016/j.fshw.2018.08.001>
40. Jang DI, Lee AH, Shin HY, Song HR, Park JH, Kang TB, Lee SR, Yang SH. The Role of Tumor Necrosis Factor Alpha (TNF- α) in Autoimmune Disease and Current TNF- α Inhibitors in Therapeutics. *International Journal of Molecular Sciences*, 2021;22(5), 2719. <https://doi.org/10.3390/ijms22052719>
41. Attia H, Nounou H, Shalaby M. Zinc Oxide Nanoparticles Induced Oxidative DNA Damage, Inflammation and Apoptosis in Rat's Brain after Oral Exposure. *Toxics*, 2018,6(2), 29. <https://doi.org/10.3390/toxics6020029>
42. Khan MS, Sheikh MA, Danyal A, Ali I, Tahir F, Bashir M, ... Asif A. Does LH/Testo and Testo/LH ratio affect male fertility? In *Medical Forum Monthly* 2006, (Vol. 17, No. 6, pp. 5-9). *Medical Forum Monthly*.
43. Mesallam DI, Deraz RH, Abdel Aal SM, Ahmed SM. Toxicity of Subacute Oral Zinc Oxide Nanoparticles on Testes and Prostate of Adult Albino Rats and Role of Recovery. *Journal of Histology and Histopathology*, 2019, 6(1), 2. <https://doi.org/10.7243/2055-091x-6-2>
44. Ibrahim A, Ibrahim MD, A F A A M, Manal M M, MD, H E M M.. Effect of Zinc Oxide Nanoparticles on the Structure of Testis of Adult Albino Rats and the Possible Protective Role of Naringenin. *The Medical Journal of Cairo University*, 2019,87(September), 3469–3483. <https://doi.org/10.21608/mjcu.2019.65644>
45. Perrard MH, Sereni N, Schluth-Bolard C, Blondet A, d'Estaing SG, Plotton I, Morel-Journel N, Lejeune H, David L, Durand P. Complete Human and Rat Ex Vivo Spermatogenesis from Fresh or Frozen Testicular Tissue. *Biology of Reproduction*, 2016, 95(4), 89–89. <https://doi.org/10.1095/biolreprod.116.142802>