


# Extra-digital glomus tumour of the forehead: a case report of a solitary solid histopathologic subtype

Rahman AT<sup>1</sup>, Awosusi BL<sup>2</sup>


<sup>1</sup>Department of Anatomic Pathology, King Salman Medical City, Medina, Saudi Arabia

<sup>2</sup>Department of Anatomic Pathology King Khalid Hospital, Almajma'ah, Saudi Arabia

Submitted: 15<sup>th</sup> January 2024

Accepted: 19<sup>th</sup> April 2024

Published: 30<sup>th</sup> June 2024

: Orcid ID

## Abstract

**Background:** Glomus tumours (GT) are benign neoplasms that develop from neuro-myoarterial structures known as "glomus bodies" involved in temperature and blood pressure control. GT rarely occur in the head and neck region, and the specific location of the glomus tumour on the forehead is even more uncommon.

**Case presentation:** We report the case of a 36-year-old female who presented with painless swelling on the forehead of one year duration with a progressive increase in size. Physical examination showed a small forehead swelling with an initial clinical diagnosis of a sebaceous cyst. The patient had local excision of forehead swelling which was submitted for histopathologic examination.

**Discussion:** The initial histological differential diagnosis included glomus tumour, benign skin adnexal tumour and PEComa. The formalin-fixed-paraffin embedded tissue blocks of the lesion were then subjected to immunohistochemical analysis. The tumour cells were negative for cytokeratin and positive for SMA and S100. Based on the morphology and immunohistochemical staining characteristics of the tumour cells, a diagnosis of glomus tumour was made.

**Conclusion:** Glomus tumour occurring on the forehead is uncommon. Therefore, a high index of suspicion is needed for diagnosis. Immunohistochemistry may be needed to confirm the diagnosis and rule out other close differential diagnoses.

**Keywords:** Forehead, Extra-digital, Glomus tumour, Glomangioma, Solid subtype

## Introduction

Glomus tumours are benign neoplasms that develop from "neuro-myoarterial structures" known as glomus bodies which are located in the dermal "stratum reticularis" specifically in the "Succquet-Hoyer canal" (1, 2). These Glomus bodies participate in temperature regulation and blood pressure regulation by controlling the blood flow in the skin (1). Glomus tumours have been reported to occur in almost every part of the body, even in locations that lack glomus bodies (2). They usually present as solitary lesions in the distal extremities,

particularly in the subungual areas rich in glomus cells (3). Glomus tumours occurring outside the digits account for about 26.7% of cases with a mean age of 48 years (3). It is also seen more commonly in males (male-to-female ratio of 11: 3) with a predilection for the upper limb (3). Glomus tumours rarely occur in the head and neck region (2). After a detailed search of the literature, we found two earlier reported cases of forehead location - one was described as a "telangiectatic type of glomangioma" while the second case was described as a "glomangioma of uncertain

Correspondence:

Awosusi, Babatope L

Department of Anatomic Pathology,

King Khalid Hospital, Almajma'ah,

Saudi Arabia.

+966554537950, [awosusilanre2@gmail.com](mailto:awosusilanre2@gmail.com)

malignant potential" (4, 5). However, despite the uncommon occurrence on the forehead, some other cases have been reported in the head and neck region including the malar region, cheeks, chin, orbital region and middle ear (2, 6, 7, 8, 9). Here we report the case of a glomus tumour occurring at an unusual location on the forehead in a 36-year-old female, and how the diagnostic dilemma was resolved with ancillary immunohistochemistry.

### Case presentation

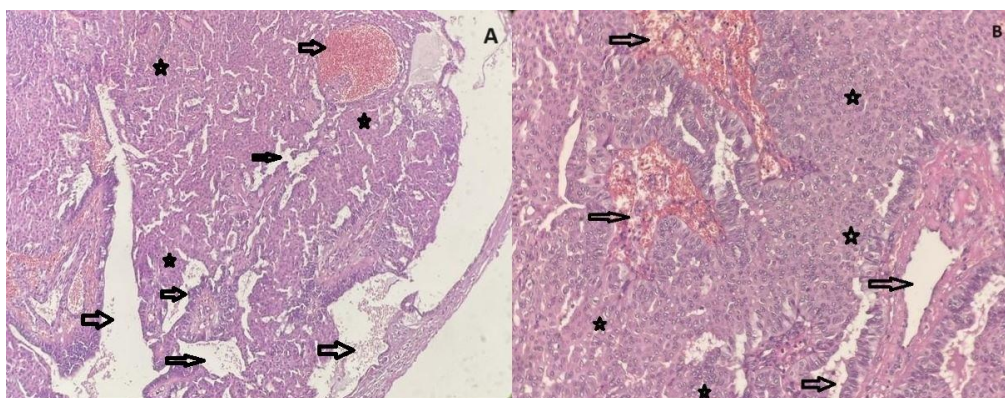
We hereby report the case of a 36-year-old female who presented with a one-year history of painless swelling on the right aspect of the forehead. There was a history of gradual increase in size with no other associated symptoms. There is no history of prior trauma or insect bite to the site. There is no significant past medical history or background comorbidity. She had a normal spontaneous vaginal delivery eight months before the index presentation. On examination at the time of presentation, she was conscious and alert. A small swelling was seen on the right aspect of the forehead measuring 1x1cm with a small central punctum. Systemic examination was unremarkable.

Ultrasound examination of the swelling showed a small nodule limited to the subcutaneous tissue of

the forehead. Chest x-ray done was unremarkable. A full blood count showed mild anaemia with a packed cell volume of 33.8% (normal is 36 to 46% for age and gender). Abdominal examination showed a small hyperechoic lesion in the right cortical kidney measuring 0.6x0.5cm suggestive of an angioliipoma. Other laboratory investigations done include serum biochemistry, lipid profile, viral screen and clotting profile which were all unremarkable. The initial clinical impression was that of a sebaceous cyst. Local excision of the forehead swelling was done and the sample was sent for histopathologic examination.

Gross finding: the sample received at histopathologic grossing was a small partly encapsulated, grey-white nodule measuring 1.5x1x1 cm in dimension. Cut sections show firm, tan hemorrhagic surfaces.

Microscopic finding: sections show some dilated and ectatic blood vessels having surrounding clusters of bland monomorphic cuboidal cells with oval punched-out nuclei and eosinophilic cytoplasm with no distinct boundaries (Figure 1 A and B). The initial morphologic differential diagnoses were PEComa, benign vasoformative/pericytic tumour and benign skin adnexal tumour.



**Figure 1: photomicrographs show a partly encapsulated lesion with dilated and ectatic blood vessels (arrows) and surrounding bland monomorphic cuboidal cells (stars). Haematoxylin and eosin stain, A: x40 magnification B: X100 magnification.**

The formalin-fixed-paraffin-embedded tissue blocks of the tumour were subsequently submitted for immunohistochemical analysis to resolve the diagnostic dilemma. A panel of Pan-cytokeratin, SMA, CK 7, HMB 45, and CD 34 antibodies was

used. The tumour cells were positive for SMA antibody (Figure 2) and S100 antibody (Figure 3); but negative for Pancytokeratin, CK 7, HMB45 and CD 34 (Figure 4 A, B, C, D).

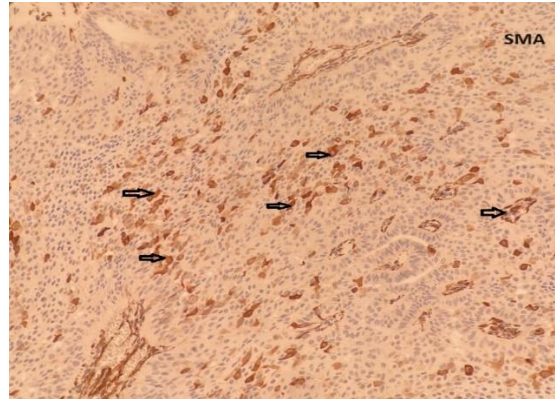


Figure 2: photomicrograph shows 60% of tumour cells with a moderate cytoplasmic positive staining pattern for SMA antibody (black arrows). Immunoperoxidase stain, X100 magnification.

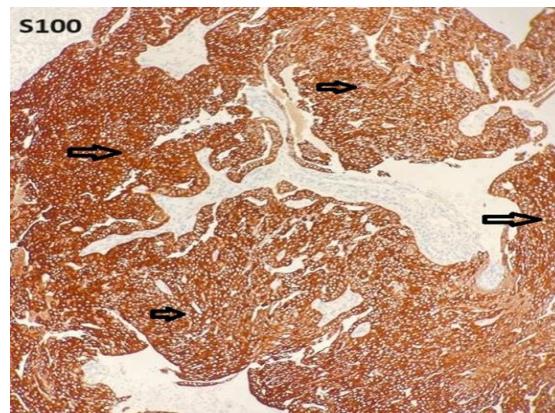


Figure 3: photomicrograph shows 90% of tumour cells with diffuse nuclear and cytoplasmic positive staining pattern for S100 antibody (black arrows). Immunoperoxidase stain, X100 magnification.

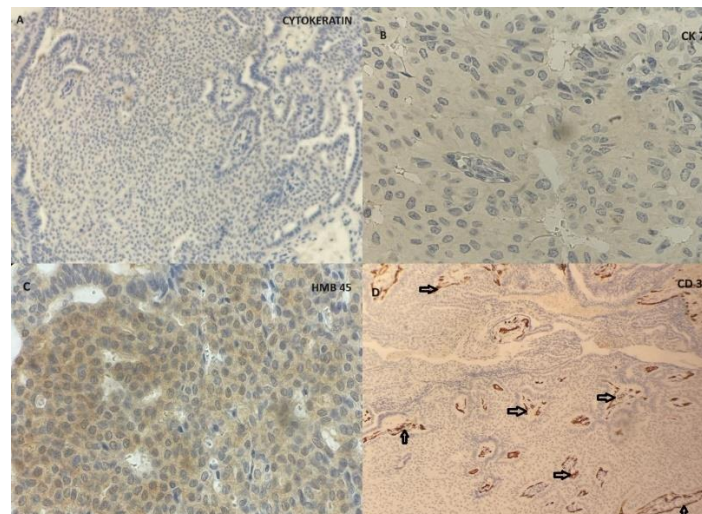


Figure 4: Immunoperoxidase stain, X100 magnification.

A: tumour cells show negative staining for Pan-cytokeratin antibody.

B: tumour cells show negative staining for CK 7 antibody.

C: tumour cells show negative staining for the HMB 45 antibody (only background staining seen).

D: CD 34 highlights the endothelial cells of blood vessels (black arrows) while the tumour cells are negative for the stain.

Based on the morphology and immunohistochemical staining characteristics of the tumour cells, a conclusive diagnosis of a solid sub-type of glomus tumour was made. The patient was stable postoperatively and discharged for follow-up in the surgical outpatient clinic.

### Discussion

Wood in 1812 was the first person to describe a glomus tumor as "a painful subcutaneous tubercle" while Kolaczek in 1878 described their common subungual location (10, 11). However, it was Barre and Masson who described the microscopic features of the glomus tumour in 1924 and discovered its origin in the glomus body (10, 11).

There are two different forms of glomus tumours namely the solitary form and the multiple form (10). The solitary form is more common than the multiple type and it accounts for about 90% of cases (10, 11). The multiple forms are more common in children with an autosomal dominant pattern of inheritance (11). Glomus tumours are classified based on World Health Organization (WHO) criteria as benign, uncertain malignant potential (glomus tumours of uncertain malignant potential GT-UMP), or malignant (12). A small subset of glomus tumours show BRAF mutations, which are associated with malignant histology and more than half of sporadic benign or malignant glomus tumours show NOTCH gene rearrangements (12). Syndromic glomus tumours show mutations in the glomulin gene and uniparental disomy and are also seen in neurofibromatosis type 1 (12).

Glomus tumours are predominantly benign, however, about 1% of cases are malignant with some reported cases of metastasis (10). Factors that support malignancy include a deep location, tumour size of more than 2 cm, mitotic activity that is more than 5 per 10 high-power fields with atypical mitotic figures, and moderate-to-marked nuclear atypia (10). The risk of metastasis can reportedly be up to 25% in the presence of all the features just described (10). In this index case, the likelihood of malignancy was eliminated due to the tumour's superficial location, small size and lack of nuclear atypia (10).

The most common location of the glomus tumour is underneath the nail plate, in which case it is referred to as a "glomus subungual tumour (GUT)" (11). A glomus tumour may also rarely occur at other sites, when it occurs outside the common subungual location as seen in this index case, it is termed a "glomus extradigital tumour (GET)" (11). The head and neck region is a rare location for extradigital glomus tumours while the forehead is an even more uncommon location for occurrences

in the head and region (11). About 20% of individuals who present with digital or extra-digital glomus tumours have a prior history of trauma (11). A published report described eight patients diagnosed with extradigital glomus tumours who had a preceding history of local trauma (11). It was discovered that the injuries occurred within a time frame that ranged from two weeks to twenty-one years before the diagnosis of the tumour was made (11). There was no prior history of trauma in this index case, and the swelling is thought to have started spontaneously.

The definitive diagnosis of glomus tumour may be missed during the physical examination of the patient, especially if it occurs in an extra-digital location as seen in this index case (11). Those with an extra-digital location usually do not present with all of the three classic symptoms of "pinpoint tenderness, pain and cold sensitivity" (11). Although a presumptive diagnosis of glomus tumour can be made from clinical and radiologic examination, microscopic evaluation of the lesion is required for a definitive diagnosis (11). This case was initially diagnosed pre-operatively as a sebaceous cyst likely because of the absence of the classic clinical signs and the extra-digital location of the lesion.

Glomus tumours are histologically composed of a varying admixture of blood vessels, muscle cells, and glomus cells (10). They can be sub-classified into "solid glomus tumour, glomangioma, and glomangiomyoma" based on the dominant tumour component (10). The most common subtype of glomus tumour is the solid subtype comprising up to 75% of cases, whereby glomus cells predominate and are disposed of in solid sheets (10). The glomangioma subtype accounts for about 20% of excised cases of glomus tumour and is composed predominantly of large dilated blood vessels surrounded by nests of glomus cells (10). The glomangiomyoma subtype has blood vessels with predominant smooth muscle cells and it is seen in approximately 5% of glomus tumours (10). Glomangiomyomas can be subdivided further into "regional, disseminated, and congenital plaque-like" types (13).

Upon light microscopic evaluation of Haematoxylin and Eosin-stained sections, this index case showed features suggestive of a benign pericytic tumour, most probably a glomus tumour with a predominance of glomus cells and few blood vessels. The other differential diagnosis considered were PEComa and skin adnexal tumours (nodular hidradenoma and spiradenoma). Immunoperoxidase staining may be required to either confirm the diagnosis or rule out other

differential diagnoses as done in this index case. Glomus tumours are positive for Vimentin and SMA, but negative for melanocytic markers such as HMB-45 and Melan-A, they are also negative for epithelial markers like pancytokeratins (10, 13). The tumour cells in our case showed positive staining for SMA and S-100 antibodies.

Typically, glomus tumours are negative for S-100 and after a detailed literature search, we found one case of glomus tumour described by Porter et al. that showed positivity for S100 antibody in their immunohistochemical study of haemangiopericytomas and glomus tumours (14). This isolated case of S100 positivity may not be enough to conclusively state that glomus tumours are positive for S100, larger immunohistochemical and molecular studies will have to be done to elucidate more on this observation. The tumour cells in this index case were negative for pancytokeratin, CK7 and HMB-45, while the endothelial cells of the blood vessels were positive for CD34. This immunohistochemical staining pattern is consistent with what has been described in the literature, thereby aiding our diagnosis of glomus tumour and excluding other confounding differential diagnoses.

Glomus tumours usually present as solitary painful lesions and complete surgical excision is the preferred treatment (15). After surgical removal of the tumour, there may be persistent or recurrent pain which can be due to residual or new tumour (11). If symptoms still occur three or more months after surgery, radiologic valuation and repeat exploration may be required (11). The index patient in this case had complete excision of the lesion and was discharged for follow-up.

### Conclusion

Glomus tumours occurring on the forehead are uncommon and thus a high index of suspicion is needed for diagnosis. Immunohistochemistry may be needed to confirm the diagnosis and rule out other close differential diagnoses. Complete surgical excision is usually curative and the overall prognosis is good.

### List of Abbreviations

BRAF: Serine/Threonine-Protein Kinase B-Raf  
CD: Cluster of Differentiation.  
CK: Cytokeratin  
GET: Glomus Extradigital Tumour  
GT: Glomus Tumour  
GT-UMP Glomus Tumours of Uncertain Malignant Potential  
GUT: Glomus Subungual Tumor  
HMB: Human Melanoma Black

NOTCH: Neurogenic Locus Notch Homolog Protein

SMA: Smooth Muscle Actin

WHO: World Health Organization

### Declarations

*Ethical approval and consent to participate*

Not applicable.

*Consent for publication*

Both authors gave consent for publication of the work under the Creative Commons Attribution-Non-Commercial 4.0 license.

*Availability of data and materials*

All essential data supporting the findings of this case are available within the article. Additional data are available upon request from the corresponding author.

*Competing interests*

The authors declare no conflict of interest.

*Funding*

The authors declare that they had no funding source or financial support.

*Authors' contributions*

Author RAT was involved in the patient management and provided the clinicopathologic data. Author ABL conceptualized the idea of presenting the case for publication and wrote the first manuscript. Both authors corrected the manuscript and agreed on the final manuscript. The manuscript has been read and approved by both authors.

*Acknowledgements*

None.

### References

1. Alyaseen HN, Al Ghadeer HA, Al-Ghanim ME, Aljawad HH, Cordoba CR. Extradigital Glomangioma of the Cutaneous Chest Wall. *Cureus*. 2021;13(9): e17910. <https://doi.org/10.7759/cureus.17910>
2. Wieser ME, Gilley DR, May JG, Rivera AL. A rare case of a middle ear glomangioma. *SAGE Open Med Case Rep*. 2022; 10:2050313X211070520. <https://doi.org/10.1177/2050313X211070520>
3. Garcia LC, Fernandes ENS, Sobreira NP, Bittencourt FV. Extradigital glomus tumor: dermoscopic description and histopathological correlation. *An. Bras. Dermatol*.

- 2021;96(6):765-767.  
<https://doi.org/10.1016/j.abd.2020.11.008>
4. Farias MM, Kolbach M, Perez M, Gonzalez S, Hasson A. Acquired telangiectatic plaque-like glomangioma on the forehead. *Int J Dermatol.* 2013;52(6):731-732.  
<https://doi.org/10.1111/j.1365-4632.2011.05323.x>
  5. D'Antonio A, Adesso M, Caleo A, Altieri R, Boscaino A. Glomus tumor of uncertain malignant potential on the forehead. *Cutis.* 2014;94(3): E13-E16.
  6. Yazdani J, Ghavimi MA, Khorshidi R, Talesh KT, Mortazavi A, Nourizadeh A. A Large Glomus Tumor of the Face: A Case Report. *Advances in Bioscience & Clinical Medicine* 2015; 3(4): 48-52.  
<https://doi.org/10.7575/aiac.abcm.15.03.04.10>
  7. Veros K, Markou K, Filizati C, Kyrmizakis DE. Glomus tumor of the cheek: a case report. *Case Rep Med.* 2012; 2012:307294.  
<https://doi.org/10.1155/2012/307294>
  8. Lee M-W, Lee J-Y, Park S-M. Solitary glomangioma on the chin: A rare case report. *Oral and Maxillofacial Surgery Cases* 2022; 8:100248.  
<https://doi.org/10.1016/j.omsc.2022.100248>
  9. Olivieri S, Toninelli S, Giorgio A, Fruschelli M, Miracco C, Oliveri G. Orbital glomangioma. *Orbit.* 2012;31(4):216-218.  
<https://doi.org/10.3109/01676830.2012.678546>
  10. Douida A, Tahiri L, Mazti A, Abdellaoui K, Sanhaji I, Hammas N, et al. A Case Report of a Glomangioma in an Unusual Location and Review of the Literature. *American Journal of Biomedical Science and Research* 2020;10(3).  
<https://doi.org/10.34297/AJBSR.2020.10.001511>
  11. Cohen PR. Glomus Extradigital Tumor: A Case Report of an Extradigital Glomus Tumor on the Wrist and Comprehensive Review of Glomus Tumors. *Cureus* 2023; 15(5): e38737.  
<https://doi.org/10.7759/cureus.38737>
  12. Wu RC, Gao YH, Sun WW, Zhang XY, Zhang SP. Glomangiomas - immunohistochemical study: A case report. *World J Clin Cases.* 2022;10(16):5406-5413.  
<https://doi.org/10.12998/wjcc.v10.i16.5406>
  13. Munoz C, Bobadilla F, Fuenzalida H, Goldner R, Sina B. Congenital glomangioma of the breast: type 2 segmental manifestation. *Int J Dermatol.* 2011;50(3):346-349.  
<https://doi.org/10.1111/j.1365-4632.2010.04565.x>
  14. Porter PL, Bigler SA, McNutt M, Gown AM. The immunophenotype of hemangiopericytomas and glomus tumors, with special reference to muscle protein expression: an immunohistochemical study and review of the literature. *Mod Pathol.* 1991; 4(1):46-52.
  15. Munoz C, Bobadilla F, Fuenzalida H, Goldner R, Sina B. Congenital glomangioma of the breast: type 2 segmental manifestation. *Int J Dermatol.* 2011;50(3):346-349.  
<https://doi.org/10.1111/j.1365-4632.2010.04565.x>