

Pulmonary Tuberculosis mimicking a right Eventration on Radiography: The falsity of single view radiograph in the diagnosis of a precursor of pulmonary disease: A Case Report

Ogunkoya JO¹, Adesuyi YO²

¹Chest Unit, Babcock University Teaching Hospital, Ilishan Remo, Ogun State, Nigeria.

²Chest unit, Babcock University Teaching Hospital, Ilishan Remo, Ogun State, Nigeria.

Submitted: 12th March 2021

Accepted: 19th April 2021

Published: 30th June 2021

Abstract

Background: The diaphragm is one of the most important muscles of respiration in the body separating the abdomen from the thorax. Abnormalities of the diaphragm could be congenital or acquired, morphological or functional while pulmonary infection e.g. pulmonary tuberculosis, is implicated in its etiology.

Case presentation: A 63-year-old man with six weeks' history of cough productive of yellowish sputum. Chest X-ray showed a uniform well-circumscribed opacity in the right lower lobe abutting on or in continuum with the right diaphragm consistent with a diaphragmatic hump. Sputum Gene Xpert was positive for Mycobacterium tuberculosis. Chest CT scan revealed bilateral lymph node enlargement with hyperdense lesions in the anterior basal segment of the right lower lobe and medial bronchopulmonary segments of the right middle lobe. He was treated for 6 months with first-line anti-tuberculosis drugs with a good outcome.

Discussion: The incidence of the diaphragmatic hump on chest radiograph worldwide and among Nigerians is unknown. The association of diaphragmatic hump with chest infection has been well document. The association of diaphragmatic hump with pulmonary tuberculosis is uncommon.

Conclusion: A high index of suspicion is needed to diagnose pulmonary tuberculosis with atypical clinical and radiological presentations. Such prompt diagnosis will aid the treatment of the disease.

Keywords: Aneurysm, Computerized Tomographic Scan, Diaphragm, Diaphragmatic hump, Eventration, Hodgkin's lymphoma, Magnetic resonant imaging, Morgagni hernia

Background

The diaphragm is one of the most important muscles in the body (1). It is the most important muscle of respiration in the body (2). It is one of the muscles in the body that is in continuous activity, the other being the heart muscle. It is a

skeletal muscle under the direct control of the respiratory center in the brain stem. It is strategically located in the body as it separates abdominal contents from structures in the thoracic cavity (2). Abnormalities of the diaphragm can be unilateral rarely bilateral, are

Correspondence:

Ogunkoya John O.

Chest Unit,

Babcock University Teaching Hospital, Ilishan Remo, Ogun State, Nigeria.

+2348077503998; ogunkoyaj@babcock.edu.ng

commoner on the left (1, 3, 4). Most unilateral diaphragmatic abnormalities are asymptomatic (1). However, when symptomatic often present with dyspnea and hiccups. Bilateral diaphragmatic abnormalities when they occur are often characterized by disorders of ventilation leading to respiratory failure (3).

Some diaphragmatic abnormalities include hernia, paralysis, and diaphragmatic hump (3). Common causes of diaphragmatic humps or eventrations on chest radiographs include Morgagni hernia, dilated right atrium, primary lung mass, anterior mediastinum mass, lymph nodes (Hodgkin's lymphoma), aneurysm, lung cysts, and abscesses (3, 4).

The association of diaphragmatic abnormalities on chest radiographs with chest infection has been well documented (3). However, there had not been documented evidence of its association with pulmonary tuberculosis. Individuals with diaphragmatic hump had been treated for pulmonary tuberculosis in the past [8]. Common clinical features of pulmonary tuberculosis include productive cough of more than 3 weeks, weight loss, hemoptysis, night sweats, and prolonged low-grade fever (5).

The diagnostic imaging modalities useful in their assessment are abdominal/ chest ultrasound, plain chest radiograph, Computerized tomography, and Magnetic Resonant Imaging (6, 7).

Case report

Mr. NW is a 63 years old retired oil industry worker who presented with a complaint of six weeks' history of cough that was initially productive of thick yellowish sputum. No associated hemoptysis. The cough became worse on lying down on his back mostly at night. No known relieving or aggravating factor. There was no history of contact with anyone with chronic cough, no significant weight loss, chest pain, fever, or excessive sweating. He had previously been diagnosed and treated with amlodipine, hydrochlorothiazide, and Lipitor as hypertensive about 27 years before presentation. There was no recent change in medications and the patient has been compliant with medications and scheduled clinic visits. There was no history

of breathlessness, palpitation, orthopnoea, easy fullness, leg or facial swellings. There was also no history of cigarette smoking and took red wine occasionally.

Physical examination revealed an elderly man not in any obvious respiratory distress with oxygen saturation in room air of 95-97%. He was not pale, he was afebrile and had grade 2 finger clubbing. He had no peripheral lymph node enlargement and no pedal edema. The respiratory rate was 26 cycles per minute, the trachea was central with reduced chest expansion in the left lower lung zone. Breath sound was absent in the right lower lung zone but vesicular in other lung zones. Pulse rate was 78 beats per minute, regular and full volume, synchronous with other peripheral pulses with a thickened arterial wall. No raised jugular venous pressure, Blood pressure was 136/76 mmHg, apex beat was in the 6th left intercostal space, lateral to the left midclavicular line. 1st and 2nd heart sounds were present.

He was conscious, oriented in time, place, and person. The speech was coherent. Memory was preserved. There were no motor or sensory abnormalities seen and no obvious cranial nerve palsy.

An initial diagnosis of pulmonary tuberculosis was made to rule out primary lung carcinoma. Investigations that were conducted included full blood count, erythrocyte sedimentation rate (ESR), plain chest radiograph, Chest Computerized tomographic scan (CT scan), sputum microscopy, culture, and sensitivity (m/c/s), and sputum GeneXpert. He was given a week appointment for a review of investigation results.

He came for follow-up a week later with worsening cough and progressive weight loss and the result of investigations. Full blood count revealed mild normocytic, normochromic anemia (PCV = 29.9%), and normal total white cell count with relative lymphocytosis. ESR was 76mm/hr. The chest radiograph showed bilateral hilar lymphadenopathy and homogeneous well-circumscribed roundish opacity in the right lower lobe abutting on the right diaphragm consistent with a diaphragmatic hump (*Figure 1*).

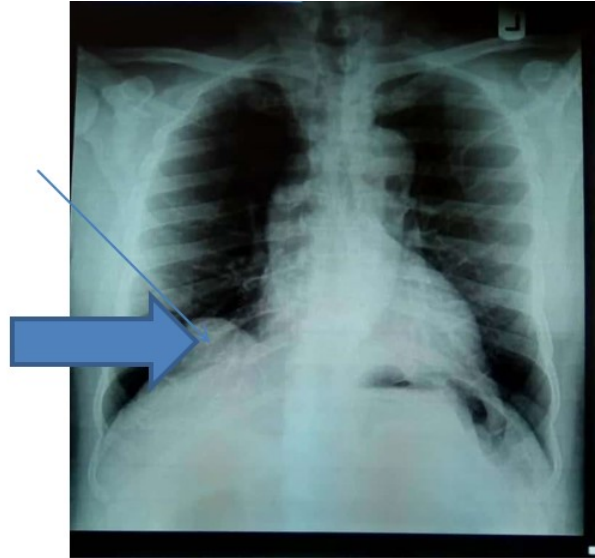


Figure 1: Plain Chest X-ray of the chest of the index case in posteroanterior view showing bilateral hilar lymphadenopathy and homogeneous well-circumscribed roundish opacity in the right lower lobe abutting on the right diaphragm.

Sputum GeneXpert result detected the presence of Mycobacteria tuberculosis (MTB-TB) sensitive to rifampicin. Sputum m/c/s revealed no bacteria growth after 48 hours of incubation. He was commenced on anti-tuberculosis drugs for 6 months. Chest CT scan revealed bilateral lymph

node enlargement with hyperdense streaky lesions in the anterior and posterior basal segment of the right lower lobe and medial bronchopulmonary segments of the right middle lobe (Figure 2 & 3).

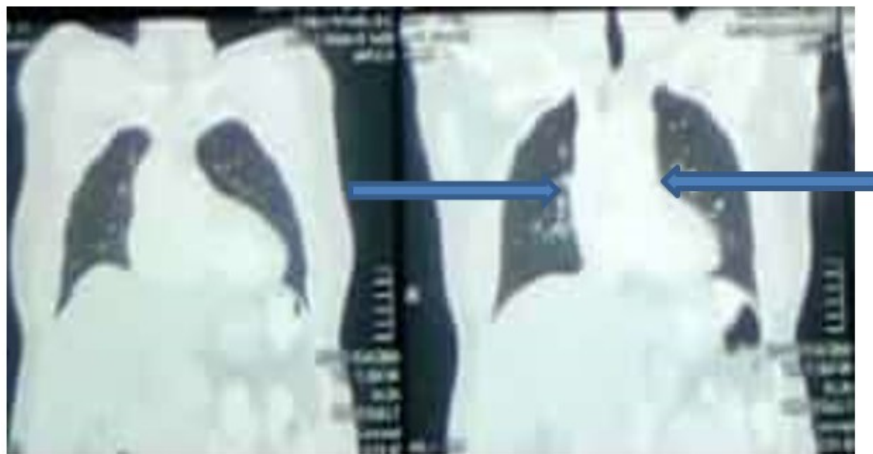

Figure 2: Chest C T scan of the chest of the index case coronal lung window view showing hilar lymphadenopathy.

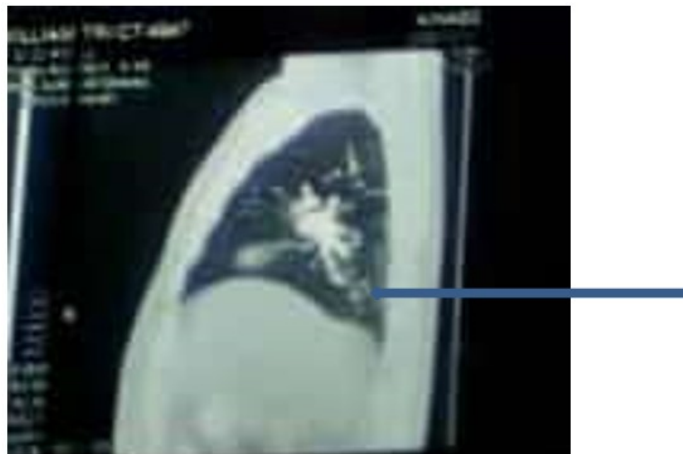

Figure 3: Sagittal view of Chest C T scan of the chest of the index case showing streaky hyperdense lesion in the posterior bronchopulmonary segment of the right lower lobe

He was commenced on anti-tuberculosis drugs for 6 months. He was on oral rifampicin 600mg daily, isoniazid 300mg daily, pyrazinamide 1,5g daily and ethambutol 800mg daily for the first two months, and rifampicin with isoniazid for the remaining 4 months. When he came for follow-up 4 weeks after commencement of anti-tuberculosis drugs, the cough had completely resolved and the patient had gained 4.5kg of body weight. He completed 6 months of anti-tuberculosis medications and was asked to do a new chest radiograph and come for follow-up in the chest clinic but he defaulted.

Discussion

The incidence of the diaphragmatic hump on chest radiographs worldwide and among Nigerians is unknown. A study done by Ogbole et al in Ibadan discovered that some undergraduates have an asymptomatic diaphragmatic hump on chest radiograph during routine pre-university admission screening (8). The association of diaphragmatic hump with chest infection has been well documented (3). However, there had not been documented evidence of its association with pulmonary tuberculosis. He further opined that some of these students with diaphragmatic hump were, however, diagnosed with pulmonary tuberculosis (8). The incident case is novel in our hospital record-showed clinical variation in cough presentation as against dominant symptom of

hiccups and dyspnoea commonly associated with diaphragmatic disorders (9).

The timely demonstration of mycobacteria in the sputum would ensure early diagnosis and commencement of adequate effective treatment thereby avoid physiological ordeals the patient would go through in the process of seeking a cure.

The incident patient lacked typical clinical but rather atypical radiological features of pulmonary tuberculosis (10). The location of chest X-ray findings in the lower lobe is completely not in line with usual findings in pulmonary tuberculosis in immune-competent individuals (8,10). He also had elevated electrolyte sedimentation rate value in conformity with a chronic disease like pulmonary tuberculosis (11,12).

Conclusion

A high index of suspicion is needed to diagnose pulmonary tuberculosis with atypical clinical and radiological presentations. Such prompt diagnosis will aid the treatment of the disease, thereby avoiding irreversible damage to the lungs and the pleural. Prognosis is good if prompt treatment is instituted.

Declarations

Ethical approval

Ethical approval and consent to participate in this study were obtained from the patient.

Consent for Publication

The authors hereby give consent for the publication of our work under the creative commons CC Attribution-Non-commercial 4.0 license.

Conflict of Interest

The authors have no conflict of interest to declare.

Funding

The authors received no funding for this research.

Authors' Contributions

OJO was responsible for the concept, literature search, drafting, and review of the manuscript. AYO was responsible for the literature search and review of the manuscript.

References

1. Yeh HC, Halton KP, Gray CE. Anatomic variations and abnormalities in the diaphragm seen with US. *Radiographics*. 1990 Nov;10(6):1019-30. <https://doi.org/10.1148/radiographics.10.6.2259759>
2. Dubé BP, Dres M. Diaphragm dysfunction: diagnostic approaches and management strategies. *Journal of clinical medicine*. 2016 Dec;5(12):113. <https://doi.org/10.3390/jcm5120113>
3. Qureshi, A. Diaphragm paralysis. In *Seminars in respiratory and critical care medicine*. 2009 July;30(03): 315-20. <https://doi.org/10.1055/s-0029-1222445>
4. Baz AA, Aglan AA, Mohammed SA, Sabri YY. Diagnostic accuracy of the trans-abdominal ultrasound in the assessment of dysfunctional hemidiaphragm due to non-pulmonic etiology. *Egyptian Journal of Radiology and Nuclear Medicine*. 2020 Dec;51(1):1-1. <https://doi.org/10.1186/s43055-020-00257-4>
5. Adetokunboh O, Oluwasanu M, Balogun TA. Burden of Tuberculosis in nine sub-Saharan African countries. *The international journal of Tuberculosis and Lung Diseases* 18(S11): November 2014, S135-S135.
6. Leow CK, Lau WY. Hepatoma, paroxysmal dyspnea, and diaphragmatic hump. *Canadian Journal of Surgery*. 1997 Feb;40(1):12.
7. Sabri YY, Hussein SA, Baz AA, Aglan AA. Ultrasonographic evaluation of the

- diaphragm. *Egyptian Journal of Bronchology*. 2019 Dec;13(5):690-8. https://doi.org/10.4103/ejb.ejb_73_19
8. Ogbole GI, Agunloye AM, Adeyinka AO. Are routine chest radiographic examinations of students in Nigerian Universities still relevant? An imaging perspective. *J Med Med Sci*. 2012;3:780-3.
 9. Wu L, Shi J, Chen Q, Jiang G. Congenital multiple eventrations of the right diaphragm in adulthood. *The Journal of thoracic and cardiovascular surgery*. 2014 Jan 15;148(2):735-6. <https://doi.org/10.1016/j.jtcvs.2013.12.053>
 10. Al Ubaidi BA. The radiological diagnosis of pulmonary tuberculosis (TB) in primary care. *J Fam Med Dis Prev*. 2018;4:073. <https://doi.org/10.23937/2469-5793/1510073>
 11. Nurli Naim. Result Analysis of Erythrocyte Sedimentation rate (ESR) For Tuberculosis (TB) patients with anti-tuberculosis Drug. *Intern Journal of Science and Healthcare Research*. April- June 2019;4(2):143-8.
 12. Oliva VM, Cezário GA, Cocato RA, Marcondes-Machado J. Pulmonary tuberculosis: hematology, serum biochemistry and the relation with the disease duration. *Journal of Venomous Animals and Toxins including Tropical Diseases*. 2008;14(1):71-81. <https://doi.org/10.1590/s1678-91992008000100006>