

Epstein-Barr virus DNA Detection in patients with gastric adenocarcinoma in a Nigerian Tertiary Health Centre

Zarami AB,¹ Chiwar H,² Bata MG,³ Nggada HA,¹ Pindiga UH¹

ABSTRACT

Background: Epstein-Barr virus (EBV)-associated adenocarcinoma constitutes 10% of gastric carcinomas worldwide. The EBV-positive adenocarcinoma has a unique genomic aberration with a low mutation burden and thus carries a good prognosis. The distinct salient genomic features have provided a guide to targeted therapy and the possibility of a clinical trial for emerging drugs in EBV-positive gastric adenocarcinomas. We retrospectively reviewed ten cases to determine the frequency of this association in our environment. **Methods:** The study was an analytical case-control study. Non-probably purposive sampling method was adopted; ten formalin-fixed and paraffin-embedded tissue blocks from surgically resected gastric adenocarcinoma seen at the Histopathology Department of the University of Maiduguri Teaching Hospital were selected and used. The PCR was done at National Trypanosomiasis Centre, Kaduna using 129 bp primers. The patient biodata and EBV status were entered into a computer and analysed using SPSS version 23. Proportions were calculated using the Chi-square test and a p-value of <0.05 was considered statistically significant. **Results:** Ten cases were retrieved. There were 6 females and 4 males with F:M ratio of 3:2 and a mean age of 52.7 ± 10.26 SD with an SE of 0.661. Seventy percent of the cases were positive for EBV while 30% were negative. Four out of the 6 females were positive for EBV DNA and 3 out of the 4 males were positive for EBV DNA. Fifty percent of the positive cases were found within their 4th decade of Life. There was no statistical significance between the histological types and EBV status ($p=0.467$). **Conclusion:** The study has shown a high frequency of EBV-DNA detection in patients with gastric adenocarcinoma in our environment, with 50 % occurring in the 4th decade of life. We recommend a further study with larger sample size and analysis of exome and genome sequencing of EBV in patients with gastric adenocarcinoma to increase our understanding of its prognosis and treatment.

Keywords: EBV-DNA, PCR, Gastric adenocarcinoma, Targeted immunotherapy.

¹Dept of Histopathology University of Maiduguri Teaching Hospital. ²Dept of Medical Laboratory Sciences, University of Maiduguri Teaching Hospital. ³Dept of Surgery, University of Maiduguri Teaching Hospital

Corresponding Author:

Zarami Abba Bakar, Dept of Human Pathology
Tel: +2347035969496
email:abbabukarzarami51@yahoo.com

Date Submitted 25th May 2022

Date Accepted 18th June 2022

Date Published online 30th June 2022

Introduction

Gastric cancer is the 4th most frequent neoplasm accounting for 6.8% of all cancers and the second leading cause of death from cancer worldwide.¹ Over 70% of gastric cancers occur in developing countries and half of the world's total occurs in Eastern Asia, mainly China.^{1,3} Incidence of 4.5% with a mortality rate of 4.1% have been reported in Africa and it was ranked the 9th most common cancer.¹ In Nigeria, 2% and 19% incidence and mortality rates respectively were reported even though most of the data from the country were hospital-based, there is a possibility that it has been under-reported.^{4,8}

The Cancer Genome Atlas project has proposed four molecular subtypes of gastric adenocarcinoma: Epstein-Barr virus (EBV)-positive gastric carcinoma, microsatellite unstable tumours, genomically stable gastric carcinoma (diffuse type) and chromosomal

Access this article online

Quick Response Code



website:www.bornomedicaljournal.com

DOI: 10.31173/bomj.bomj_2207_19



instability gastric carcinoma (intestinal type). EBV is one of the oncogenic viruses implicated in many cancers. Its positivity in gastric adenocarcinoma was significantly higher in diffuse histological type, males gender, patients <40years, and mostly non-antral sites.⁹⁻¹²

This study aims to characterize the histological types of gastric adenocarcinoma using the three-tier Lauren classification system into intestinal, diffuse and indeterminate types (which corresponds to the respective WHO 2016 gastric cancer classification) and to detect the presents of EBV-DNA using Polymerase Chain Reaction (PCR) on archived tissue biopsies of patients diagnosed with gastric adenocarcinoma. To the best of our knowledge, this is an index report in our environment.

Methods:

The study was an analytical case-control study. Non-probably purposive sampling method was adopted.

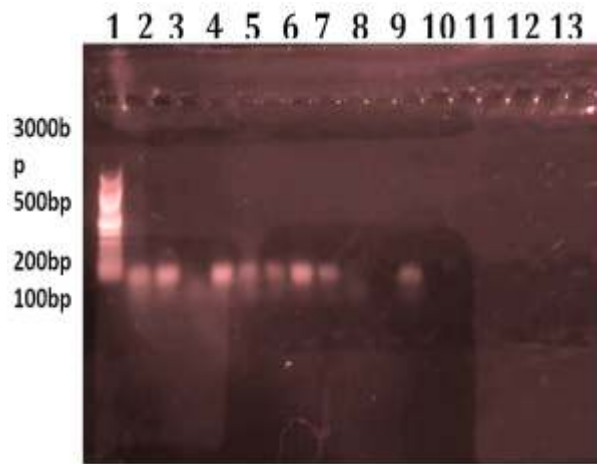
Twelve formalin-fixed and paraffin-embedded tissue blocks from surgically resected gastric adenocarcinoma were retrieved from the archives (2018-2020) of the Histopathology department at the University of Maiduguri Teaching Hospital. Two cases out of the 12 gastric adenocarcinomas found were excluded from the study because the corresponding tissue blocks were missing. The remaining ten cases histologically diagnosed with gastric adenocarcinoma were used. The patients' bio-data and the histological types (Lauren classification) were retrieved from the request card and the cancer register. A 129 bp primer sequence with 10 nucleotides each for forward (primer 1) and reversed (primer 2) sequence was adopted from a previous study.¹³ The study was reviewed and approved by the Research and Ethical Review Committee of the University of Maiduguri Teaching Hospital (UMTH/REC/985).

Sequence	Amplicon size base pair (bp)
Primer	
primer 1 5'-CCAGACAGCAGCCAATTGTC-3'	129 bp
primer 2 5'-GGTAGAAGACCCCTCTTAC-3'	
DNA was extracted from each paraffin block and conventional PCR was carried out at the National Trypanosomiasis centre, Kaduna state. The DNA extraction and PCR protocols were done in the following steps.	
1. A ten-micrometer thick section of each block of formalin-fixed paraffin-embedded tissue (FFPET) was collected in a 1.5 ml microcentrifuge tube, dewaxed by adding 1 ml of xylene and vortexed for 10 seconds then centrifuged at full speed (14000rpm) for 2 minutes at room temperature.	5. After incubation at 100°C for 10 minutes, the samples were centrifuged at 12,000 rpm for 10 minutes.
2. The supernatant was removed by pipetting and to the pellet 1ml, ethanol (100%) was added and then mixed by vortexing to remove residual xylene from the sample.	6. The supernatant containing DNA was stored at -20°C and then used as the template for the PCR.
3. The tubes were opened and incubated at room temperature for the ethanol to evaporate.	7. The primer for PCR adopted was the 129 bp region of the internal repeat, EBNA-1 (Epstein-Barr virus nuclear antigen-1). ¹³
4. To the 10µm thick tissues (dewaxed) kept in 1.5mL microcentrifuge tubes, 0.5mL of DNA extraction solution was added guided by the manufacturer's instructions.	8. The template DNA 1µg was mixed with 10 X buffer (100 mM Tris-HCl, 500 mM KCl, 15 mM MgCl ₂), 10 mM dNTP mixture, and 1.5 µU Taq-polymerase, which constituted the master mix.
	9. The prepared samples were loaded into the Appendoft cyler, where the sample DNA was denatured at 95°C for 5 minutes and then subjected to 35 cycles of amplification.
	10. Each cycle consisted of 30 seconds of denaturation at 95°C, 30 seconds of annealing at 58°C, and 1 minute of extension at 72°C. Finally, the mixture samples were extended at 72°C for 5 minutes.



11. B95-8 cell line (EBV-transformed leukocytes) as a positive control and a mixture of samples without DNA served as a negative control.
12. The products of PCR were electrophoresed in a 2% agarose gel and then stained with ethidium bromide. It was then visualized and photographed. (figure 1)

Results:



Key:
 Lane 1-PCR Ladder
 Lane 2-Positive control
 Lane 3-12 test samples
 Lane 13-Negative control

Figure 1: Shows Photographs of PCR Products

Table 1: Shows mean age, gender (sex), Age Groups and EBV status (n=10)

	Frequency	Percent
Mean age± SD	52.7 ± 10.26	
Sex		
F	6	60.0
M	4	40.0
Total	10	100.0
Age Group (years)		
40-49	5	50.0
50-59	3	30.0
60-69	1	10.0
≥70	1	10.0
Total	10	100.0
EBV status		
EBV-	3	30.0
EBV+	7	70.0
Total	10	100.0

Table 2: Cross-Tabulation of Age Groups with EBV Status

Age Groups		EBV Status		Total (%)
		EBV-	EBV+	
Age Groups	40-49	0	5	5(50)
	50-59	2	1	3(30)
	60-69	1	0	1(10)
	≥70	0	1	1(10)
Total		3	7	10(100)



Table 3: Cross Tabulation of gender and EBV Status

		EBV Status		Total
		EBV-	EBV+	
Sex	F	2	4	6
	M	1	3	4
Total		3	7	10

Table 4: Cross Tabulation of Morphological Types of Gastric Adenocarcinoma with EBV Status

		EBV Status		
		EBV-	EBV+	Total
Morphological Types	Adenocarcinoma Diffuse	3	5	8
	Adenocarcinoma Intestinal	0	2	2
Total		3(30%)	7(70%)	10(100%)

Discussion:

Epstein-Barr virus (EBV) was discovered to be associated with gastric adenocarcinomas based on histopathological features since 1990.¹⁴ The EBV-positive adenocarcinomas have a good prognosis and unique genomic aberration with low mutation burden. It responds to immunotherapy especially immune checkpoint targeted therapy, unlike EBV-negative adenocarcinomas.^{14,15,16} In this study 10 cases of gastric adenocarcinoma were retrospectively reviewed and analysed. There were 6 females and 4 males with a male-to-female ratio of 2:3 and a mean age of 52.7±10.27 years (table 1 and 3). Seventy percent of the cases show positive EBV DNA, by PCR using 129 primers (figure 1). These findings are in keeping with many reported cases that showed an average age of 58 years with a higher frequency of EBV-positive cases in men.^{9,14} Frequency of 10% was reported in Korea, Hong Kong, China and Japan.¹³ These findings were at variance with the current study, probably because of our small sample size.

Epstein-Barr Virus positive adenocarcinomas are mostly found in the proximal stomach and can invade the submucosa. However, the rate of lymph node metastasis was reported to be low.¹⁴ Its positivity in gastric adenocarcinoma was significantly higher in diffuse histological type.⁹⁻¹² In this study 8 cases were classified as diffuse type and 2 cases were intestinal type adenocarcinoma. Five out of the 8 cases of diffuse and the 2 of the intestinal type were EBV-positive adenocarcinoma, (Tables 1 and 4). There was no statistically significant relationship between the various histological types

of gastric adenocarcinoma and EBV status ($p=0.469$), probably due to the small sample size, (table 4).

The median survival of EBV-positive adenocarcinoma was 8.5 years compared to only 5.3 years in EBV-negative cancer.¹⁴ Therefore; there is a need to treat EBV-positive adenocarcinoma because of its high median survival duration.¹⁴

Many studies have indicated a negative correlation between p53 antibody and EBV positivity and thus, it has been shown that EBV-positive gastric adenocarcinoma lacks the TP 53 mutation.^{13,14} In reported cases, EBV-positive gastric adenocarcinomas, have shown remarkable response to newer immunotherapy drugs.^{17,18,19,20} All cases of EBV-positive gastric cancers certainly displayed CDKN2A (P16 gene) as promoter hypermethylation and lack MLH1 hypermethylation found in MSI-associated cancers.^{9,19} These distinct salient genomic features have provided a guide to targeted therapy and the possibility of a clinical trial for emerging drugs in EBV-positive gastric adenocarcinoma.^{9,19,20}

Conclusion: The study has shown a high frequency of EBV-DNA detection in patients with gastric adenocarcinoma in our environment and 50% occurred in the 4th decade of life. We recommend a further study with larger sample size and analysis of exome and genome sequencing of EBV in patients with gastric adenocarcinoma to increase our understanding of its prognosis and treatment.

Conflict of interest - None

Funding - None



References:

1. Ferlay J, Soerjomataram I, Dikshit R, Rser S, Mather C, Rebelo M, et al. Cancer incidence and mortality worldwide: Sources, methods and major patterns in GLOBOCAN 2012. *Int J Cancer* 2015; 136(5): E359-386.
2. Ferlay J, Colombet M, Soerjomataram I, Mathers C, Parkin DM, Pineros M, et al. Estimating the global cancer incidence and mortality in 2018: GLOBOCAN sources and methods. *Int J Cancer* 2019;144(8):1941-1953.
3. Katherine D Crew, Alfred I Neugut. Epidemiology of gastric cancer. *World J Gastroenterol* 2006; 12(3): 354-362.
4. Abdulkareem FB, Onyekwere CC, Awolola NA, Ajekigbe AT. Clinicopathological study of malignant gastric tumours in Lagos. *Niger J. Hosp Prac*, 2010; 20(2): 49-54.
5. Muhammed AZ, Edino ST, Ochicha O, Gwarzo AK, Samaila AA. Cancer in Nigeria: a 10 year analysis of the Kano Cancer Registry. *Nig J Med* 2008;17(3): 280-284.
6. Okobia MN, Aligbe JU. Pattern of malignant diseases at the University of Benin Teaching Hospital. *Trop Doct* 2005; 35(2): 91-92.
7. Tijjani MB, Borodo MM, Samaila AA. Upper Gastrointestinal Tract Cancers at Endoscopy in Kano, North-Western Nigeria. *Nig Med Pract*. 2009; 56: 1-2.
8. Abubakar AB, Ibrahim AG, Bata MG, Nggada HA. Pattern of gastric cancer in north-eastern Nigeria: A clinicopathological study. *J Chinese Clin Med* 2010; 5(4):211-215.
9. Bass AJ, Thorsson V, Shmulevich I, Raynolds SM, Bernard B, Hinouse T, et al. Comprehensive molecular characterization of gastric adenocarcinoma. *Nature* 2014; 513(7517): 202-209.
10. de Lima MA, Ferreira MU, Borros MP, Pardini MC, Ferrasi AC, Rabenhors HB. Epstein-Barr Virus associated gastric carcinoma in Brazil: comparison between in situ hybridization and PCR detection. *Braz J Microbiol* 2012; 43 (1): 393-404.
11. Camargo MC, Murphy G, Koriyama C, Pfeiffer RM, Kim W H, HerreraGoepfert R, et al. Determinants of Epstein-Barr virus-positive gastric cancer: an international pooled analysis. *British J Cancer* 2011; 105: 38-43.
12. Ambinder RF, Mann RB. Detection and characterization of Epstein-Barr virus in clinical specimens. *Am J Pathol* 1994; 145:239-252.
13. Lee MA, Hong YS, Kang JH, Lee KS, You JY. Detection of Epstein-Barr virus by PCR Band expression of LMP, p53, CD44 in gastric cancer. *Korean J Intern Med* 2004; 19 (1): 43-47.
14. Sun K, Jia K, Huifang LV, Wang S, Wu Y, Lei H, et al. EBV positive gastric cancer: Current knowledge and feature perspective. *Front Oncol* 2020; 583463.
15. Gasenko E, Isajevs S, Camargo MC, Offerhaus GJA, Polaka I, Gulley ML, et al. Clinicopathological characteristics of Epstein-Barr virus-positive gastric cancer in Latvia. *Eur J Gastroenterol Hepatol* 2019; 31(11):1328-33.
16. Dai C, Geng R, Wang C, Wong A, Qing M, Hu J, et al. Concordance of immune checkpoints within tumor immune contexture and their prognostic significance in gastric cancer. *Mol Oncol* 2016; 10(10):1551-8.
17. Kim ST, Cristescu R, Bass AJ, Kim KM, Odegaard JI, Kim K, et al. Comprehensive molecular characterization of clinical responses to PD-1 inhibition in metastatic gastric cancer. *Nat Med* 2018; 24(9):1449-58.
18. Liu X, Choi MG, Kim K, Kim KM, Kim ST, Park SH, et al. High PD-L1 expression in gastric cancer (GC) patients and correlation with molecular features. *Pathol Res Pract* 2020; 216(4):152881.
19. Jacome AA, Lima EM, Kazzi AI, Chaves GF, Mendonca DC, Maciel MM, et al. Epstein-Barr virus-positive gastric cancer: a distinct molecular subtype of the disease? *Rev Soc Bras Med Trop* 2016; 49(2):150-7.
20. Rodriquenz MG, Roviello G, D'Angelo A, Lavacchi D, Roviello F, Polom K. MSI and EBV Positive Gastric Cancer's Subgroups and Their Link with Novel Immunotherapy. *J Clin Med* 2020; 9(5):1427.

Cite this Article as: Zarami AB, Chiwar H, Bata MG, Nggada HA, Pindiga UH. Epstein-Barr virus DNA Detection in patients with gastric adenocarcinoma in a Nigerian Tertiary Health Centre. *Bo Med J* 2022;19(1):1-5 **Source of Support:** Nil, **Conflict of Interest:** None declared

