

## Correlation of Clinical and Ultrasound Findings in Ocular Trauma at The University of Benin Teaching Hospital, Nigeria

<sup>1</sup>Ademola A. Adeyekun, <sup>1</sup>Sally N. Ozougwu, <sup>1</sup>Efe E. Efe-Aluta, <sup>2</sup>Juliet N. Ese-Onakewhor

### ABSTRACT

**Background:** The eye is very vulnerable to external injuries and accidents. Clinical evaluation is usually the first line in management of ocular trauma. Ultrasonography is a useful tool for evaluating ocular trauma due to its ready availability and relative safety. The eye provides a perfect acoustic window for ocular imaging, being a fluid filled structure. Data on level of correlation between clinical and sonographic findings in ocular trauma is sparse in the Nigerian literature.

**Objectives:** The aim of this study was to correlate clinical findings with sonographic assessment in patients who presented with ocular trauma at the University of Benin Teaching Hospital (UBTH), Benin-City, Nigeria.

**Materials and Methods:** Eighty patients were studied, over an eight-month period, September-April 2014. After history taking and clinical examination, and following informed consent, each patient was scanned with a linear array probe of transducer frequency 5-12MHz (SONACE X4; Medison Inc, Korea), using the closed eye technique. Data was analyzed with Statistical Package for the Social Sciences, version 17 (SPSS Inc; Chicago USA). Statistical tests were considered significant at 'p' level < 0.05.

**Results:** The modal age group involvement was 18-35 years, and most of the causes of ocular trauma were work related. The right eye was more commonly involved (44 patients or 56.4%). The most common source of injury was intraocular foreign bodies (26 patients or 32.5%). Vitreous hemorrhage was the most common sonographic finding (36 patients or 45.0%). Ultrasound examination significantly identified more abnormalities (50 cases or 62.5%), compared with clinical or ophthalmologic assessment alone (27 cases or 33.8%).

**Conclusion:** Ultrasound significantly identified more abnormalities than ophthalmologic examination. The posterior segment was more involved than the anterior, with vitreous hemorrhage as the most common abnormality. Ultrasound findings correlated significantly with clinical findings.

### Keywords: ocular trauma, ultrasound, correlation

Department of <sup>1</sup>Radiology and <sup>2</sup>Ophthalmology, University of Benin Teaching Hospital, Benin City.

#### Corresponding Author

Ademola A. Adeyekun  
e-mail: ademolaadeyekun@gmail.com  
Phone: +234-8055464948

#### Access this article online

Quick Response Code



website: [www.bornomedicaljournal.com](http://www.bornomedicaljournal.com)

DOI: 10.31173/bomj.bomj\_166\_16

### Introduction

Worldwide, there are approximately 1.6million people who are blind from eye injuries with 2 million bilaterally visually impaired and 19 million with unilateral visual loss<sup>1</sup>

The maximum incidence of ocular trauma is among young adults with a second peak in the elderly<sup>2</sup> Males are more affected with profound socioeconomic implications, in



terms of loss of productivity, especially in young people<sup>3,4</sup>.

Ocular injuries can be mechanical or non-mechanical. Mechanical eye injuries can be penetrating or blunt, caused by sharp objects and high velocity foreign bodies from blasts. Non-mechanical injuries may result from physical contacts or chemicals for example, combat sports, household items and implements<sup>5,6</sup>.

Ocular injuries may also be closed or open, depending on the integrity of the cornea and sclera. Open globe injuries involve full thickness laceration of the corneoscleral wall. Clinical manifestation may be mild, moderate or severe and can range from conjunctiva hemorrhages and abrasion, corneal abrasion, penetrating eye injuries, lid abrasion and avulsion, and orbital fractures. The anterior eye segment, (cornea, conjunctiva, trabecular meshwork, iris and crystalline lens) is more vulnerable to direct trauma and sometimes there may be combined anterior and posterior segment (retina, choroid and optic nerve) involvement<sup>7-9</sup>.

The ability of ultrasound to evaluate the eye and adjacent structures (the globe and orbit) in a non-invasive and rapid manner is of tremendous value in the setting of a busy emergency department. There is better posterior segment access with ultrasound; therefore, more abnormalities are detected when it is used in conjunction with clinical assessment.

This study set out to correlate the clinical and ultrasound findings in ocular trauma.

### Materials and Methods

This was a descriptive cross-sectional study. Eighty patients who presented with ocular trauma at the Accident and Emergency unit of the University of Benin Teaching Hospital (UBTH), and met the inclusion criteria were studied. Informed consent was obtained,

either from the subjects or their relations. Patients with globe rupture and those who refused to give consent were excluded. The integrity of the corneoscleral wall was used to differentiate open from closed injuries.

For those selected, demographic data, including age, sex and occupation were obtained. After history taking, the procedure was thoroughly explained to each subject or the accompanying relative, clinical assessment was done, and the findings recorded.

Ocular ultrasonography was performed for the consecutively selected cases with the patient in the supine position, using the close eye technique.

A high resolution 7.5 – 10 MHz curvilinear probe (SONOACE X4 machine; Medison Co. South Korea). Transmission gel was applied to the eyelid and patient told to look straight ahead. Scanning was done in both sagittal and transverse planes. Depth and gain were adjusted for optimal imaging. Globe structures were studied; including the cornea, anterior segment and its contents, the posterior segment as well as retro bulbar structures.

After the examination, the transmission gel was gently cleaned off.

Data obtained was entered into a spreadsheet and analyzed using the Statistical Package for Social Sciences (SPSS version 17; SPSS Inc, Chicago, IL USA). Parametric data was summarized using means and standard deviation. Dichotomous variables were presented as frequency counts and charts. Statistical test of significance of the hypothesis between anterior and posterior segment involvement, ultrasound and clinical assessment was done using Chi-square test and Pearson's correlation coefficient. At 95% confidence interval, the level of significance was set at probability values less than or equal to 0.05.



**Results**

**Socio-Demographic Characteristics**

Ocular ultrasound was carried out on 80 subjects with ocular trauma. The mean age of study subjects was 32.2 ± 18.4years (range 1-80years). There were more males (67 or

83.8%) than females (13 or 16.2%); this was not statistically significant: p=0.271. A quarter of the subjects (19 or 23.7%) were engaged in manual occupations

**Table 1: Socio-demographic characteristics of subjects**

	Frequency (n = 80)	%
<b>Age Group</b>		
0-12	17	21.3
13-17	1	1.2
18-35	34	42.5
36-59	23	28.8
> 60	5	6.2
<b>Sex</b>		
Male	67	83.8
Female	13	16.2
<b>Educational Level</b>		
None	2	2.5
Primary	32	40
Secondary	24	30
Tertiary	22	27.5
Widowed	2	2.6
<b>Occupation</b>		
Students/Pupils	19	23.8
Manual Occupations	19	23.7
Trader/Private Business	12	15
Other non-specific occupations	30	37.5

**Ophthalmic Findings**

Clinically, foreign bodies from blasts (26 cases or 32.5%), blows (20 cases or 25.1%), and RTA (18 cases or 22.5%) were the common causes of eye injuries. The right eye was more involved (45 cases or 56.3%), than the left (34 cases or 42.5%). Bilateral involvement was

seen in only 1 case (1.2%). Sonographically, vitreous hemorrhage (36 cases or 45.0%) was the most common finding, followed by retinal detachment (13 cases or 16.3%), and foreign bodies (16 cases or 20.0%).



**Table 2: Sonographic findings of eye injuries among subjects**

Variable	Frequency (N=80)	%
<b>Affected Eye</b>		
Right	44	56.4
Left	33	42.3
Both	1	1.3
<b>Sonographic findings</b>		
Vitreous haemorrhage	36	45.0
Foreign bodies	16	20.0
Retinal detachment	13	16.3
Aqueous haemorrhage	11	13.8
Lens subluxation	11	13.8
Lens dislocation	11	13.8
Incidental cataract findings	6	7.5
Choroidal detachment	5	6.3

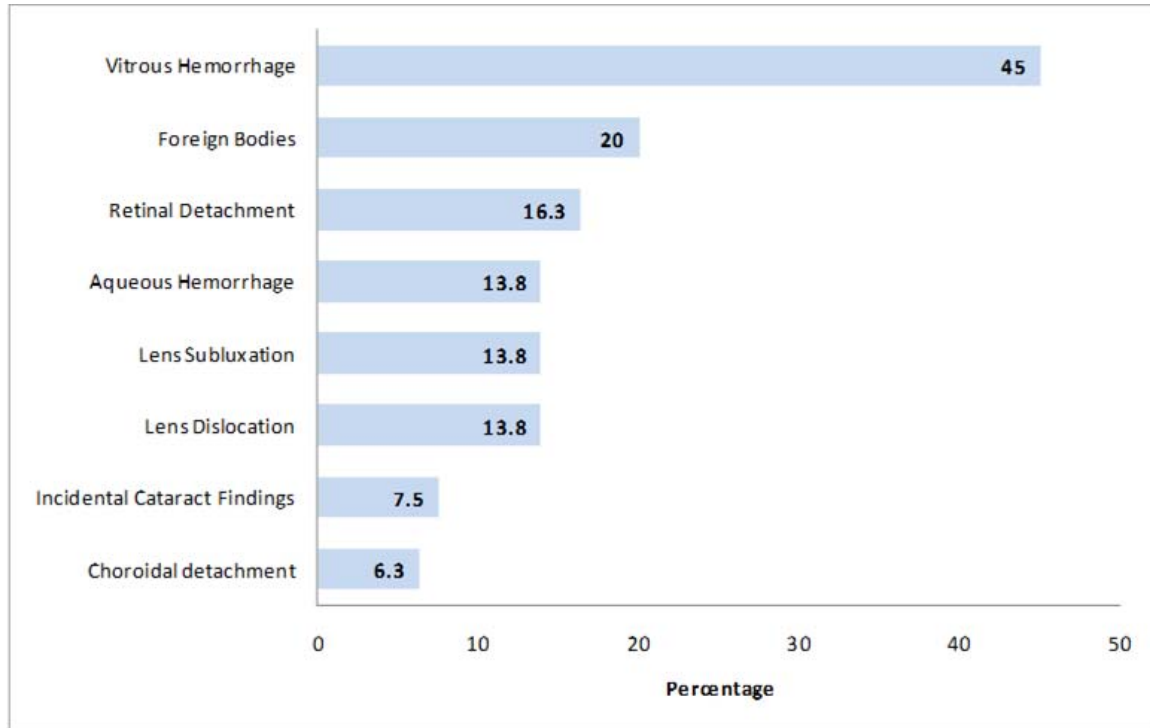
Injuries due to blows, and those from gunshots were more common on the left, resulted in choroidal detachment than injuries from RTAs, falls; 25 cases or 31.3%. The association of injuries due to blows and gunshots with vitreous haemorrhage was not statistically significant;  $p=0.065$  respectively.

#### **Comparison of Ophthalmologic and Ultrasound Findings**

Vitreous haemorrhage, intraocular foreign bodies, retinal detachment were commonly identified by ultrasound but missed on clinical

(ophthalmologic) assessment. For both eyes, the posterior segment was significantly more involved (38 cases or 47.5%) than the anterior (23 cases or 28.8%);  $\chi^2=5.96$ ;  $df=1$ ;  $p=0.015$ . The use of ultrasound identified significantly more positive findings; (50 or 62.5%) compared with ophthalmologic assessment (27 or 33.8%);  $\chi^2=13.24$ ;  $p=0.000$ ; Figure 1 and Table 3, Figures 2 and 3. Using Pearson's coefficient, the correlation between ultrasound and clinical assessment of the eye following trauma was fairly good and significant ( $r=0.5$ ;  $p=0.000$ ).





**Table 3: Comparison of ultrasound and ophthalmologic findings in the eyes among subjects (N=80)**

Variable	Ultrasound assessment n (%)	Ophthalmologic assessment n (%)
Lesion(s)		
Yes	50 (62.5)	27 (33.8)
No	30 (37.5)	53 (66.2)
Total	80 (100)	80 (100)

$\chi^2 = 13.24$ ;  $df = 1$ ;  $p = 0.000$ ;  $r = 0.5$ .



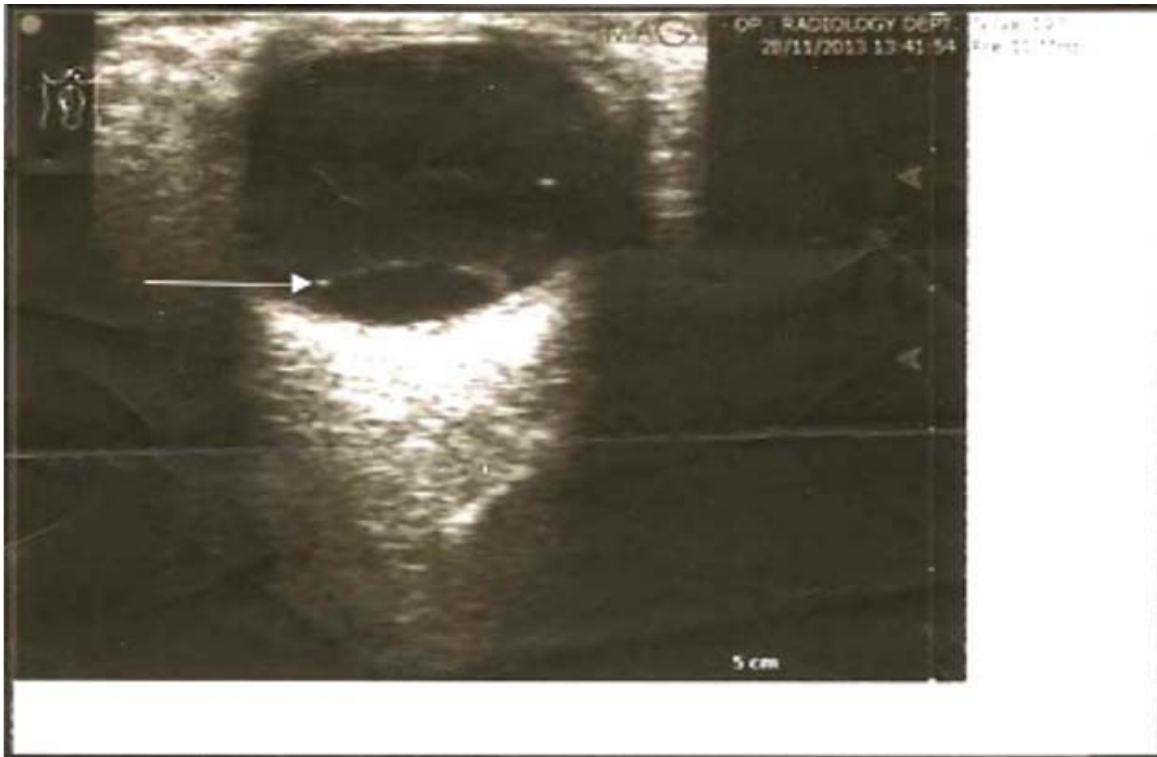

Figure 2: Transverse ultrasound image showing choroidal detachment (arrow)

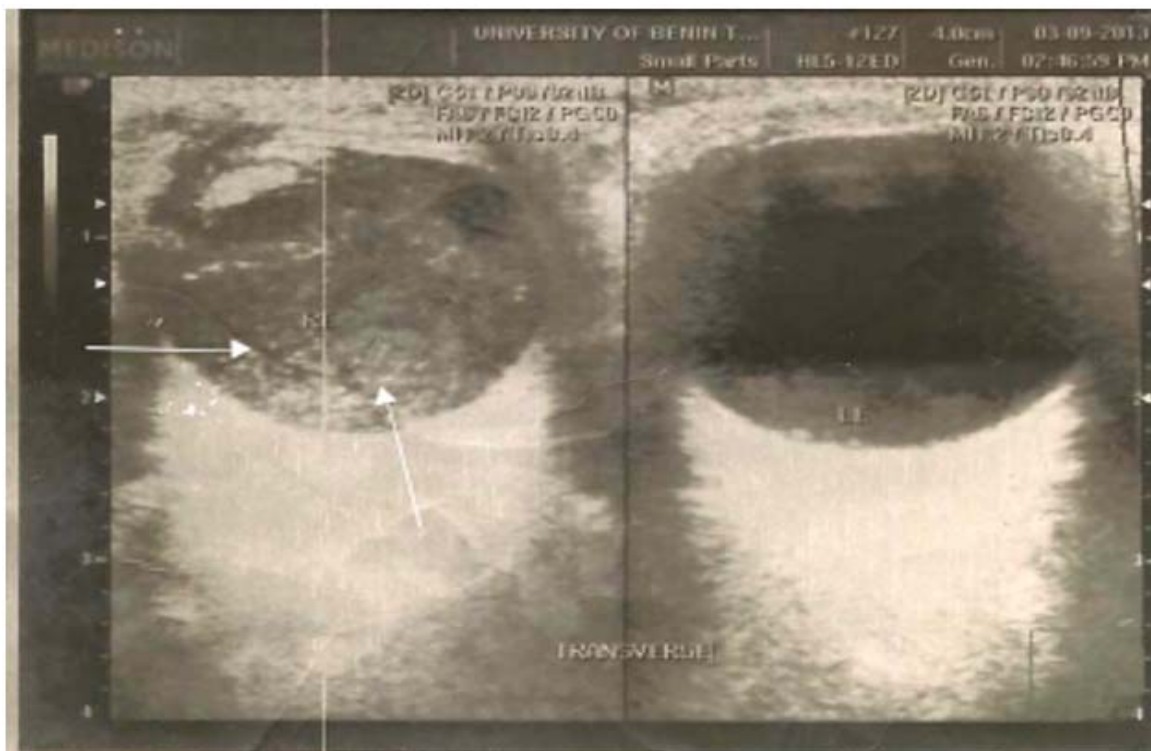


Figure 3: Ultrasound image showing bright echoes in the posterior chamber (arrow), due to vitreous haemorrhage.

## Discussion

Clinical examination has been the traditional method of ocular examination, especially in trauma cases. Ultrasound in recent times has been employed as an adjunct to clinical examination, especially for greater detection of posterior segment lesions. Therefore, there is need to compare the degree of correlation of the two methods.

In this study the male gender was five times more involved in ocular trauma than females. This is consistent the pattern reported by Nzeh et al in Nigeria<sup>10</sup>, and Cao et al in China<sup>11</sup>. Also, studies by Jahangir and Sadaf in Pakistan (12,13) and in Egypt by Soliman et al (14), reported that males in age group 18 - 45years were mostly involved. The greater involvement of men in this age group is due to higher levels of risk taking among adult males which makes them suffer more from occupational injuries, blows, vehicle related crash injuries.

The present study found occupational mishap more than domestic injuries as causes of ocular trauma, with figures of 38 (47.5%) and 27 (33.8%) respectively. These results are consistent with the reports of Voon et al in Singapore (15), and Cao et al in China. (11) Okojie et al (16), similarly reported this in a study on health status of sawmill workers in Benin City.

The situation in the present report is aggravated by the lack of awareness of safety practices in the work environment. Also injuries from blasts and high velocity foreign bodies, like shrapnels, made up most of the cases reported (55 or 68.8%) around the work place due to non-usage of protective eye devices like goggles, again due to lack of awareness of use of safety devices like goggles in the workplace, as some think that wearing such will be inconvenient and interfere with activity.

Vitreous haemorrhage (45cases or 56.3%), intraocular foreign bodies, from blasts and shrapnels, (16 cases or 20%) and retinal detachment (13 cases or 16.3%) were the most common findings in this study. Others included aqueous haemorrhage, lens subluxation and dislocation. Identical findings were reported by Blaivas et al (17) in the USA, Kwong et al (18) in Korea and Sadaf et al (13) in Pakistan. However, Nzeh et al (10), Ukpomwan et al (19), both in Nigeria, in their ultrasound studies on ocular trauma reported retinal detachment as their most common finding. Late presentation characteristic of patients in the Nigerian environment could be the cause for this disparity because insidious haemorrhage would have had time to organize and lead to sequel of retinal detachment.

In this study 39 (48.8%) patients could not have detailed ophthalmic assessment due to non-cooperation, probably due to pain, and hyphemia that made access to the posterior segment difficult. Subsequent ultrasound assessment revealed vitreous haemorrhage (13 or 33.3%), followed by intraocular foreign bodies (9 or 23.1%), and retinal detachment (12 or 15.47%). These were mainly posterior segment findings, and therefore support previous reports on the superiority of ultrasound over clinical examination especially in posterior segment. (17)

The use of ultrasound significantly identified more findings in the eye (50 cases or 62.5%), where compared with clinical findings (27 cases or 33.8%). Also a statistically significant and positive correlation was found between ultrasound and ophthalmic assessment of the eye following trauma ( $r = 0.5$ ;  $p = 0.000$ ). Previous reports have highlighted the superiority of ultrasound over clinical assessment, as well as good correlation



between the two methods. (19) Out of a total of 53 (66.2%) patients in whom ophthalmologic examination was negative, 24 had one or more positive findings on ultrasound. As earlier slated, these involved posterior segment lesions, such as vitreous hemorrhage, foreign bodies, and retinal detachment. One contributory factor to the greater sensitivity of ultrasound may be that access to the posterior chamber is restricted during clinical examination.

### Conclusion

Ultrasound correlated well with clinical findings in ocular trauma. There were more abnormalities detected on ultrasound than clinical examination. Posterior segment findings were more than anterior segment abnormalities. One contributory factor to the greater sensitivity of ultrasound may be that, in emergencies, access to the posterior segment is restricted during clinical examination as a result of pain. Ultrasound examination is recommended as an adjunct to clinical examination in ocular trauma.

### References

1. Gyasi ME, Adjuik MA, Amaaku W. Epidemiology of Ocular Injuries in the Upper East Region of Ghana. *Ghana Medical Journal* 2007; 41: 171-175.
2. Schroeder WF. Open Globe Injuries: Epidemiological Study of Two Eye Clinics in Germany, 1981-1991. *Croatia Medical Journal* 2004; 45: 268-274.
3. Mc Gwinn G, Owsley C, Xie A. Rate of Eye injury in the United States. *Arch Ophthalmol* 2005; 123: 970-976.
4. Emmem GA, Uwemedumbuk SE. Prevalence of Ocular Injury in a Teaching Hospital in South-South Nigeria. *Adv Trop Med Pub Health Int.* 2012; 2: 102-105.
5. Pieramici DJ, Sternberg P, Aaberg T et al. A system for Classifying Mechanical Injuries of the Eye (Globe). *Am J Ophthalmol* 1997; 23: 820-831.
6. Ilsar M, Chirambo M. Ocular Injuries in Malawi. *Br J. Ophthalmol* 1982; 66; 145-8
7. Kuhn F, Morris R, Witherspoon CD et al.. A Standard Classification of Ocular Trauma. *Graefes Arch Clin Exp Ophthalmol* 1996; 6:399-403.
8. Pieramichi DJ, Sternberg P, Aaberg T et al. A System for Classifying Mechanical Injuries of the Eye (Globe). *Am J Ophthalmic* 1997; 23: 820-831.
9. Coyler MH, Chun DW, Bower KS et al.. Perforating Globe Injuries During Operation Iraq Freedom. *Ophthalmology* 2008; 115:2087 - 93
10. Nzeh DA, Owoeye JF, Ademola-Popoola DS et al. Sonographic Evaluation of Ocular Trauma in Ilorin, Nigeria. *Eur J Ophthalmol* 2006; 16: 453-7
11. Cao H, LiL, Zhang M. Epidemiology of Patients Hospitalised for Ocular Trauma in the Chaosan Region of China: 2001-2010. *Arch Ophthalmol* 2011; 10: 137.
12. Jananagir T, Butt HN, Hamza U et al. Pattern of Presentation of factors leading to Ocular Trauma. *Pak J Op hthalmol* 2011; 27: 96-101.
13. Sadaf L, Saima A, Imran HD. Imaging in Ocular Trauma. Optimizing the Use of





- Ultrasound and Computerized Tomography. Pak J Ophthalmol 2011; 27:3.
14. Soliman MM, Macky TA. Pattern of Ocular Trauma in Egypt. Graefes Arch Clin Exp Ophthalmol 2008; 246: 205-12.
15. Voon LI, See J, Wong TY. The Epidemiology of Ocular Trauma in Singapore: Perspective from the Emergency Service of a Large Tertiary Hospital. Eye 2001; 15:75-81.
16. Okojie OH, Egbagbe E, Kadiri I. An Epidemiological Study of the Health Status of Sawmill Workers in Benin City, Edo State Nigeria. J. Med Biomed Research 2003; 2:76-81.
17. Blaivas M, Theodore D, Sierzenski PR. A Study of Bedside Ocular Ultrasonography in the Emergency Department. Acad Emergency Medicine 2002; 9:791-99.
18. Kwong JS, Murk PL, Lin DT et al. Real Time Sonography in Ocular Trauma. Am J Roentgenol 1992; 158: 179-82.
19. Ukponmwan CU, Marchie TT. Ultrasound Diagnosis of Orbito-Ocular Diseases in Benin-City, Nigeria, Niger Postgrad Med J. 2001; 8: 123- 6.

---

**Cite this Article as:** Ademola A. Adeyekun, Sally N. Ozougwu, Efe E. Efe-Aluta, Juliet N. Ese-Onakewhor. Correlation of Clinical and Ultrasound Findings in Ocular Trauma at The University of Benin Teaching Hospital, Nigeria. **Bo Med J 2019;16(2):** **Source of Support:** Nil, **Conflict of Interest:** None declared

---

