

Effects of Sildenafil Citrate On Testicular Histology and Sperm Count During Wound Healing Process in Diabetic Rats

Mohammed B. Mahre¹, Saidu I. Ngulde², Bukar Umaru², Fakilahyel M. Mshelbwala³, Dauda Yahy¹, Abubakar Waziri⁴, Aji T. Goni⁴, Bitrus Wampana¹

ABSTRACT

Background: This study was carried out to determine the effects of sildenafil citrate on morphology of the testes and spermatogenesis during wound healing process in diabetic rats. Eighteen adult male Wistar rats randomly divided into two groups (A and B) of 9 rats per group were treated orally with sildenafil citrate at a dose of 50 mg/kg for 21 days and or/single dose of intraperitoneal injection of insulin (10 IU). Before treatment, type 1 diabetes mellitus was induced in group A by a single intraperitoneal injection of alloxan (130 mg/kg) and a square-shaped wound measuring 1.5 cm² was created under anesthesia with ketamine at the dose rate of 50 mg/kg intraperitoneal injection on the dorsum of rats in all groups with the exception of 3 rats in group B. From each of the two groups (A and B), 9 rats were humanely sacrificed for histology and sperm count. This was done after the administration of the sildenafil citrate on day 21. The results of the study showed significant ($p < 0.05$) decrease in testicular and epididymal sperm head counts. Sections of the testes showed severe vacuolar degeneration of germinal epithelial cells in the seminiferous tubules in diabetic rats during the 21 days of treatment with sildenafil citrate. This indicates that sildenafil citrate may not have any protective effect against testicular injury due to wound healing process in diabetic rats.

Keywords: Diabetes, rats, sildenafil citrate, sperm count, testes, wound

¹Dept of Veterinary Physiology and Biochemistry;

²Dept of Veterinary Pharmacology and Toxicology;

⁴Dept of Veterinary Pathology, Faculty of Veterinary Medicine, University of Maiduguri, P.M.B. 1069, Maiduguri, Borno State, Nigeria

³Dept of Veterinary Pathology, College of Veterinary Medicine, Federal University of Agriculture, Abeokuta, Ogun State, Nigeria.

Corresponding Author

Mohammed B. Mahre


Department of Veterinary Physiology and Biochemistry, University of Maiduguri, P.M.B. 1069, Maiduguri, Borno State, Nigeria

Email: mbmahre@gmail.com +2348095002402

Introduction

Diabetes mellitus affects a large number of young men of reproductive age and erectile and ejaculatory difficulties arise due to vascular and neuropathic problems.¹ Research have shown that diabetes mellitus can lead to reduced sperm quality^{1,2} and wound healing also constitutes a great challenge in the diabetic patients.³ Fertility of the male may be compromised by stress factors resulting from the wound healing process which is related to immune system activation.⁴ Sildenafil citrate is a phosphodiesterase type-5 inhibitor, vasodilator agent that is used in the management of erectile dysfunction and primary pulmonary hypertension.⁵ Although sildenafil citrate has been develo-

Access this article online

Quick Response Code	website: www.bornomedicaljournal.com
	DOI: 10.31173/bomj.bomj_121_16



ped for erectile dysfunction and pulmonary hypertension, it now has other medical indications in diseases such as cardiovascular, spinal cord injury and type II diabetes mellitus.⁶ Several studies have indicated that sildenafil may exert a protective effect against testicular injury in rat models.⁷⁻⁹ Furthermore, it has been shown that administration of sildenafil citrate may also be useful against ischemic injury in other organs such as the liver, colon and brain.¹⁰ Pentoxifylline, another phosphodiesterase (PDE) inhibitor, has been shown to affect sperm quality and early embryo development.¹ It is likely therefore, that sildenafil citrate, also a PDE inhibitor, may affect sperm quality. Ejaculatory difficulties are also more common in diabetics although treatments such as Trucut testicular biopsy and intracytoplasmic sperm injection have improved the outlook for these patients. There are evidences that spermatogenesis is impaired in diabetic patients and affected individuals have a reduced sperm motility and semen volume.^{1,2} As a result, diabetes mellitus directly or indirectly causes a significant loss of fertility in men suffering from the disorder. Although, oral administration of sildenafil citrate has been reported to influence the male reproductive system, its effects on histology of the testes and sperm count during wound healing process in diabetic rats have never been investigated. Therefore, the aim of this study is to evaluate the effects of the oral administration of sildenafil citrate on histology of the testes and sperm count during wound healing process in diabetic rats.

Materials and Methods

Experimental Animals and Management

Eighteen adult male Wistar albino rats weighing between 140 g – 210 g were obtained and managed as described by Mahre *et al.*¹¹ This study was undertaken according to the

International Guiding Principles for Biomedical Research involving laboratory animals¹² and was approved by the Faculty Ethics Committee of the Faculty of Veterinary Medicine, University of Maiduguri, Nigeria.

Experimental Design

The experimental design in the current study was adapted from Mahre *et al.*,¹¹ Eighteen adult male Wistar rats weighing between 140 g – 210 g were randomly divided into two groups (A and B) of 9 rats per group and administered sildenafil citrate orally at a dose of 50 mg/kg for 21 days and or/single dose of intraperitoneal injection of insulin (10 IU). Before treatment, type 1 diabetes mellitus was induced in group A by a single intraperitoneal injection of alloxan monohydrate (130 mg/kg) after the rats were deprived of feeds for 18 hours. Type 1 diabetes mellitus was confirmed 3 days after administration of alloxan monohydrate through tail tipping using a glucometer as described by Meiton.¹³ Only rats with blood glucose level of 180 mg/dl and above were considered diabetic and used for the experiment. A square-shaped wound measuring 1.5 cm² was created under anesthesia with ketamine at the dose of 50 mg/kg intraperitoneal injection on the dorsum of rats in all groups with the exception of 3 rats in group B.¹¹

Histological Examination

From each group, 9 rats were humanely sacrificed for histology of the testes and spermatology. This was done after the administration of the sildenafil citrate on day 21.



Samples of the right testes (1 cm³) from each rat in each group were fixed in Bouin's solution for 24 hours and processed for paraffin sectioning.

The paraffin sections were cut at 5µm using the rotary microtome and stained with haematoxylin and eosin and evaluated histologically¹⁴ using a light microscope.

Sperm Counts

The left testes and epididymis from the aforementioned rats were dissected. The tunica albuginea was removed from each left testes before its homogenization in 5 mls of normal saline.

The head, body and tail of left epididymis were separately homogenized in 2 mls of normal saline. The sperm count per milliliter of the homogenate was done using a haemocytometer.¹⁵⁻¹⁷

The total sperm count per homogenate was determined using the formula; (volume of homogenate) × (count in 5 squares) × (0.05 × 10⁶).

Data analysis

Data obtained from the study was presented as mean ± standard deviation. Differences between group means were tested by Paired-Samples T test using statistical software IBM SPSS Statistics 22.

Values were considered significant at p < 0.05.

Results

Sperm Counts

There was a significant decrease in the testicular and epididymal sperm head counts (Table 1 and 2). Plate 1 shows a normal section of the testis (×100; H&E) and Plate 2 is a section of the epididymis containing scanty seminal fluid with few spermatozoa (×100; H&E). Plates 3, 4, 5, 6,7 and 7 shows sections of the testes with severe vacuolar degeneration of germinal cells in the seminiferous tubules in diabetic rats during the 21 days of treatment with sildenafil citrate and Plate 8 shows a section of the testis with severe uncanalized seminiferous tubules with vacuolar degeneration of germ cells.

Table 1: Effects of sildenafil citrate on sperm count of diabetic and non-diabetic Wistar albino rats (×10⁶)

Group A Diabetic rats	Group B Non diabetic rats
12.9±0.10 ^a	20.1±1.39 ^x
11.6±2.96 ^a	38.6 ±1.72 ^y
09.8±0.46 ^b	19.1±2.73 ^z

Values represent mean ± standard deviation of sperm head count by paired-samples t test analysis. Different superscripts indicate significant (p<0.05) different means between groups for sperm head count.




Table 2: Effects of sildenafil citrate on epididymal sperm count of diabetic and non-diabetic Wistar albino rats ($\times 10^6$)

	Group A Diabetic rats	Group B Non diabetic rats
Head	2.2 \pm 1.3 ^a	3.4 \pm 2.0 ^x
Body	0.7 \pm 0.9 ^b	1.1 \pm 1.3 ^y
Tail	4.0 \pm 1.3 ^c	6.3 \pm 2.0 ^z
Head	1.9 \pm 1.2 ^{a*}	5.9 \pm 3.6 ^{x*}
Body	0.6 \pm 0.8 ^{b*}	1.9 \pm 2.4 ^{y*}
Tail	3.6 \pm 1.2 ^{c*}	11.1 \pm 3.6 ^{z*}
Head	1.6 \pm 1.0 ^{dx}	3.2 \pm 1.9 ^{cx}
Body	0.5 \pm 0.7 ^{dy}	1.0 \pm 1.3 ^{cy}
Tail	3.1 \pm 0.9 ^{dz}	6.0 \pm 1.9 ^{cz}

Values represent mean \pm standard deviation of epididymal sperm count by paired-samples t test analysis. Different superscripts indicate significant ($p < 0.05$) different means between groups for sperm head count in the head, body and tail of the epididymis

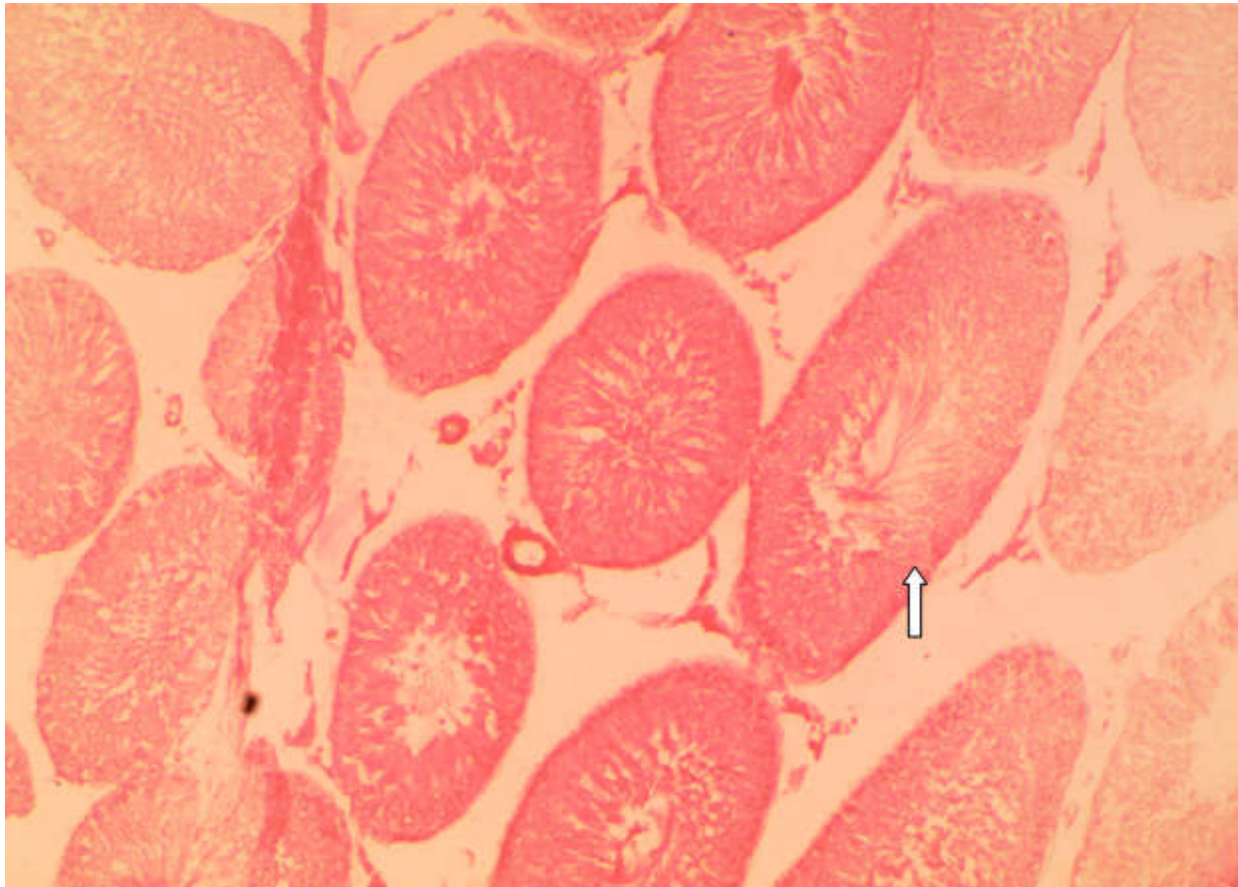


Plate 1: Section of the testis showing normal architectural arrangement of the seminiferous tubules (x100; H&E)

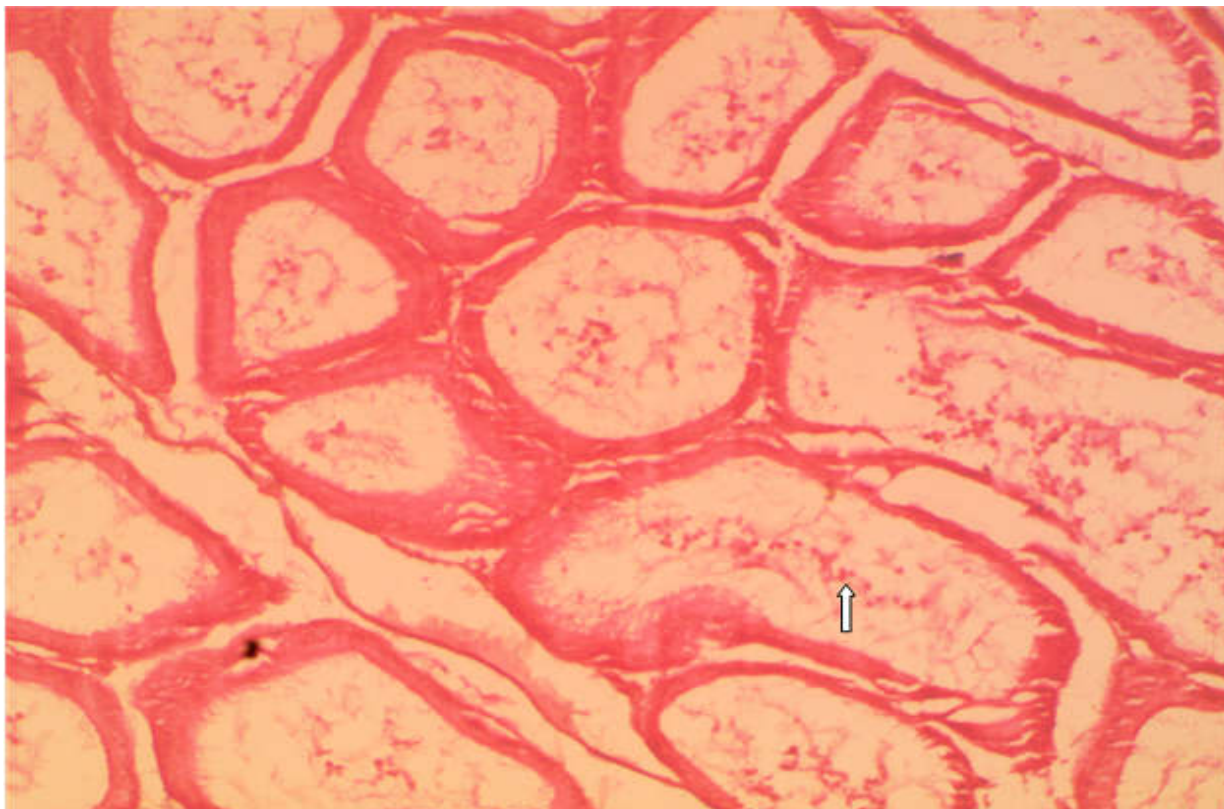

Plate 2: Section of the epididymis showing scanty seminal fluid with few spermatozoa (arrow) (x100; H&E)

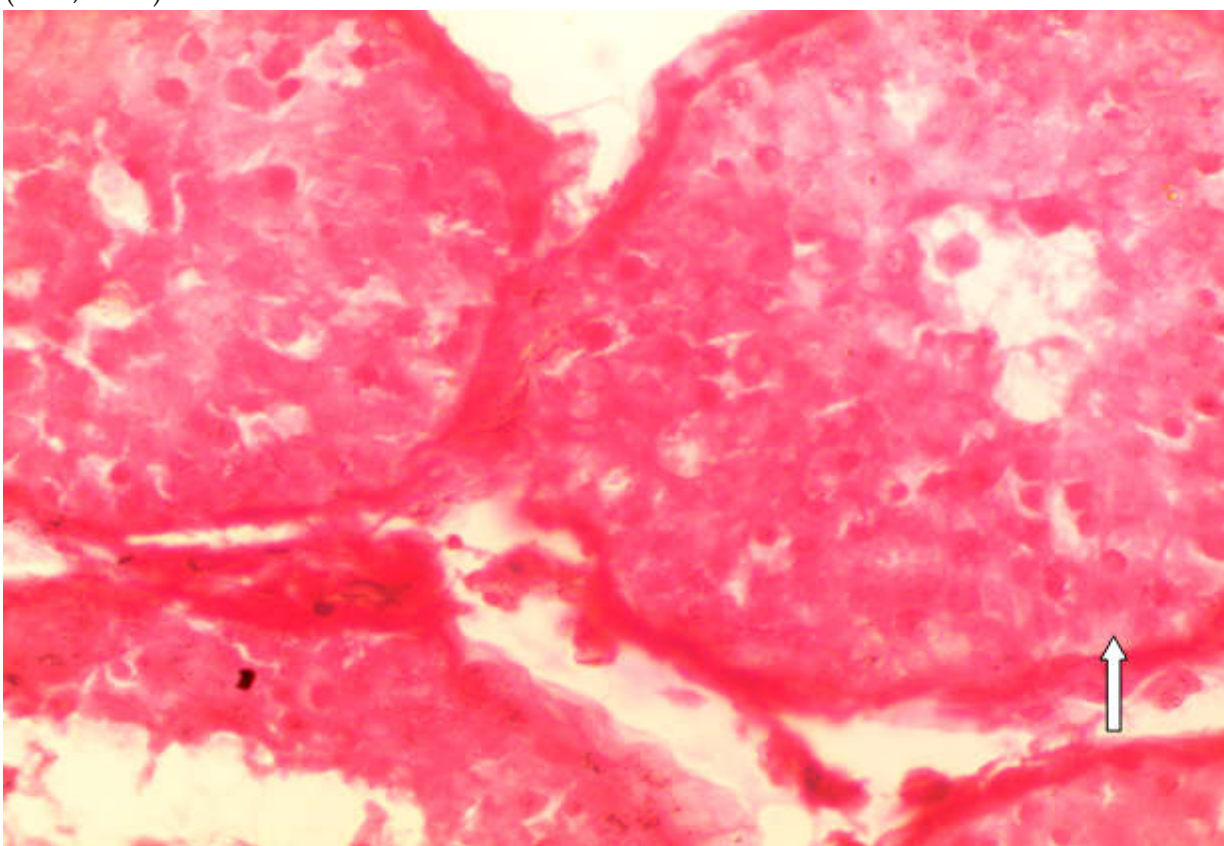


Plate 3: Section of the testis showing severe vacuolar degeneration of germinal cells (arrow) (x400; H&E)

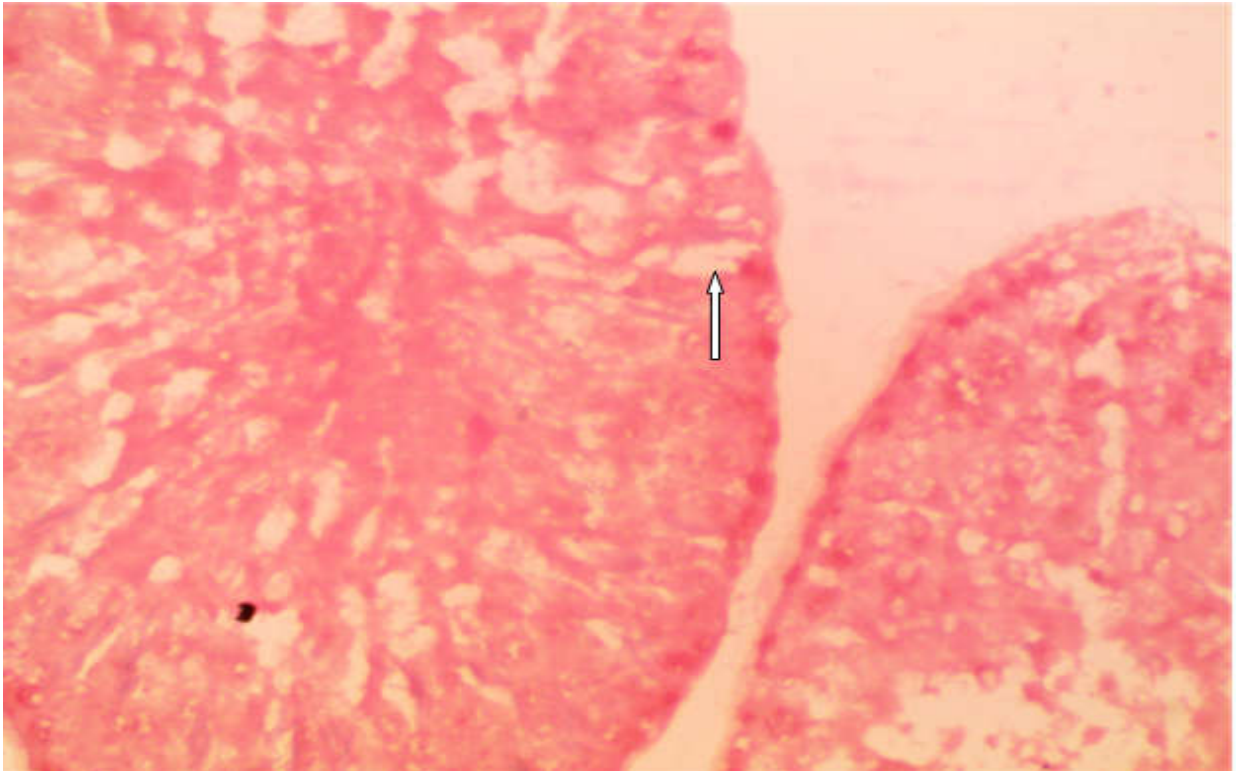


Plate 4: Section of the testis showing vacuolar degeneration of the germinal cells (arrow) (x400; H&E)

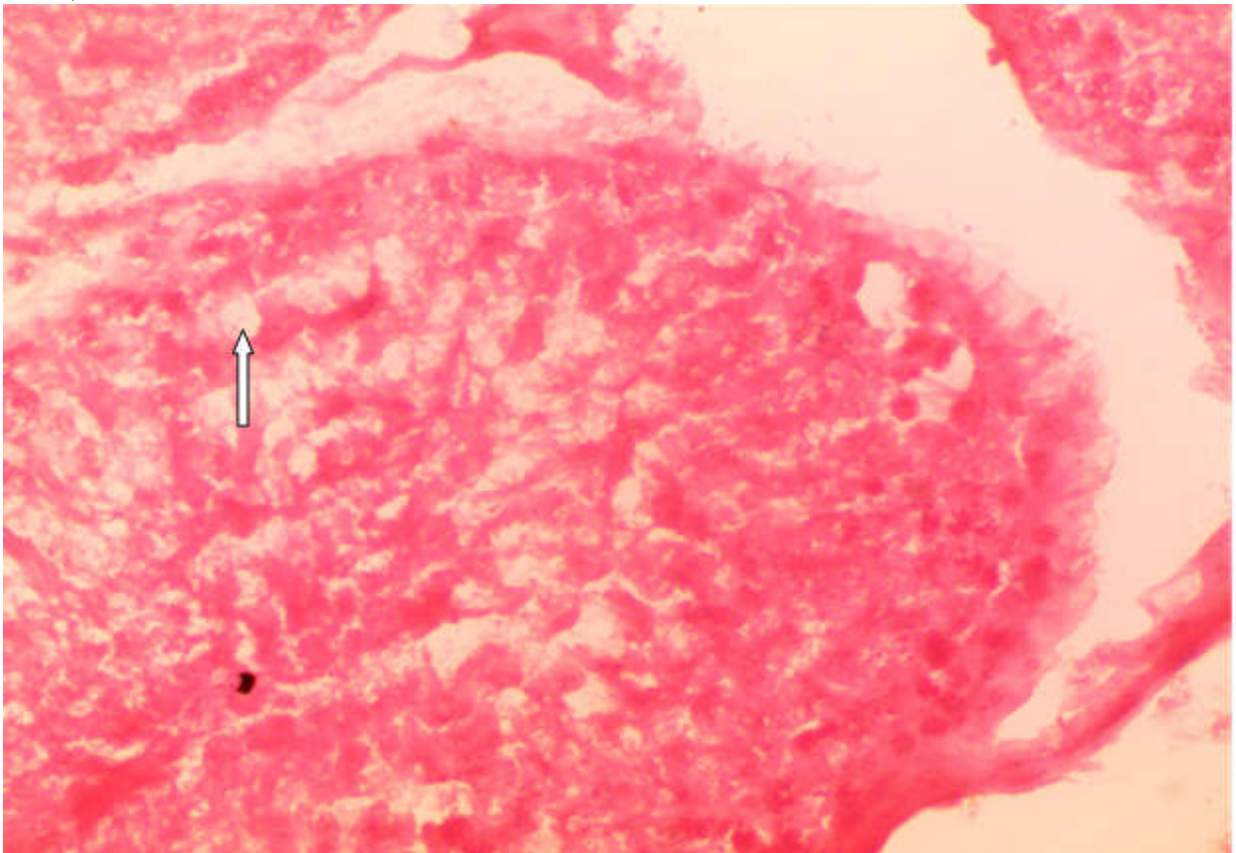


Plate 5: Section of the testis showing severe vacuolar degeneration of the germinal cells (arrow) (x400; H&E)

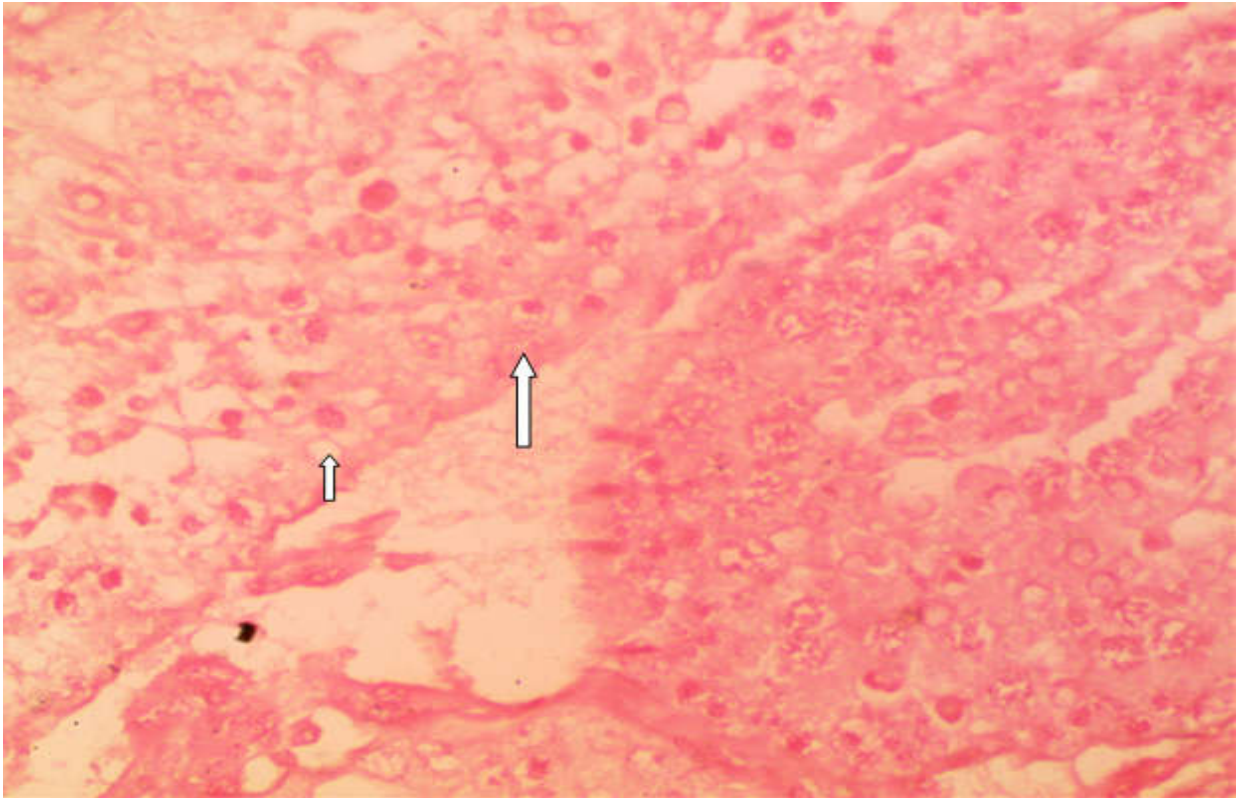


Plate 6: Section of the testis showing severe vacuolar degeneration of germinal cells in the seminiferous tubules (arrows) (x400; H&E)

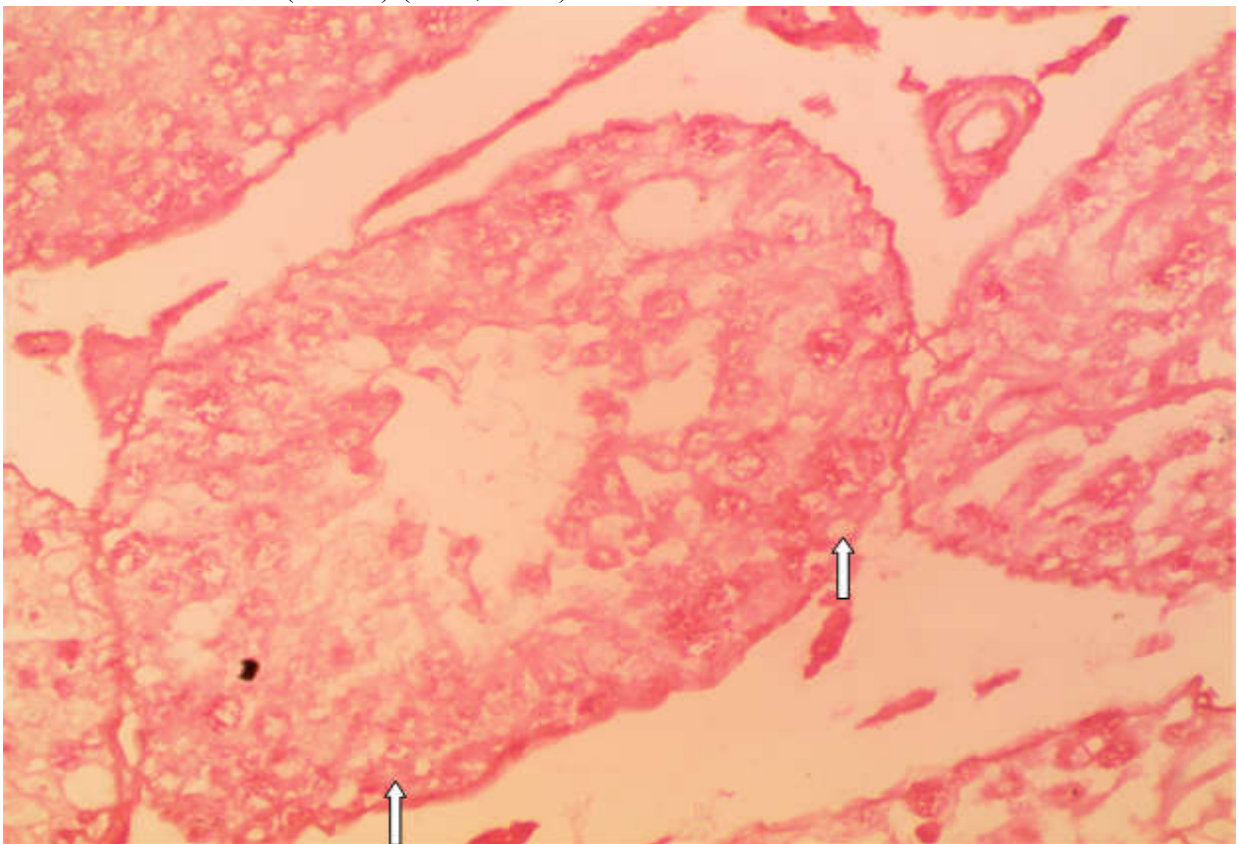


Plate 7: Section of the testis showing severe vacuolar degeneration of germinal cells in the seminiferous tubules (arrows) (x400; H&E)

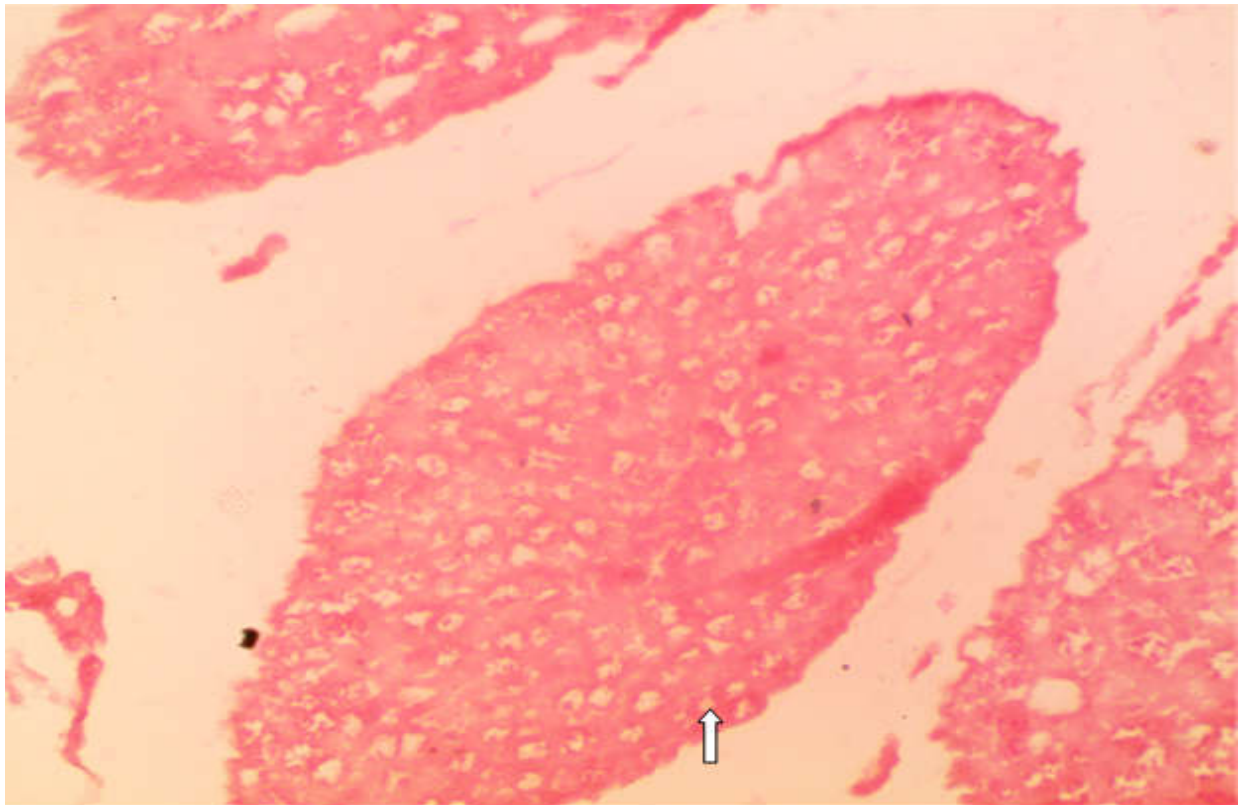


Plate 8: Section of the testis showing severe uncanalized seminiferous tubules with severely vacuolated germ cells (arrow) (x400; H&E)

Discussion

The decrease in testicular and epididymal sperm counts and the severe vacuolar degeneration of germinal cells in the seminiferous tubules observed in the present study may be an indication that sildenafil citrate does not have any protective effect *against* testicular injury during wound healing process in diabetic rats. This is in contrast to previous studies on normal rat model.^{7-9,18} The difference can be attributed to the hyperglycemic state of the diabetic rats investigated. As mentioned above, citing Brownlee¹⁹ and Muralidhara,²⁰ hyperglycemia can induce testicular oxidative stress and cause increase in the production of free radicals. Moreover, increased lipid peroxidation and decreased antioxidant enzyme concentration mainly impairs fertility in male with Type I diabetes mellitus.²¹ It is also important to note that

oxidative stress itself could mediate damage to plasma membrane, integrity of DNA and on germ cell which could leads to deterioration of sperm quality.²¹

The decrease in testicular and epididymal sperm counts seen in the present study may have resulted due to the severe vacuolar degeneration of germinal epithelial cells in the seminiferous tubules, known to be associated with diabetes in rats.²²⁻²⁵ It may also be due to changes caused by the wound healing process that affect the expression of various receptors associated with the cGMP or in the responsiveness of these receptors in the brain, which can cause damage to testicular tissues that lead to failure of spermatogenesis.²⁶ Alternatively, the inhibition of cGMP breakdown may produce changes in nitric oxide (NO) production via negative feedback mechanisms.²⁷

There are also considerable implications in terms of public health education and the need to inform recreational users of its potential side effects. These concerns make it all the more crucial to elucidate fully any effects sildenafil has on reproduction.¹

Conclusion

The results of the study showed significant decrease in testicular and epididymal sperm counts and sections of the testes showed severe vacuolar degeneration of germinal cells in the seminiferous tubules in diabetic rats during the 21 days of treatment with sildenafil citrate, and this may be an indication that sildenafil citrate may not have any protective effect against testicular injury during wound healing process in diabetic rats.

References

1. Glenn DR, McClure N, Lewis SE. The hidden impact of diabetes on male sexual dysfunction and fertility. *Human Fertility* 2003; **6** (4):174-179.
2. Condorelli RA, La Vignera S, Mongioi LM, Alamo A, Calogero AE. Diabetes Mellitus and Infertility: Different Pathophysiological Effects in Type 1 and Type 2 on Sperm Function. *Front Endocrinology* 2018; **9**:268.
3. Fahey TJ, Sadaty A, Jones WG, Baarber A, Smoller B, Shires GT. Diabetes impairs the late inflammatory response to wound healing. *Journal of Surgery Research* 1991; **50**:308-313.
4. Stürup M, Baer-Imhoof DR. Nash JJ, Boomsma B. When every sperm counts: factors affecting male fertility in the honeybee *Apis mellifera*. *Behavioral Ecology*, 2013; **24** (5):1192-1198
5. Kloner RA. Pharmacology and drug interaction effects of the phosphodiesterase-5 inhibitors: Focus on alpha-blocker interactions. *American Journal of Cardiology*, 2005; **96** (12):42-46.
6. Filho DW, Torres MA, Bordin AL, Crezcynski-Pasa TB, Boveris A. Spermatic cord torsion, reactive oxygen and nitrogen species and ischemia-reperfusion injury. *Molecular Aspect of Medicine*, 2004; **25**:199-210
7. Beheshtian A, Salmasi AH, Payabvash S, Kiumehr S, Ghazinezami B, Rahimpour S. Protective effects of sildenafil administration on testicular torsion/detorsion damage in rats. *World Journal of Urology* 2008; **26**:197-202.
8. Erol B, Tokgoz H, Hanci V, Bektas S, Akduman B, Yencilek F. Vardenafil reduces testicular damage following ischemia/ reperfusion injury in rats. *Kaohsiung Journal of Medical Sciences* 2009; **25**:374-380.
9. Özgür BC, Telli O, Yuceturk CN, Sarici H, Ozer E, Surer H, Kilinc AS, Hucumenoglu S, Eroglu M. The effect of sildenafil and udenafil on testicular damage following ischemia-reperfusion injury in rats. *Journal of Urology*, 2014; **192**(4):1272-1277.
10. Uzun H, Konukoglu D, Nuri MK, Ersoy EY, Özçevik S, Yavuz N. The effects of sildenafil citrate on ischemic colonic anastomotic healing in rats: its relationship between nitric oxide and oxidative stress. *World Journal of Surgery* 2008; **32**:2107-2113.
11. Mahre MB, Umaru B, Ngulde SI, William A, Atela EP, Patrick AA, Middah YH, Zangoma Y. Wound healing effects of sildenafil citrate in



- diabetic albino rats. Sokoto Journal of Veterinary Sciences 2017; **15**(1). 20- 26
12. Council for International Organizations of Medical Sciences and the International Council for Laboratory Animal Science. International Guiding Principles for Biomedical Research Involving Animals. Geneva 27, Switzerland: WHO 1211; 2012
 13. Meiton DA. Reversal of type 1 diabetes in mice. New England Journal of Medicine 2006; **355**(1):89 – 90.
 14. Faqi AS, Johnson WD, Morrissey RL, McCormick DL. Reproductive toxicity assessment of chronic dietary exposure to soy isoflavones in male rats. Reproductive Toxicology 2004; **18**:605–611.
 15. Almquist JO, Amann RP. Reproductive capacity of dairy bulls II. Gonadal and extragonadal sperm reserves as determined by direct counts and depletion trials, dimension and weight of genitalia. Journal of Animal Science 1961; **44**:1668-1678.
 16. Amann RP, Lambiase JT. The male rabbit III. Determination of daily sperm production by means of testicular homogenates. Journal of Animal Science 1969; **28**:369 – 374.
 17. Mahre MB, Umaru B, Ojo NA, Yahy D, Sa'idu A, Musa AS, Bukola OO. Phytochemistry of methanolic seed extract of *Abrus precatorius* and its effect on spermatogenesis in rats. Journal of Research in Forestry, Wild Life and Environment 2017; **9**(1):44 – 57.
 18. Sivasankaran TG, Udayakumar R, Elanchezhyan C, Sabhanayakam S. Effect of sildenafil citrate (Viagra) and ethanol on the Albino rat testis: A scanning electron microscopic approach. Cell Biology International. 2008; **32** (2): 293-297
 19. Brownlee M. Glycosylation products and the pathogenesis of diabetic complications. Diabetes Care 1992; **15**:1835-1843
 20. Muralidhara SB. Early oxidative stress in testis and epididymal sperm in streptozotocin-induced diabetic mice: its progression and genotoxic consequences. Journal of Reproductive Toxicology 2007; **23**(4):578-87.
 21. Akondi RB, Kumar P, Annapurna A, Pujari M. Protective Effect of Rutin and Naringin on Sperm Quality in Streptozotocin (STZ) Induced Type 1 Diabetic. Iranian Journal of Pharmaceutical Research 2010; **10**(3):585-596.
 22. Ghafari S, Balajadah BK. Effect of *Urtica dioica* on testicular tissue in STZ-induced diabetic rats. Pakistan Journal of Biological Science 2017; **14**:798-804.
 23. Akkoc H, Kelle I, Tunik S, Erdinc M, Erdinc L, Nergic Y. Effect of ethyle pyruvate on testicular damage in rats with streptozotocine-induced diabetes. Acta Endocrinologica, 2012; **8**:35-45.
 24. Chatterjee K, Ali KM, De D, Bera TK, Jana K, Maiti S, Ghosh A, Samanta R, Ghosh, D. Diabetes induced testicular dysfunction amelioration by ethyl acetate fraction of hydromethanolic extract of root of *Musa paradisiaca* L. in streptozotocin-induced diabetic rats. Asian Pacific Journal of Tropical Disease, 2012; **12**:233-241.
 25. Modeste WN, Florea A, Balici S, Pierre W, Honea M, Albert K. *Dracaena arborea* alleviates ultra-structural spermatogenic alterations in



- streptozotocin-induced diabetic rats. *Complementary and Alternative Medicine* 2013; **13**:1-9.
26. Canteros G. Nitric oxide synthase content of hypothalamic explants: Increase by norepinephrine and inactivated by NO and cGMP. *Proceedings of the National Academy of Sciences USA* 1996; **93**:4246-4250.
27. Ali ST, Rakkah NI. Neurophysiological role of sildenafil citrate (Viagra) on seminal parameters in diabetic males with and without neuropathy. *Pakistan Journal of Pharmaceutical Science* 2007; **20**(1):36-42.

Cite this Article as: Mohammed B. Mahre, Saidu I. Ngulde, Bukar Umaru, Fakilahyel M. Mshelbwala, Dauda Yahi, Abubakar Waziri, Aji T. Goni, Bitrus Wampana. Effects of Sildenafil Citrate On Testicular Histology and Sperm Count During Wound Healing Process in Diabetic Rats. *Bo Med J* 2018;**16**(1): **Source of Support:** Nil, **Conflict of Interest:** None declare

