

## PROLAPSED VAGINAL MULLERIAN CYST MASQUERADING AS UTERO-VAGINAL PROLAPSE: A CASE REPORT.

EHALAIYE B<sup>1</sup>, NDONYA-SALEH D<sup>1</sup>, YOHANNA J<sup>1</sup>, KWAGHE BV<sup>2</sup>

### ABSTRACT

A 20 year old para 2, presented at our gynaecological clinic with a 4 year history of “something protruding from her vagina”. She was referred to us with a diagnosis of utero-vaginal prolapse. Examination revealed a 6x6 cm, cystic, anterior vaginal wall mass, which was confirmed to be a vaginal cyst on ultrasound. Surgical excision of the cyst was done and histopathology confirmed it was of mullerian origin. Vaginal mullerian cysts are usually small and asymptomatic, but may rarely enlarge as reported in this case. They are therefore important in the differential diagnosis of utero-vaginal prolapse or cystocele.

**KEYWORDS :** Vaginal cyst, Mullerian cyst, Prolapse.

### INTRODUCTION

Cysts in the vaginal wall are relatively uncommon and are usually incidental findings in gynaecological practice<sup>1</sup>. Mullerian cysts are the commonest congenital vaginal cysts<sup>2,3</sup>. Mullerian cysts are embryological remnants of the Paramesonephric (mullerian) ducts. These paired ducts extend caudally to reach the urogenital sinus at about 9 weeks gestation. Their lower ends fuse in the midline and develop into the uterus and cervix, while the cephalic ends remain separate to form the fallopian tubes. Both the mullerian ducts and the urogenital sinus are believed to contribute to the formation of the vagina<sup>4</sup>. During replacement of the mullerian epithelium with squamous epithelium of the urogenital sinus, mullerian tissue can persist anywhere in the vaginal wall, from which cysts may arise. The most common location is along the antero-

lateral aspect of the vagina<sup>3,5</sup>. Mullerian cysts are usually less than 2cm in size and asymptomatic. They usually require no treatment but occasionally may be large enough that the symptoms require surgical excision<sup>1,3,5</sup>. We report a rare case of a large prolapsed vaginal mullerian cyst.

### CASE REPORT

A 20 year old para 2 (last child birth, 2 years earlier), presented at the gynaecological clinic of our hospital with a 4 - year history of “something protruding from her vagina”. It was first noticed a few months after her first delivery. It was initially small-sized, but gradually increased to its present size. It also became non-reducible, with associated pelvic pressure and coital difficulty, but no history of pain, vaginal discharge, bleeding or urinary symptoms. There was no antecedent history of vaginal trauma, repair of perineal lacerations or episiotomy. She had been referred to the clinic as a case of utero-vaginal prolapse.

Her general and systemic examination findings were unremarkable. Vaginal examination revealed a non-tender, non-reducible, 6 x 6 cm, cystic mass, arising from the anterior vaginal wall, which displaced the urethra laterally. The uterus was retroverted and normal-sized, no prolapse or stress incontinence. A provisional diagnosis of a cystocele to rule out bladder diverticulum or

<sup>1</sup>Department of Obstetrics and Gynaecology, Federal Medical Centre, Yola.

<sup>2</sup>Department of Histopathology, Federal Medical Centre, Yola.

### Correspondence to:

**EHALAIYE B,**

Department of Obstetrics and Gynaecology,  
Federal Medical Centre, Yola.

[eMail:- ehabolurin@gmail.com](mailto:ehabolurin@gmail.com)



vaginal cyst was made. Ultrasonography revealed a clear, cystic mass, obscuring the vaginal echo, with a well-defined border, separating it from the lower part of the posterior bladder wall. It measured 5.0 X 2.3 X 6.4 cm. Diagnosis was Paravaginal Cyst. She was scheduled for surgical excision of the cyst after satisfactory pre-operative work-up. A metal catheter passed into the bladder intra-operatively showed it was displaced laterally and not connected to the cyst. Incision was made on the anterior vaginal wall and the cyst sac separated from the vagina by blunt and sharp dissection (Figure 1). The cyst accidentally ruptured in the process with drainage of mucinous fluid. Excess vaginal tissue was excised and vaginal mucosa closed with absorbable sutures, haemostasis was secured. A vaginal pack was applied and urinary catheter drained clear urine. Adequate antibiotic cover was provided and the vaginal pack removed 8 hours post-operatively, with no bleeding or haematoma formation noticed. She remained stable and was discharged on the 4<sup>th</sup> day post-operatively.

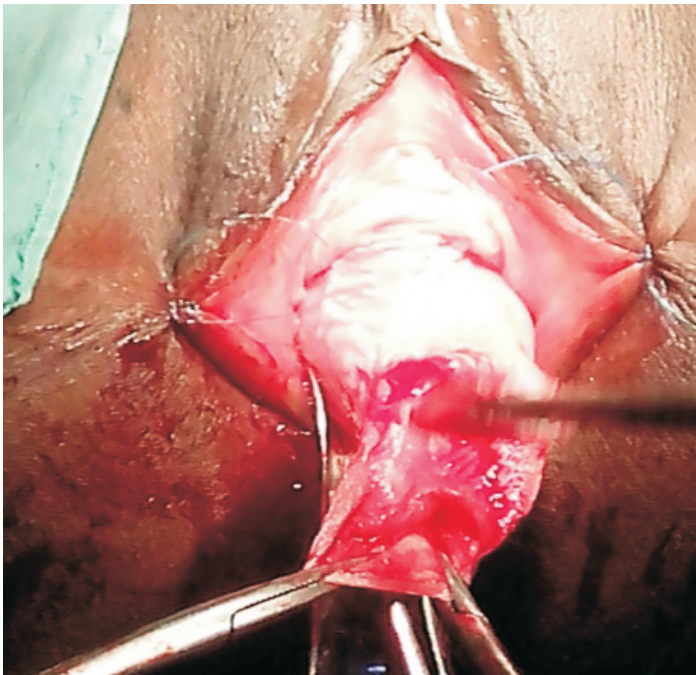


Figure 1: Mullerian Vaginal cyst

Histology showed cystic space lined by tall columnar cells with apical mucin. Epithelium was attenuated at some foci and seen within a fibro - collagenous stroma, with some foci showing blood vessels and muscle fiber, diagnosis was Mullerian Vaginal Cyst.

She was followed up in the clinic 2 weeks and 6 weeks later. She was stable with no complaints. Vaginal wound healing was satisfactory.

### DISCUSSION

Cystic lesions of the vagina are relatively uncommon, usually an incidental finding on gynaecological examination and are classified histologically, based on the lining epithelium. They include the Mullerian cyst, Gartner's duct cyst, Epidermal inclusion cyst, Bartholin's duct cyst, Dermoid cyst among others<sup>6</sup>.

Mullerian cysts are the commonest congenital cysts of the vagina. They occur predominantly in the reproductive age, typically less than 2cm in diameter and asymptomatic. Larger cysts tend to be symptomatic, presenting with voiding or defaecation problems, dyspareunia, visible or palpable mass, vaginal discharge and pain<sup>1,7,8</sup>. This patient presented with a vaginal mass which was initially mistaken for a utero-vaginal prolapse.

Mullerian cysts are commonly located in the antero-lateral vaginal wall<sup>3,5</sup> in relation to the bladder, where it may mimick a cystocele<sup>9</sup> as occurred with our patient. Rarely, they may extend posteriorly, presenting as an enterocele<sup>5,7</sup>. In this case, the location of the cyst ruled out Bartholin's cyst which is located in the postero-lateral vaginal wall, while lack of antecedent history of vaginal trauma or perineal surgeries precluded the likelihood of an inclusion cyst.

Ultrasonography revealed a clearly defined mass with no communication with the bladder, thereby ruling out a cystocele or bladder diverticulum. Pre-operative characterization

of the exact nature of a vaginal cyst may be difficult, but the clear cystic nature of the cyst, will exclude a dermoid cyst, characterized by echogenic material<sup>10</sup>.

Histopathology confirmed the diagnosis of mullerian cyst with tall columnar cells having apical mucin<sup>18</sup>. This is unlike gartner's duct cysts which are composed of non-mucin secreting low columnar or cuboidal epithelium, though differentiating between the two is of little clinical importance<sup>11</sup>.

Transvaginal surgical excision of the cyst was a satisfactory treatment modality as the patient remained stable on follow-up.

In conclusion, not all masses protruding from the vagina are cases of utero-vaginal prolapse, cystocele or enterocele. Vaginal cysts, though relatively uncommon, are important in the differential diagnosis. Mullerian cysts are the commonest congenital cysts of the vagina and are satisfactorily managed by surgical excision. ■

---

## REFERENCES

1. Sheela Jayaprakash, Lakshmidhevi M, Sampath kumar G. A rare case of posterior vaginal wall cyst. *BMJ Case Rep.* 2011; 2011:bcr022011.
2. Pradhan J, Tobon H. Vaginal cysts: a clinicopathological study of 41 cases. *Int J Gynecol* 1986; 5:35-46.
3. Emrah Toz, Muzaffer Sancı, Suheyla Cumurcu, et al. Mullerian cyst of the vagina masquerading as a cystocele. *Case Reports in Gynecology Volume 2015 (2015)*. Article ID 376834, 3 pages.
4. Edmonds DK. Normal and abnormal development of the genital tract. In: Edmonds DK (ed), *Dewhurst's Textbook of Obstetrics and Gynaecology for Postgraduates*. 6th edition. Blackwell Sciences, 1999; 1-11.
5. Kresowik J, Kennedy CM, Wing S, Galask RP. Prolapsing vaginal cyst: a case report. *J Reprod Med.* 2007; 52(9): 852-4.
6. Harun Toy, Fatma Yazici. Female genital tract cysts. *Eur J Gen Med* 2012; 9 (Suppl 1): 20-26.
7. Rashmi, Suneja A, Agarwal N, et al. Vaginal mullerian cyst presenting as enterocele. *J Obstet Gynecol India* 2009; 59(1): 74-76.
8. Valecha SM, Shah N, Gandhewar M, Shende P. Rare case of prolapsing vaginal cyst. *J South Asian Feder Obst Gynae* 2013; 5(1): 40-41.
9. Montella JM. Vaginal mullerian cyst. *Obstet Gynecol* 2005; 105(5): 1182-4.
10. Sharma R, Rao KA, Nagraj S. A rare case of vaginal dermoid cyst: A case report and review of literature. *Int J Infertility Fetal Med* 2012; 3(3): 102-104.
11. AV Arumugam, G Kumar, LK Si et al. Gartner duct cyst in pregnancy presenting as a prolapsing pelvic mass. *Biomed Imaging Interv J* 2007; 3(4): e46.

---

**Cite this article as:** Ehalaiye B, Ndonya-saleh D, Yohanna J, Kwaghe BV.

Prolapsed Vaginal Mullerian Cyst Masquerading as Utero-vaginal Prolapse: A Case Report. *Bo Med J* 2015; 12(1): 48 - 50. **Source of Support:** Nil, **Conflict of Interest:** None declared.

---

