

**SPONTANEOUS ENTEROCUTANEOUS FISTULA COMPLICATING ENCARCERATED FEMORAL HERNIA: A CASE REPORT****ALIYU S, IBRAHIM AG, LAWAN AM, ALI N, SALIM MU**

---

**SUMMARY**

---

Femoral hernias are uncommon of all external abdominal hernias; however they are the most commonly incarcerated external hernias, leading to significant morbidity and mortality. Rarely, such strangulation of viscus may result in spontaneous fistulation with its sequelae of fluids and electrolytes imbalance, anaemia, and malnutrition. We report a case of spontaneous enterocutaneous fistula resulting from neglected strangulated femoral hernia.

**KEYWORDS:** Femoral hernia, Strangulation, Spontaneous, Enterocutaneous Fistula.

---

**INTRODUCTION**

Femoral hernia is an uncommon external hernia with high possibility of strangulation due to the narrow neck of the hernia ring<sup>1</sup>. However, spontaneous enterocutaneous fistula arising from its strangulation is rare except in neglected cases<sup>2</sup>. Most of the cases of spontaneous fecal fistulae reported in the literature are from developing countries like Pakistan, India, Nigeria and Yemen<sup>3-6</sup>. Enterocutaneous fistula is associated with profound fluids and electrolytes derangements. Such patients are usually malnourished, dehydrated, anaemic, and may be septic with or without peritonitis<sup>7</sup>. The management require resuscitation by correction of fluids and electrolytes imbalance, blood transfusion, nutritional

support, antibiotics and definitive procedure of bowel resection, anastomosis and femoral herniorrhaphy.

**CASE SUMMARY**

The patient was a 60-year old woman from rural area in neighbouring Yobe state who presented with painless right groin swelling of 10 - years duration. The swelling was reducible but became irreducible in the last three weeks associated with pain, vomiting, constipation, and abdominal distension. Five days prior to presentation she noticed foul - smelling feculent discharge from the right groin swelling via multiple openings. There was no preceding trauma, and there was no history of incision of the swelling by traditional healer and patient was never taken to any hospital. She is not diabetic nor hypertensive. Other systems were essentially normal. She was found to be chronically ill - looking, wasted, pale, dehydrated, febrile and weak. Her pulse rate was 110/min and blood pressure was 80/60mmHg. The essential findings on abdominal examination were multiple openings discharging faces over an indurated femoral swelling (Fig 1).

---

College of Medical Sciences, University of Maiduguri Borno State Nigeria

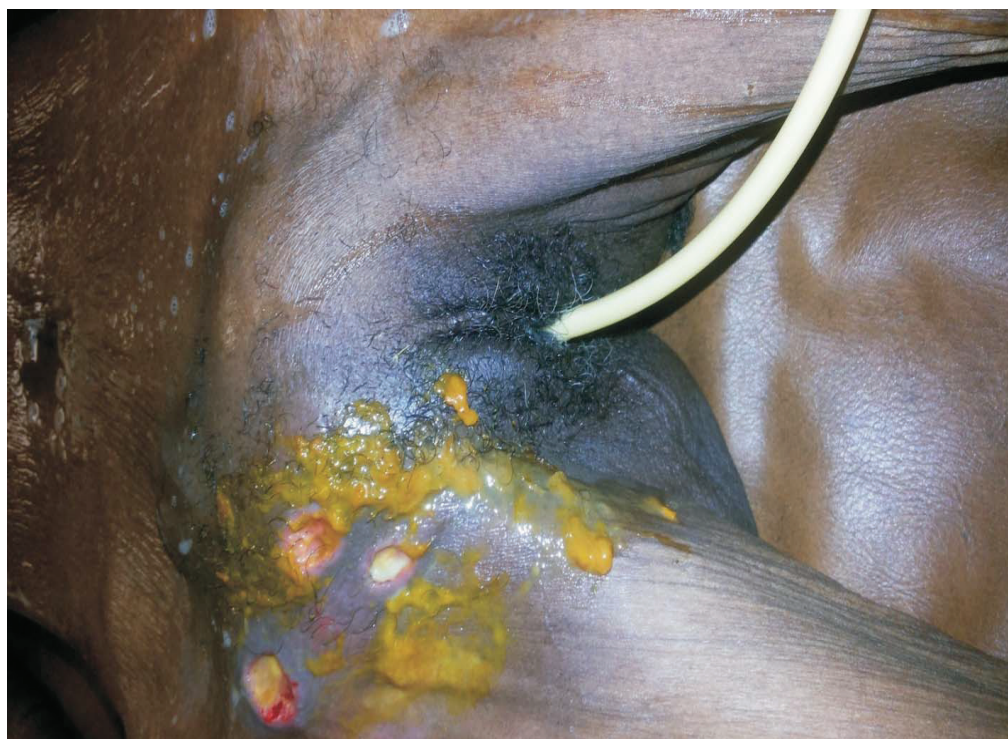**Correspondence to:****DR SULEIMAN ALIYU**

Department of Surgery University of Maiduguri Teaching Hospital P. M. B. 1414 Maiduguri Borno State Nigeria.

eMail:- [drsuleiman.aliyu@yahoo.com](mailto:drsuleiman.aliyu@yahoo.com)

A working diagnosis of spontaneous enterocutaneous fistula from strangulated femoral hernia was made. The investigations done were PCV 21%, Blood chemistry Na 120mmol/l, K 2.8mmol/l, Urea 7mmol/l, Cr 149mmol/l, total protein 51g/l, albumin 28g/l. Other investigations were within normal limits. Patient was resuscitated with intravenous fluids, electrolytes corrected, had 3 units of blood transfused, antibiotics (ceftriaxone and metronidazole), and nutritional

support were given. Intraoperative findings were incarcerated small bowel with multiple lateral fistulae involving hemi circumference with the largest having a diameter of 2.6cm (gangrenous portions have sloughed off- Fig.2). Patient had bowel resection, anastomosis with femoral herniorrhaphy under general anesthesia (Fig 2 and Fig 3). The post operative recovery was uneventful; she was discharged three weeks after surgery.



**Fig 1:** Multiple openings discharging feces over an indurated femoral swelling.

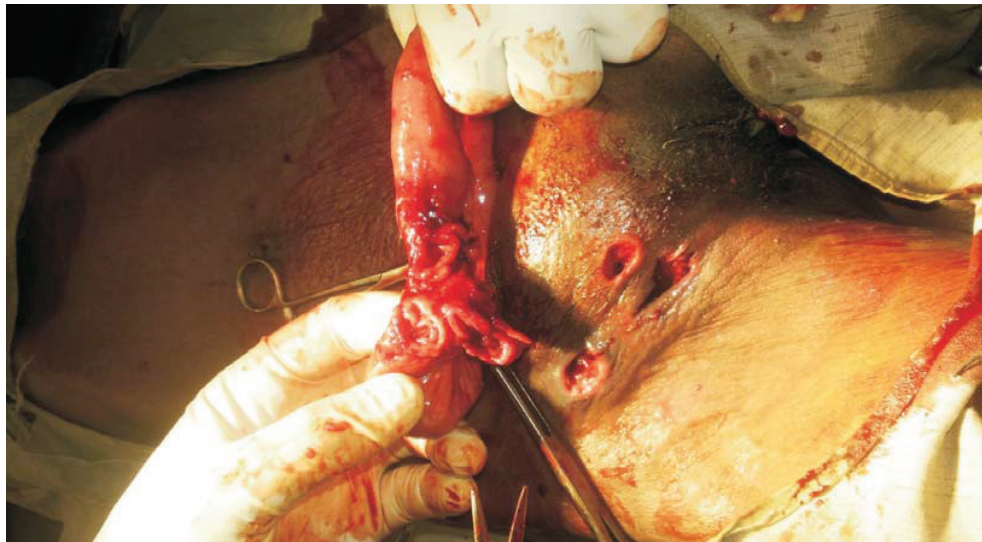


Fig 2: Multiple fistulae

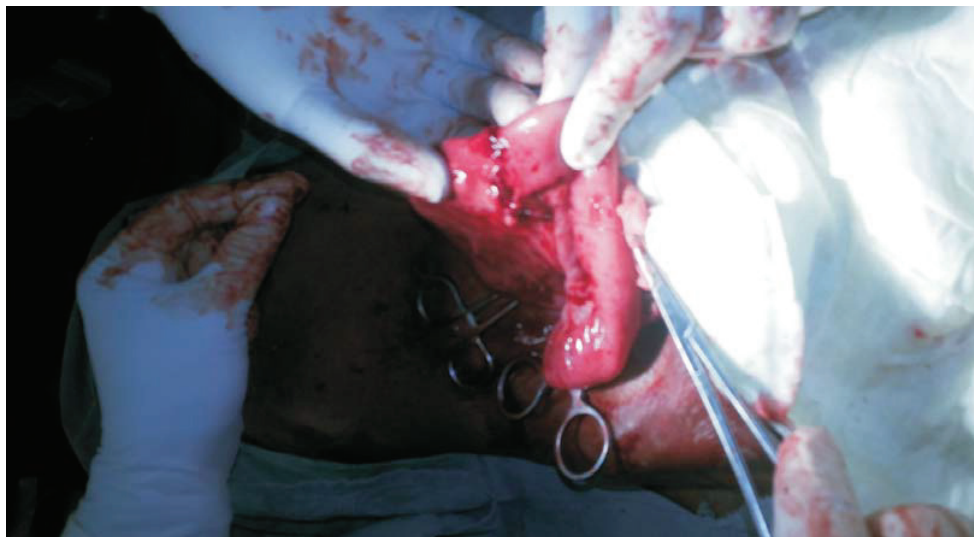


Fig 3: Resection and end to end anastomosis.

#### DISCUSSION

Spontaneous enterocutaneous fistula is a rare entity as more often strangulated hernias are surgical emergencies with short history. Strangulation and fistulation, a process that require time can occur only in neglected cases or where medical services are not readily accessible<sup>8</sup> as in the index patient. Enterocutaneous

fistula is associated with high morbidity and mortality. The triad of sepsis, malnutrition, and fluids / electrolytes disturbance is the greatest determinant of mortality<sup>8</sup>. In the index patient, such challenges were encountered. The initial management of these patients is aimed at correction of fluids and electrolyte disturbances, control of sepsis and

nutritional support to combat hyper catabolic state and prevent malnutrition. The management of the index patient relied on this principle. In favorable circumstances, 60 – 70 % of fistulae will healed spontaneously within 6 weeks of conservative management<sup>9</sup>. In the index patient surgery was undertaken after

initial management because there was no facility for total parenteral nutrition. Nutritional rehabilitation was intensified and recovery was remarkable. All hernias should be promptly evaluated and repaired to prevent incarceration and its sequellae. ■■■

---

#### REFERENCES

1. David T: Strangulated femoral hernia. *Med J* 1967;1: 258.
2. Ihedioha U, Alani A, Modak P, Chong P, O'Dwyer P J ; Hernia are the most common cause of strangulation in patients presenting with small bowel obstruction. *Hernia* 2006;10: 338 – 340.
3. Samad A, Sheikh GM. Spontaneous fecal fistula: a rare presentation of inguinal hernia. *J Ayub Med. Coll Abbottabad*. 2005;17: 77 – 9
4. Kasat LS, Waingankar VS, Kamat T, AnilKumar, Bahety G, Meisheri IV. Spontaneous scrotal faecal fistula in an infant. *Pediatr Surg Int*. 2000; 16: 443 – 444
5. Chirdan LB, Uba AF, Iya D, Dakum NK. Spontaneous scrotal faecal fistula in a neonate: report of a case. *Nigerian Journal of surgical Research*. 2006;6:59 – 60
6. Binbisher SA, Aram FO. Enterocutaneous fecal fistula as a complication of Strangulated Inguinal Hernia: a case Report. *Journal of the Bahrain Medical Society (JBMS)* 2008;20:178 - 9
7. Deepa Taggarshe, Daniel Bakston, Mickael Jacobs, Alascdair Mckendrick, Vijoy K Mittal. Management of enterocutaneous fistulae: A 10 year experience. *World J Gastrointest Surg* 2010 2: 242 – 256.
8. Joyce M, Dietz D. Management of complex gastrointestinal fistula. *Curr Prob Surg*. 2009;246:5:379.
9. Datta V, Windo A. C. Surgical Management of enterocutaneous fistula. *Br J Hosp Med (Lond)* 2007; 68:28 – 31.

---

**Cite this article as:** Aliyu S, Ibrahim AG, Lawan AM, Ali N, Salim MU. Spontaneous Enterocutaneous Fistula Complicating Encarcerated Femoral Hernia: A Case Report. *Bo Med J* 2014; 11(1): 72 - 75.

---