

CHEST RADIOGRAPHIC FINDINGS IN SPUTUM SMEAR POSITIVE PULMONARY TUBERCULOSIS AS SEEN IN USMANU DANFODIYO UNIVERSITY TEACHING HOSPITAL SOKOTO, NIGERIA.

¹Saidu SA, ²Makusidi AM, ²Njoku CH

ABSTRACT

Background: Pulmonary tuberculosis has become a major public health concern particularly with the global HIV/AIDS epidemic. Recent report has shown that the disease affects mainly young adults in their most productive age with attendant socio-economic impact on the nation. Although sputum bacteriology is the gold standard for the diagnosis of PTB, chest radiography is a valuable tool for its investigation and management. **Objective:** To determine pattern of chest radiographic findings in sputum positive pulmonary tuberculosis. **Method:** A two-year prospective study was undertaken between January, 2010 and December, 2011 among treatment naïve sputum smear positive PTB patients who had chest radiograph at diagnosis. The socio-demographic and clinical features were recorded. The chest radiographs were reported by radiologist and the data was analysed using SPSS version 11. **Results:** One hundred and six consecutive PTB patients who had chest radiograph were studied. Their age range was 20 – 75 years with mean (\pm SD) of 37.1 (\pm 10.3) years. There were 78 males (73.6%) with male to female ratio of 1.4:1. Significant proportions (54%) were of low socio-economic status and 52% were HIV positive. The commonest presenting radiological features were patchy/streaky opacities and cavitary lesions. Eight had pleural effusion while lung collapse was found in 4 patients. Bilateral involvement of the lung fields was commoner (68.3%) and upper lobe disease was the commonest finding. **Conclusion:** Patchy/streaky opacities and cavitary lesions were the commonest radiographic features in our study. Bilateral and upper lobe affectations were predominant. Chest radiograph remains a useful tool in the diagnosis and subsequent management of PTB.

Key words: *Chest radiograph, Sputum, PTB.*

INTRODUCTION

Tuberculosis (TB) has become a major health concern especially with the global HIV/AIDS epidemic. More than 9 million people are diagnosed with active tuberculosis each year, and 1.6 million die of the disease¹. Recent projections indicate that the incidence of tuberculosis can be expected to increase to 10.2 million annually with 3.5 million deaths¹.

The tuberculosis burden has been found to be largest in sub-Saharan Africa and South East Asia^{2,3}. Seventy-five percent of TB cases

in these countries are in the economically productive age groups. Majority of adult tuberculosis patients with or without HIV co-infection develop pulmonary disease³. Although sputum bacteriological study is the gold standard for the diagnosis of pulmonary tuberculosis⁴ it hardly gives insight into the severity and extent of the disease. The combination of clinical assessment and radiological finding which give insight into disease severity will significantly influence the course of management and follow up. There are few studies on the radiological pattern of pulmonary tuberculosis among Nigerians⁵⁻⁷ and none has been carried out in the Sahelian Belt of North Western Nigeria to the best of our knowledge. It is therefore expected that this work would serve as pioneer study in this region while forming a basis for comparison with other documented studies.

MATERIALS & METHODS

Usmanu Danfodiyo University Teaching Hospital, (UDUTH) Sokoto serves as the

¹Department of Radiology ²Department of Medicine, Usmanu Danfodiyo University Teaching Hospital, Sokoto

Correspondence to:

DR MAKUSIDI AM

Department of Medicine

Usmanu Danfodiyo University Teaching Hospital, PMB 2370, Sokoto

Tel: +2348036057382

Email Address: makusidi1@yahoo.com

tertiary referral centre for Sokoto, Kebbi, Zamfara, Niger and Katsina States of Nigeria. A two year prospective study was undertaken between January 2010 and December 2011, among treatment naive sputum smear positive PTB patients, who had chest radiographs at the time of diagnosis.

Patients that presented to the medical outpatient department and/or admitted to the medical ward during the above mentioned period were enrolled for the study if they had cough, with expectoration for at least 2 weeks with or without haemoptysis, chest pain, fever and weight loss and were subsequently bacteriologically confirmed to have PTB.

The consent of the patients were obtained and their socio-demographic data, presenting symptoms and clinical examination findings were documented at presentation.

Ethical clearance was obtained from the Hospital Ethical Committee.

RESULTS

One hundred and six consecutive positive smear PTB patients who had their chest radiographs done at our centre were studied. The age range of the patients was 20-75 years with a mean of 37.1 ± 10.3 . There were 78 males (73.6%) and 28 females. Significant proportions (54%) of the patients were of low socioeconomic status. Fifty five of the cases (52%) were HIV positive. Three of the HIV negative patients had diabetes mellitus.

All the patients with positive history of contact with individuals with chronic cough in our study were found to be HIV negative. Other clinical features found are haemoptysis and diarrhoea.

The commonest radiographic finding was patchy /streaky opacities in 58 patients, followed by cavitory lesion in 46 patients while reticulonodular opacities and pneumonic consolidation were found in 19 patients each (Figure 1). The distribution of the radiological findings was such that bilateral affection of the lung fields was commonest with 68.3%,

followed by unilateral right sided involvement in 17.8%. About seventy eight percent of the patients who had lesion showed upper lobe affection, while 8(72.7%) of the 11 patients that had pleural effusion showed the effusion as the only radiological feature. Five of our patients had normal radiographs. There were 4 cases of lung collapse of which 3 (75%) were on the right and one on the left. There was also one case of destroyed lung syndrome on the left side.

DISCUSSION

Majority of PTB patients in our study were young adults in their most productive age. This agrees with the finding from Ilorin, Nigeria⁸ and supports the global epidemiological pattern described for developing countries; where more of the infected people are below 50 years of age. This contrasts with what obtains in the developed countries where there is higher prevalence of the disease among those aged 50 years and above. The contributory factors responsible for the disparity include improvements in TB control and treatment programmes.

Majority of our patients were males (73.6%) which are similar to the finding in previous reports^{9,10}. However, Erinle⁵ in his study in Ilorin, Nigeria reported a female preponderance presumably because his study population consisted of both adults and children. Fifty two percent of our patients were HIV positive. This may not be unconnected with the association of the resurgence of tuberculosis with the HIV pandemic in sub-Saharan Africa^{3, 11, 12}. This unholy alliance between HIV and tuberculosis is as a result of suppression of the patients' immunity leading to the increase in the incidence of reactivation of latent tuberculosis and progression of recent infection. Another cause of immunosuppression is diabetes mellitus, which we found as co-morbidity in three of our HIV negative patients.

The commonest presenting symptoms were fever and productive cough followed closely

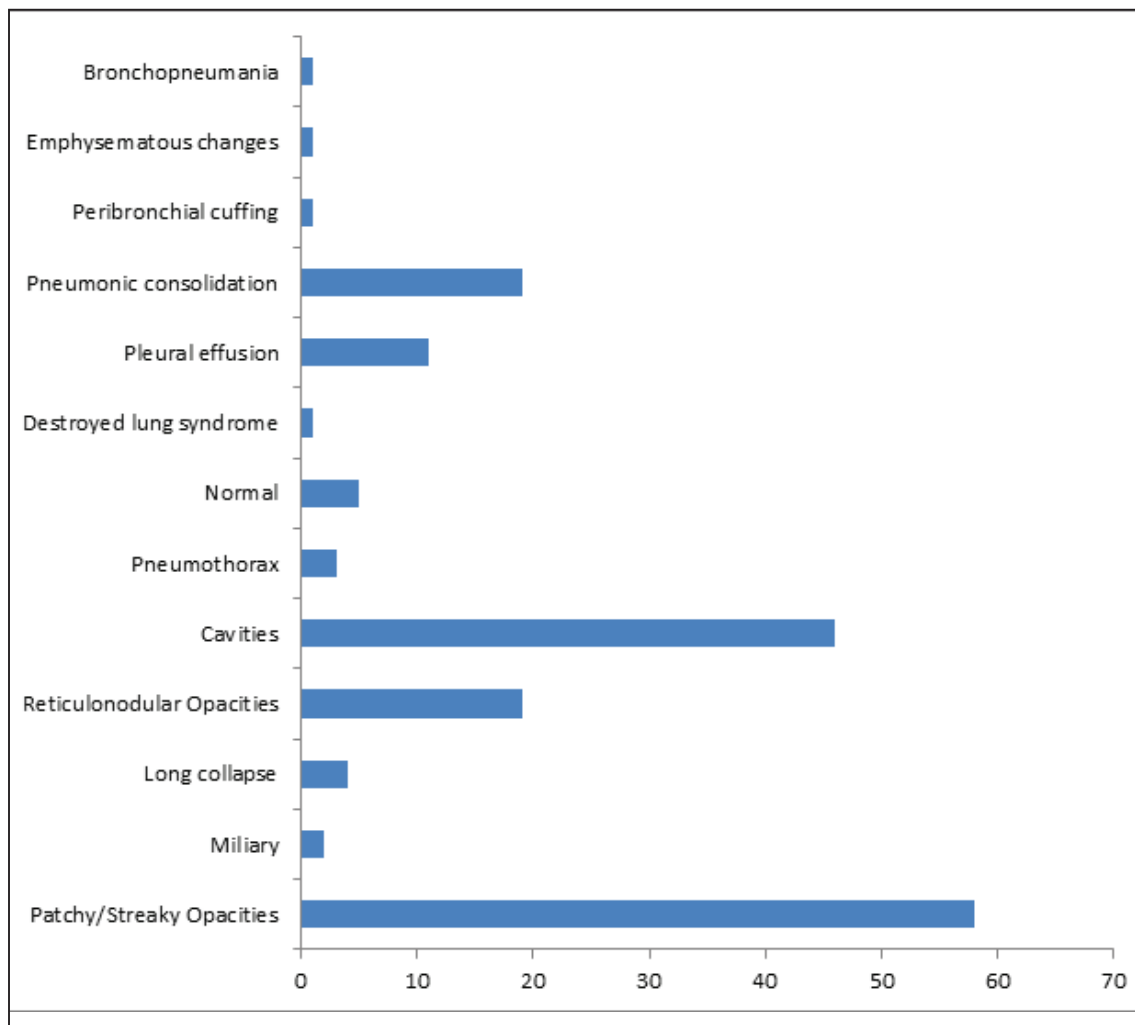


Figure 1. Patterns of radiographic findings in PTB

by chest pain and weight loss. All patients with positive history of contact with chronically coughing individuals were found to be HIV negative. This may not be surprising as HIV positive individuals are more likely to have reactivation of latent TB infection than re-infection from exposure to a tuberculosis patient¹³⁻¹⁵.

The chest radiograph is the mainstay in the radiologic evaluation of suspected or proven pulmonary TB¹⁵. WHO recommends that the diagnosis of pulmonary tuberculosis be based on any of the following: ‘‘One sputum smear positive for acid fast bacilli (AFB) and radiographic abnormalities consistent

with active PTB’’ for sputum positive PTB and ‘‘symptoms suggestive of PTB and three negative smears for AFB and radiographic abnormalities consistent with active PTB’’ for negative smear PTB^{1,4}.

The predominant radiological feature in our study was patchy /streaky opacities, followed by cavitory lesions. This is in accord with previous studies^{5,14}. The only case of destroyed lung syndrome was on the left which was noted by other studies to be more commonly affected by the lesion⁵.

The radiological features in our study showed that most of the patients had bilateral lung

involvement. This is similar to the finding by Erinle⁵. Unilateral affectation of either the right or left lung field was found in 17.0% and 13.2% respectively. Five of the study group had normal chest radiographs. This infers that a normal radiograph does not totally exclude active tuberculosis. It has however, been argued that this may be seen in cases associated with endobronchial lesions which may not be apparent at the time of the examination or early apical lesions that can be missed¹⁴. In such unclear cases, CT scan is often helpful¹⁵. Chijioke et al¹⁵ reported the usefulness of CT scan in demonstrating pulmonary miliary shadows in a patient with miliary PTB in

which the chest X ray was essentially normal

The commonest lobar involvement is that of the upper lobe (78.2%). This agrees with findings in other studies^{7,9}. Dosumu⁷ in his study drew attention to the preponderance of the upper lobe lesions in PTB.

In conclusion, we found patchy/streaky opacities and cavitatory lesions predominantly affecting the upper lobes as the commonest radiographic features in PTB. Chest radiograph remains a useful tool in the diagnosis and subsequent management of PTB.

REFERENCES

1. WHO (2010) Global Tuberculosis Control 2010. WHO. Geneva; WHO/HTM/TB/2010.7.
2. Raviglione MC, Sunder DE (Jnr), Kochi A. Global epidemiology of tuberculosis. Morbidity and mortality of a worldwide epidemic JAMA 1995 :273 :220 -226
3. Harries AD, Maher D. Diagnosis and treatment of pulmonary tuberculosis in adults. Tuberculosis series in Postgrad Doctor Africa, 1995; 17 (4): 264 – 269
4. Harries AD, Maher D. TB/HIV. A clinical manual WHO/TB/96/2000, Geneva: World Health organization, 1996.
5. Erinle SA. An appraisal of the Radiological Features of Pulmonary Tuberculosis in Ilorin. The Nig Postgrad Med J, 2003; 10 (4): 264-269.
6. Ahidjo A, Yusuph H, Tahir A. Radiographic features of pulmonary tuberculosis among HIV patients in Maiduguri, Nigeria. Ann Afr Med. 2005; 47: 6-8.
7. Dosumu EA. Chest radiographic findings in newly diagnosed pulmonary tuberculosis cases in Iwo, Nigeria. Nig Med Pract. 2005; 47: 6-7.
8. Salami AK, Oluboyo PO. Hospital prevalence of pulmonary tuberculosis and co-infection with human immunodeficiency virus in Ilorin: A review of nine years (1991-1999), WAJM 2002; 21 (1): 24-27.
9. McCray E, Weinbaum CM, Braden CR, Onorato IM. The epidemiology of tuberculosis in the United States. Clin Chest Med. 1997; 18 (1): 99-113.
10. Geng E, Kreiswirth B, Burzinsky J, Schluger NW. Clinical and Radiographic correlates of Primary and Reactivation Tuberculosis. JAMA.2005;293(22):2741-2745
11. Decock KM, Soro B, Caulibaly IM, Lucas SB. Tuberculosis and HIV in sub Saharan Africa. JAMA. 1992; 268:1581-1587.
12. Idigbo EO, Alabi S. Prevalence of HIV antibodies in Tuberculosis patients in Lagos, Nigerian J Trop. Med. And Hyg. 1994; 97: 91-97.
13. McAdams HP, Erasmus J, Winter JA. Radiologic manifestations of pulmonary tuberculosis. Radiol Clin North Am. 1995; 33: 655-678.
14. Kolawole TM, Onadeko EO, Sofowora

EO, Esan GF. Radiological patterns of tuberculosis masquerading as pyrexia of pulmonary tuberculosis in Nigeria. Trop. obscure origin. *Sahel Medical Journal*.2000; Geogr. Med. 1975;27:339-350. 13:50-52.

15. Chijioke A, Aderibigbe A, Kolo PM, Olanrewaju TO, Makusidi AM et al. Miliary

Cite this article as: Saidu SA, Makusidi AM, Njoku CH. Chest Radiographic findings in sputum smear positive Pulmonary Tuberculosis as seen in Usmanu Danfodiyo University Teaching Hospital Sokoto, Nigeria. *Bo Med J* 2013;10(1):20-24