

# Giant Solitary Plasmacytoma of the Skull: Management of a Rare Differential Diagnosis

Usman B<sup>1</sup>, Mohammed B<sup>1</sup>, Daibu U<sup>1</sup> Bukar A A<sup>2</sup>, Zarami A B<sup>3</sup>

## ABSTRACT

**Background:** Solitary plasmacytoma of the skull (SPS) is a condition arising from the pathological proliferation of plasma cells. It is a rare condition, especially giant ones and may often mimic many conditions. Total excision may be curative. However, in some cases, chemotherapy or radiotherapy or chemoradiation may be necessary post-excision. **Case summary:** S.S. was a 44-year-old male with a rapidly growing swelling in the middle of his forehead for eight months. Physical examination revealed an otherwise healthy-looking young man, an obvious forehead mass covered with normal intact skin, sessile with a base circumference of 31cm, non-tender, mixed consistency (hard with cystic areas), fixed to the frontal bone but skin over it was freely mobile. No pulsation and no bruit. A clinical diagnosis of osseous meningioma was made. Fine Needle Aspirate Cytology (FNAC) revealed features consistent with a plasmacytoma. Urinary Bence Jones protein and bone marrow biopsy were negative for Myeloma. Surgical excision was via a craniectomy and a cranioplasty was done. Clinical condition one year after surgery remained satisfactory with no evidence of recurrence or development of myeloma. No chemotherapy or radiotherapy was administered. **Conclusion:** Giant solitary plasmacytoma of the scalp is a very rare condition and may clinically be misdiagnosed. May be managed with a total wide excision with or without chemotherapy or radiotherapy.

**Keywords:** Giant, plasmacytoma, skull, solitary.

<sup>1</sup>Neurosurgery unit, surgery department, the University of Maiduguri and the University of Maiduguri Teaching Hospital. <sup>2</sup>Haematology department, the University of Maiduguri and the University of Maiduguri Teaching Hospital. <sup>3</sup>Histopathology department, the University of Maiduguri and the University of Maiduguri Teaching Hospital.

## Corresponding Author:

Dr Usman Babagana.

Neurosurgery unit, surgery department, the University of Maiduguri and the University of Maiduguri Teaching Hospital.

**Email:** babaganau@yahoo.com.

**Phone:** +2348035951137

## Introduction

The pathological proliferation of the plasma cells produces a variety of disorders from benign solitary plasmacytoma to malignant myeloma<sup>1</sup>. Plasma cell tumours include solitary plasmacytoma, multiple plasmacytoma and multiple myeloma<sup>2</sup>.

A solitary bone plasmacytoma is described as a single lesion consisting of malignant proliferation of monoclonal plasma cells, found in less than 5% of patients with plasma cell myeloma tumours<sup>3</sup>. The most common location of solitary plasmacytoma (SP) is the axial skeleton, rarely found on the skull and more rare is a giant skull lesion<sup>4</sup>.

A diagnosis of SP is made when all the following criteria are satisfied: A histologically confirmed single lesion with negative skeletal imaging apart from the primary site, normal bone marrow biopsy (less than 10% monoclonal plasma cells), and no myeloma-related organ dysfunction<sup>5</sup>. Myeloma-related organ dysfunction includes the absence of increased serum Calcium, Renal insufficiency, Anaemia, or multiple Bone lesions (CRAB) that helps

## Access this article online

QuickResponse Code



website: [www.bornomedicaljournal.com](http://www.bornomedicaljournal.com)

DOI: [10.31173/bomj.bomj\\_2217\\_19](https://doi.org/10.31173/bomj.bomj_2217_19)



in differentiating it from myeloma as reported by Sevil *et al.*<sup>6</sup>

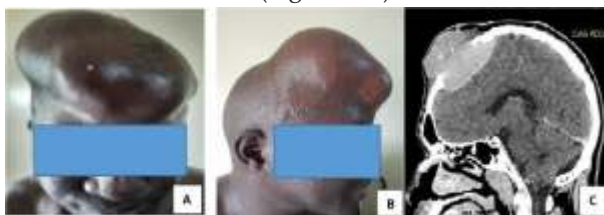This case highlights plasmacytoma of the scalp (a giant solitary Plasmacytoma of the Scalp) as an important differential diagnosis of a huge mass on the head, treated with total excision and cranioplasty.

### Case presentation

A 44-year-old male was referred to our facility with painless, rapidly growing swelling on the middle of his forehead. No bleeding, no features of raised intracranial pressure and no neurological deficit.

He was conscious and oriented with stable vital signs. Head and neck examination findings revealed a huge swelling on the frontal aspect of the vertex, sessile with a base circumference of 31 cm, horizontally about 35 cm wide, anteroposteriorly about 20 cm wide, and 9 cm at its highest point, covered by normal skin (Figure 1 A and B). Not warm to touch, non-tender, hard in consistency with some cystic areas, non-pulsatile, no bruit and no neck lymphadenopathy. The skin over the mass was freely mobile. However, the mass was fixed to the skull. Other systemic examinations were normal.

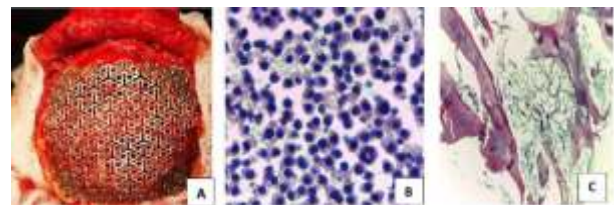
His Full Blood Count, Electrolytes, Urea, creatinine, fasting blood sugar and clotting profile were normal. A presumptive clinical diagnosis of meningioma was made. Fine Needle Aspiration Cytology (FNAC) of the swelling revealed a cellular smear of mononuclear cells with round to oval eccentrically placed nuclei and moderate to abundant cytoplasm. Sheets of plasmacytoid cells mixed with lymphocytes and occasional histiocytes were noted. These findings are suggestive of plasmacytoma. Furthermore, the skeletal survey, bone marrow biopsy, serum lactate dehydrogenase, calcium, albumin, and renal function test were within normal limits. Bence Jones protein in the 24-hour urine sample was negative. Head computed Tomography (CT) revealed scalp swelling, and erosion of the skull with an intracranial but extradural extension, exhibiting multiple calcifications and uniform contrast enhancement (Figure 1 C).



**Figure 1:** pictures (A) and (B) are the anterior and

lateral views of the patient respectively. While (C) is a sagittal reconstruction of the patient's Computed Tomography of the head showing the contrast-enhancing extra-axial lesion, no dura breach, with multiple calcifications.

The patient was counselled for surgery and underwent craniectomy after a bicoronal incision with an en-bloc total excision of the tumour with about two cm margin, and subsequent cranioplasty with a titanium plate (Figure 2 A). The tumour was histopathologically confirmed to be a plasmacytoma (Figure 2 B). Patient was neither treated with radiotherapy nor chemotherapy. Bone marrow biopsy done one month post-op (Figure 2 C) and did not show evidence of systemic myelomatosis.



**Figure 2:** Intraoperative picture showing the post-craniectomy cranioplasty with titanium plate (A), Tumour histopathology- photomicrograph ( $\times 200$  H and E) showing atypical plasma cells with perinuclear halo and eccentric nuclei (B), Bone marrow biopsy photomicrograph showing no evidence of marrow involvement(C).

He was followed up closely for one year, watching out for local recurrence and transformation or progression to multiple myeloma, but none occurred.

### Discussion

Our patient was a young man, of the black race, with a solitary plasmacytoma at the frontoparietal region of his skull vertex. The affection to his age group and race by SP as compared to multiple myeloma was as reported by Sevil *et al.*<sup>6</sup>

His presentation with a huge scalp swelling that eroded the underlying skull, with an extradural-intracranial extension on the CT scan made us consider meningioma as the initial diagnosis until the findings of the FNAC. This type of clinical presentation with plasmacytoma mimicking meningioma is not uncommon.<sup>7</sup>

The involvement of the skull by plasmacytoma has been well documented. Schwartz reported that the



commonly involved parts of the skull are the vault, base, dura and orbit in this order.<sup>8</sup>

His computed tomography findings were highly suggestive of plasmacytoma than a meningioma, similar to the finding of Adam *et al*<sup>7</sup>.

He had gross total resection with surrounding craniectomy followed by cranioplasty with titanium. This is assumed to be curative in our setting. This is said to be a successful treatment option as concurred by Arienta *et al*<sup>9</sup> and Grammatico *et al*.<sup>10</sup> It is unclear whether additional treatment with radiotherapy is necessary for resected extramedullary plasmacytoma with clear surgical margins.<sup>10</sup> Arienta *et al*<sup>9</sup> reported that if total resection has been achieved, then radiotherapy should be reserved for the cases of tumour recurrence.

His follow-up of one year was rather shorter than the over 10 years of Hu and Yahalom<sup>11</sup>, who found the rate of progression to multiple myeloma of 65-84% at 10 years and 65-100% by 15 years respectively.

### Conclusion

Clinical diagnosis of solitary plasmacytoma especially that of the scalp requires a high index of suspicion. Clinicians, therefore, need to develop this clinical acumen because early intervention with total excision with free margins may ensure a cure. However, postoperative follow-up is necessary in all cases to identify recurrence or progression which may require radiation/chemotherapy or chemoradiation

**Consent:** Approval from our hospital's ethics committee and informed consent from the patient was obtained.

**Contribution:** All the authors participated in managing the patient and writing the manuscript

**Funding:** None

**Conflict of interest:** None

### References:

1. Dong L, Zhang X, Zhang H, Song R, Gu X, He L. Solitary plasmacytoma of the skull: Two case reports. *Oncology Letters*. 2012 Nov 26;5(2):479-82. doi:10.3892/ol.2012.1046
2. Gürbüz MS, Akmil MU, Akar E, Aker FV. Solitary plasmacytoma of the skull. *BMJ Case Rep*. 2013;2013: bcr2013200379. Published 2013 Aug 8. doi:10.1136/bcr-2013-200379
3. Kuo YH, Huang WC, Wu JC. Surgical Treatment for a Giant Solitary Plasmacytoma with Skull Erosion. *Cureus*. 2018;10(11):e3535. Published 2018 Nov 1. doi: 10.7759/cureus.3535
4. Dores GM, Landgren O, McGlynn KA, Curtis RE, Linet MS, Devesa SS. Plasmacytoma of bone, extramedullary plasmacytoma, and multiple myeloma: incidence and survival in the United States, 1992-2004. *British Journal of Haematology*. 2009 Jan;144(1):86-94. DOI: 10.1111/j.1365-2141.2008.07421.x
5. Durie BG, Kyle RA, Belch A, Bensinger W, Blade J, Boccadoro M *et al*. Myeloma management guidelines: a consensus report from the Scientific Advisors of the International Myeloma Foundation. *Hematol J* 2003;4:379-98.
6. Kilciksiz S, Karakoyun-Celik O, Agaoglu FY, Haydaroglu A. A review for solitary plasmacytoma of bone and extramedullary plasmacytoma. *Scientific World Journal*. 2012;2012:895765. doi:10.1100/2012/895765
7. Adam C, Wilberger, Richard A. Prayson; Intracranial Involvement by Plasma Cell Neoplasms, *American Journal of Clinical Pathology* 146 (2016): 156-162.
8. Schwartz TH, Rhiew R, Isaacson SR, Orazi A, Bruce JN. Association between intracranial plasmacytoma and multiple myeloma: clinicopathological outcome study. *Neurosurgery*. 2001;49(5):1039-1045. doi:10.1097/00006123-200111000-00002
9. Arienta C, Caroli M, Ceretti L, Villani R: Solitary plasmacytoma of the calvarium: two cases treated by operation alone. *Neurosurgery*. 1987, 21:560-563. DOI:10.1227/00006123-198710000-00022
10. Grammatico S, Scalzulli E, Petrucci MT. Solitary Plasmacytoma. *Mediterr J Hematol Infect Dis*. 2017;9(1):e2017052. doi:10.4084/MJHID.2017.052
11. Hu K, Yahalom J. Radiotherapy in the management of plasma cell tumors. *Oncology (Williston Park)*. 2000;14(1):101-115.

---

**Cite this Article as:** Usman B, Mohammed B, Daibu U, Bukar AA, Zarami AB. Giant Solitary Plasmacytoma of the Skull: Management of a Rare Differential Diagnosis. *Bo Med J* 2022;19(2):136-138 **Source of Support:** Nil, **Conflict of Interest:** None declared

---

