

Gestational Gigantomastia: Report of a Rare Case and Literature Review

Abdullahi YM,¹ Zarami AB,¹ Lawan AI,¹ Guduf MI,² Farouk HU,³ Pindiga UH¹

ABSTRACT

Background: Gestational gigantomastia is a rare disorder with unknown aetiology. It commonly occurs during the first and early second trimesters and mostly affects women during their second and third decades of life. The disease has been reported to be more common among Caucasians than Blacks and involves both breasts in 92% of cases. There are no standard treatment protocols for the disease, however, both medical use of bromocriptine and simple mastectomy have been applied. **Case summary:** We present a case of 32-year-old un-booked female, G8P7+0, 7 alive, who presented with bilateral breast enlargement with ulceration at 25 weeks' gestation. The diagnosis was confirmed by tissue biopsy and simple mastectomy was done and the pregnancy was allowed to continue to term. **Conclusion:** This case report describes the first case of gestational gigantomastia in our environment and the seventh case reported in Africa to increase our awareness on how to diagnose and rule out other causes of bilateral massively enlarged breasts during pregnancy and the treatment options for this distressing clinical condition.

Keywords: Breast, Bilateral, Gestational gigantomastia

¹Department of Histopathology, Gombe State University/University of Maiduguri, Department of Human Pathology.

²Department of Surgery, Federal Teaching Hospital Gombe.

³Department of Obstetrics and Gynaecology, Federal Teaching Hospital Gombe.

Corresponding Author:

Zarami Abba Bukar
Department of Human Pathology
Faculty of Basic Clinical Sciences
University of Maiduguri
abbabukarzarami51@yahoo.com +2347035969496

Introduction

Gigantomastia in pregnancy is a rare non-neoplastic medical condition¹ associated with rapid diffuse and excessive breast hypertrophy.² The disease was first described by Palmuth in 1648 and since then only a few cases were reported in the English literature.³ In a meta-analysis of gestational gigantomastia (GG) over 40 years only fifty cases were reported in human subjects.⁴ The incidence of the disease was reported as 1 in 28,000 to 1 in 100,000 pregnancies. The natural history of GG, as well as its risk factors, are not fully understood,⁴ however, the disease is more common among Caucasian than African women with most patients affected within the third decades of life.⁵ To date there is no standard treatment for the disease although, both medical and surgical treatments were proposed by many researchers. Very few cases of postpartum complete spontaneous resolution have been reported.^{1,2,3,4}

This is the first case of gigantomastia in pregnancy in our collective experiences therefore we present this case because of its rarity and its tendency to subterfuge other causes of bilateral massive breast enlargement during pregnancy.

Case Presentation

A 32-year-old un-booked woman G8P7+0, 7 alive, presented at 25 weeks' gestation referred from State Specialist Hospital Gombe to Federal Teaching

Access this article online

Quick Response Code



website: www.bornomedicaljournal.com

DOI: 10.31173/bomj.bomj_2119_18



Hospital Gombe on account of marked bilateral breast swelling; the breast enlargement started at 16 weeks' gestation and increased rapidly as the pregnancy progressed and subsequently complicated by skin atrophy over the breast, ulcerations, necrosis and pain. The patient also complained of mastalgia, severe back pain with difficulties in breathing and movement. This was the first time she had experienced excessive breast enlargement (figure 1). Examination revealed a conscious lady, not pale, anicteric, acyanosed with moderate bilaterally pitting pedal oedema up to the ankle joint and multiple axillary lymphadenopathies. The two breasts were markedly enlarged with hyper-pigmented skin overlying both breasts, the ulcers on both breasts show necrotic floors and indurated base measuring 20x8cm and 18x5cm in diameter on the left and right breast respectively. The ulcer edges are everted. The left breast measured 30x22x10cm while the right measured 25x18x8cm. She has normal vital signs. Abdominal examination shows symphysio-fundal height of 28cm, singleton baby, longitudinal lie and cephalic presentation. Clinical diagnosis of bilateral gravid breast enlargement to rule out bilateral breast cancer was made.

The baseline haematological and biochemical parameters are within normal limit. Fine needle aspiration cytology (FNAC) was reported as benign lesion (C2). Incisional tissue biopsy was reported as suggestive of bilateral gestational breast hypertrophy. The patient had bilateral mastectomy under general anesthesia (figure 2). The pregnancy was allowed to continue to term under close monitoring.

Grossly, the right and left mastectomy specimens measured 24x16x8cm and 30x22x10cm and weighed 1.9kg and 2kg respectively (figure 3). Their cut surfaces appeared solid greyish white and rubbery in consistency.

Microscopically, the sections from both breast masses show similar features. The sections show breast tissue composed of hyperplastic ducts lined

by double-layered epithelium and are arranged in lobular pattern in a hyperplastic fibromyxoid stroma with extensive oedema. There is marked adenosis and stromal hypertrophy. The features are consistent with gestational breast hypertrophy (figure 4). Verbal consent was sought from the patient before all the pictures were taken along with the history.

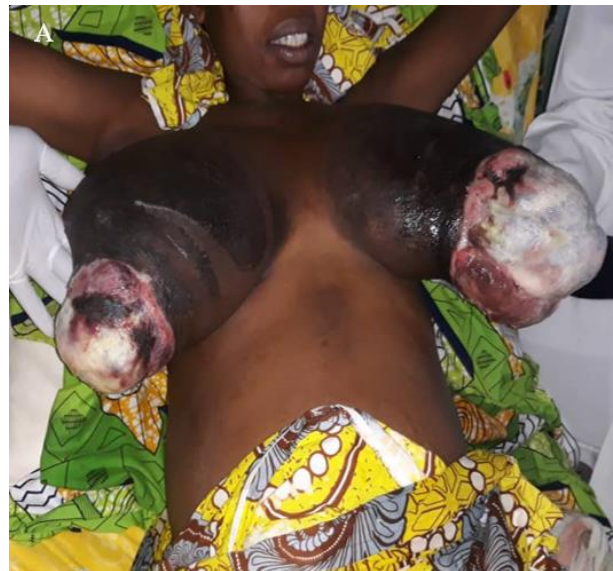

Figure 1: Preoperative picture of the bilateral gigantomastia with hyperpigmented skin and ulceration.

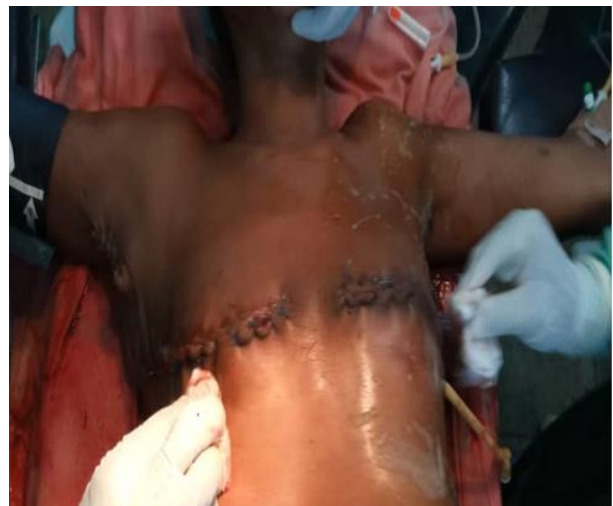

Figure 2: Bilateral simple mastectomy sutured wound

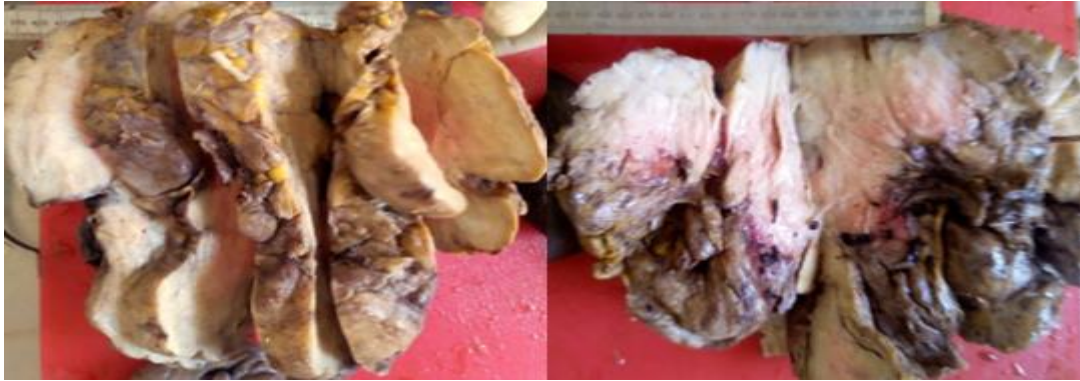

Figure 3: Gross specimen of breasts masses after fixation in 10% formalin, post mastectomy

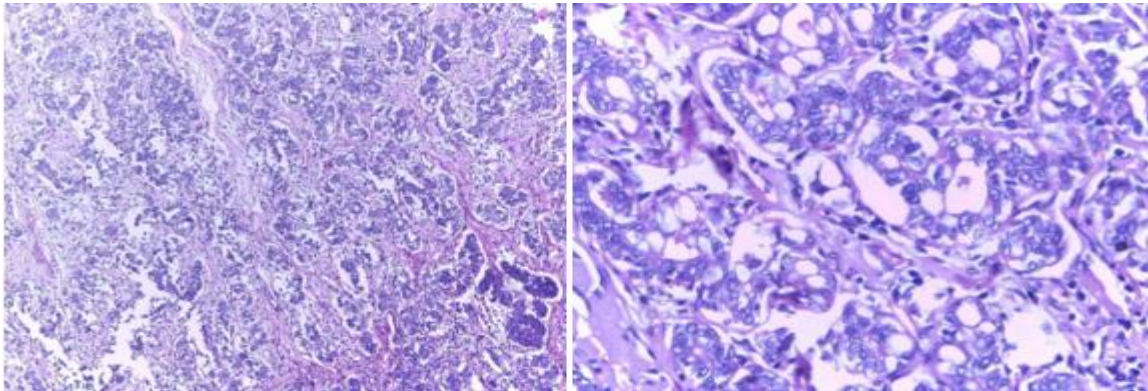


Figure 4: photomicrographs of the breasts tissues composed of hyperplastic glands lined by double layered epithelium arranged in lobular pattern in a hypertrophic fibromyxoid stroma. Haematoxylin and Eosin stains; X100, X200.

Table 1: Literature review of GG

S/N	First Ref.	Author/	Age (Years)	Gravidity/ Gestational age in weeks	Breast Mass Size (cm)	Breast Mass Weight (Kg)	Hormonal (Prolactin, Progesteron)	status Oestrogen,	Present s of Ulcer	Treatment Options
1.	Raziet <i>et al</i> (1)		28	G ₂ P ₁ 0 + 1A 37weeks	Rt=69x47x30 Lt=65x49x31	-	Normal		No ulcer	Bromocriptine at 2.5 mg Bd. Reduction mammoplasty
2	Zingerettiet <i>et al</i> (2)		37	29weeks	Rt=46.5x22.5 Lt=48x24	Rt=3.23 Lt=4.2	Normal		-	Reduction mammoplasty
3	Adili G <i>et al</i> (6)		37	15weeks	-	Rt=7.95 Lt=8.10	Normal		-	Simple mammoplasty
4	Halil T <i>et al</i> (7)		26	22weeks	-	Rt=3.75 Lt=3.7	Increase 110ng/ML	prolactin	-	Simple mastectomy
5	Kala A <i>et al</i> (8) Ezem B <i>et al</i> (9)		20	Primigravida/ 10weeks	Rt=51x28 Lt=54x30	-	Normal		-	Bromocriptine at 2.5mg Bd
6			24	G ₃ P ₂ 0 + 2A 26weeks	-	-	-		No ulcer	Spontaneous regression postpartum
7	Musa G <i>et al</i> (10)		32	G ₈ P ₇ 0 + 7A 28weeks	-	-	Normal		Ulcer present	Bromocriptine at 5mg daily + wound care
8	Jidot T <i>et al</i> (11)		30	G ₂ P ₁ 0 + 1A 12weeks twin	-	-	Normal with history of myasthenia gravis		-	Refractory to Bromocriptine Had subcutaneous mastectomy
9	Sharu A <i>et al</i> (12)		23	G ₂ P ₁ 0 + 1A 12weeks	-	-	-		-	Refractory to Bromocriptine Had subcutaneous mastectomy
10	Begun A <i>et al</i> (13)		32	G ₅ P ₄ 0 + 4A 33weeks	-	-	-		-	Conservative treatment
11	Vincky J <i>et al</i> (14)		27	30weeks	-	-	-		-	Refractory to Bromocriptine Had simple mastectomy
12	Lewisson E <i>et al</i> (15)		18	Primigravida	-	-	Low urinary steroid metabolite Pregnanedion, oestrogen, 17-ketosteroid			Spontaneous reduction, postpartum

Discussion

Gestational Gigantomastia (GG) also called gravid macromastia is a rare medical condition of the breast often associated with pregnancy and characterized by diffuse, disproportional and excessive growth and enlargement of both breast.⁶ Gestational Gigantomastia was first described by Palmuth in 1648 and its aetiology and pathogenesis are not well established to date.⁷ Gigantomastia as defined by Dafydd *et al* is excess breast tissue that contributes 3% of a patient's total body weight.⁶ Others defined gigantomastia as rapid and excessive breast hypertrophy greater than 1.5kg.² In the index case the left and right breast weighed 2kg and 1.9kg respectively. The incidence of the disease was reported as 1 in 100,000 pregnancies worldwide with only 100 cases reported in 40years (1976 to 2016)^{1,4} out of which 50 cases were from human subjects.⁴ In Africa only six cases were reported and to the best of our knowledge, the present case is the seventh emanating from Africa.⁴ Even though the aetiology

of the disease is not known,^{4,5} however, it is believed to be triggered by placental hormones.^{7,8,9} In most reported cases the breast enlargement usually starts during the first trimester and early second trimester,^{4,9} even though our patient experienced the excessive increase in breast size during the second and third trimester, it is possible however that the increase in size may have started during the first trimester but unnoticed by the patient. Of the 50 cases reported, only two cases showed breast enlargement in the third trimester while one case was reported during the postpartum period.² Most of the women are multigravida with no previous history of breast enlargement during the previous pregnancies.^{1,2} Two cases of breast swelling associated with twin gestation have also been reported.² The disease is more common in patients between the ages 26 to 30 years (Table 1) with an age range of 16-35years.¹ Our patient was 32 years old and that falls within the age range of the reported



cases. Gestational gigantomastia was bilateral in 92% of cases as in the index case and only 8% of cases were reported as unilateral.¹ It has also been reported that certain cases of GG have normal hormone levels and the increase in the breast size may be due to an increase in hormonal sensitivity in the target organs.¹ Patients with rheumatoid arthritis were reported to have gigantomastia due to D-penicillamine which predisposes to breast enlargement.⁷ Similarly, other autoimmune disorders such as myasthenia gravis, autoimmune thyroiditis and SLE have also been reported to increase breasts size.^{4,5} Drugs that were found to cause breast enlargement include cyclosporine and bucillamine.⁷ In the index case there was no history of autoimmune disease and the patient was not on any medication prior to the breast enlargement, likewise her hormonal assays were within normal limits. Complications of GG include pain due to rapid breast enlargement and ulceration due to ischemia from pressure effects,¹ as seen in the index case. Secondary bacterial infection with septicaemia is present most of the time present in patients with ulcers as in this case. Few reported cases of GG associated with breast invasive carcinoma (No Specific Type), were described by Vandenberghe et al in 2005.¹ Report of non-Hodgkin lymphoma co-existing with GG were also made, even though there was no evidence to show whether the tumours were responsible for the breast enlargement. Underlying malignancy should always be kept in mind and excluded as there has been a case report in which patient initially presented with GG but later proved to have underlying malignancy.⁴ Similarly, multiple fibroadenomas of the breast have also been reported with GG.²

Considering the range of differential diagnosis for women presenting with GG a thorough workup should include full blood count, electrolytes, urea and creatinine, hormonal assay especially prolactin, oestrogen, and progesterone, liver function test and tissue biopsy.^{4,9,10,11} All these investigations were performed on our patient but turn out to be negative. Histological features of GG are commonly glandular hyperplasia, stromal hypertrophy and oedema as in our case (figure 4). Furthermore, there are reported cases of GG with hypercalcaemia probably due to excessive production of parathyroid hormone.^{1,3}

To date there is no standard treatment protocol for GG, however, medical treatment with bromocriptine

is the most widely used^{4,9,10,11} (Table 1) even though the drug may lead to IUGR as a side effect with the risk of preterm labour.^{1,4} Other drugs that were tried include Br- alpha ergocryptine, androgen, oestrogen and progesterone but with limited success. Drugs like stilbesterol, norethindrone and tamoxifen have also been tried but all in vain.^{4,5} The most successful treatment is surgery in the form of reduction mammoplasty or simple mastectomy¹ which is usually indicated when there is a complication such as tissue necrosis, as in our case (figure 1, 2). Recurrence has been reported in some instances of reduction mammoplasty.¹ Termination of pregnancy does not improve the breast enlargement and so is usually discouraged unless indicated by other maternal medical conditions.⁴

Conclusion: Gestational gigantomastia is a rare non-neoplastic disease of unknown aetiology. Good and comprehensive knowledge on this distressing clinical condition is a must among all categories of practicing physicians as it requires multidisciplinary crew effort for a good foeto-maternal outcome. More studies at the molecular level are required to find the exact aetiology of this rare disease so that the treatment will be focused on the arrest of the progression of the disease at an early stage.

References

1. Rezai S, Nakagawa JT, Tedesco J, Chadee A, Gottimukkala S, Mercedo R *et al.* Gestational gigantomastia complicating pregnancy: A case report and review of the literature. *Case Rep ObsGyn*2015;<http://dx.doi.org/10.1155/2015/892369>.
2. Zingaretti N, Biaso FD, Ricco M, Nardini N, Mariuzzi L, Parodi PC. A case of gestational gigantomastia in a 37 - year - old woman associated with elevated ANA: A casual linkage. *Pan Afri Med J* 2017; 27: 167.
3. Reis PE, Sntos NQB, Pagio FA, Chambo F, Chambo D, Filbo AC. Management and follow up of a case of gestational gigantomastia in a Brazillian hospital. *Case Rep ObsGyn*2014; Article ID 610363.4.
4. Mangla M, Single D. Gestational gigantomastia: A systematic review of case report. *J Medlife Health* 2017; 8(1): 40 - 44.



5. Lafreniere R, Ketcham TW. A gestational macromastia. *AMJ Surg.* 1984; 148: 413-418. [PubMed: 6476236].
6. Adili G, Axier A, Meixiang L, Chenming G, Huifang L, Keyoumu G *et al.* An exceptional case of gestational gigantomastia. *J Gynaecol Women's Health* 2019; 15(2): 555911. Doi: 10.19080/JGWH.2019.15.555911.
7. HalilTurkan M, Gokgoz S, Tesdelen J, Dundar HZ. Gestational gigantomastia. *J Breast Health* 2016; 12:86-87.
8. Kala A, Rathna A, Kesari S. A rare case report of gestational gigantomastia. *Evolution Med. Dent Sci* 2019; 8(35): 2773 - 2774.
9. Ezem Bu, Obuagwu CC, Opara KA. Gestational gigantomastia with complete resolution in Nigerian women. *BMJ case report* 2011; doi: 10.1136/bcr.01.2010.2632.
10. Musa G, Malumani M, Teyangesikayi G. gestational gigantomastia: A patient case review and literature review. *Med J Zambia* 2018; 45 (2): 112-116.
11. Jido T. A, Mohammed AZ, Alhassan SU. Gigantomastia complicating pregnancy: A case report. *Niger J Med* 2006; 24: 396 - 401.
12. Sharu A, Elbassiony L, Amin M. Gestational gigantomastia: a review article and case presentation of a new surgical management options. *Surg Innovation* 2011;18(1): 94-101.
13. Beegun A, Iqbal K, Kyari K. A rare case of gestational gigantomastia with complete resolution after delivery. *J Society ObstGynae Pakistan* 2015;5(1):51-54.
14. Vincky J, Gonzalez N, Dubinsky D, Nasswetter G, Cardinal H, Hojman J. Gestational gigantomastia in autoimmune diseases. *J ClinRheuma* 2015; 21(2): 110-112.
15. Lewisson E, Jones G, Trimble F, da Lima L. Gigantomastia complicating pregnancy. *SurgGynaecolObst* 1960; 110:215-223.

Cite this Article as: Abdullahi YM, Zarami AB, Lawan AI, Guduf MI, Farouk HU, Pindiga UH. Gestational Gigantomastia: Report of a Rare Case and Literature Review. **Bo Med J** 2021;18(2):1-6 **Source of Support:** Nil, **Conflict of Interest:** None declared

